



Atypical Location and Appearance of Chondromyxoid of the Right Iliac Wing Fibroma in a Child

Hicham Ziani ^{a*}, Ayoub Ettaj ^a, Yassine Regragui ^a,
Nabil Elachhab ^a, Aziza Bentalha ^a, Alae El Koraichi ^a
and Selma El Kettani ^a

^a Department of Pediatric Intensive Care and Anesthesia, Ibn Sina Hospital, Mohammed V University, Rabat, Morocco.

Authors' contributions

This work was carried out in collaboration among all authors. Authors HZ, AE, YR and NE wrote the first draft of the manuscript. Authors AB, AEK and SEK managed the analyses of the study. All authors read and approved the final manuscript

Article Information

DOI: 10.9734/AJPR/2023/v12i2234

Open Peer Review History:

This journal follows the Advanced Open Peer Review policy. Identity of the Reviewers, Editor(s) and additional Reviewers, peer review comments, different versions of the manuscript, comments of the editors, etc are available here: <https://www.sdiarticle5.com/review-history/98718>

Case Report

Received: 07/02/2023
Accepted: 09/04/2023
Published: 13/04/2023

ABSTRACT

Aims: The chondromyxoid tumor is a benign primary bone tumor of cartilaginous differentiation whose location is atypical and rarely described in the literature.

Case Report: A 10 year old child, who consulted the emergency room of the children's hospital of Rabat for a hard and painful swelling of the right iliac fossa, rapidly increasing in volume. Biological tests were normal. The radiography showed a mixed lytic and condensing lesion, heterogeneous, of the right iliac wing, prompting an magnetic resonance imaging (MRI).

Discussion: Chondromyxoid fibroma usually affects young subjects and manifests clinically as pain and swelling. Pathological fractures are common.

*Corresponding author: Email: drzianih@gmail.com;

On standard radiography, in long bones, there is an eccentric geographic gap, blowing out the cortex. On flat bones such as the iliac bone, the tumor is often polycyclic and mixed, combining condensation and bone lysis. Intratumoral microcalcifications may be encountered.

MRI is the key examination to evoke the diagnosis of chondromyxoid fibroma.

Conclusion: Imaging and in particular MRI plays multiple and fundamental roles in the management of chondromyxoid fibroma. MRI provides diagnostic guidance, particularly in the case of atypical localization.

Keywords: Chondromyxoid fibroma; child.

1. INTRODUCTION

Chondromyxoid tumor is a rare benign bone tumor, presenting 0.5% of primary bone tumors. It usually involves the metaphyses of long bones.

The objective of our article is to illustrate an aggressive form of this tumor, of atypical location in a child, by underlining the preponderant role of magnetic resonance imaging (MRI) in its management.

2. PRESENTATION OF THE CASE

A 10 year old child, who consulted the emergency room of the children's hospital of Rabat for a hard and painful swelling of the right iliac fossa, rapidly increasing in volume. Biological tests were normal. The radiography showed a mixed lytic and condensing lesion, heterogeneous, of the right iliac wing, prompting an MRI.

The MRI showed a lesion process centered on the right iliac wing (Fig. 1), multi-loculated, hyposignal T1, hypersignal T2 heterogeneous, containing multiple thick septa in hyposignal T2 enhanced by Gadolinium, without diffusion restriction. There is a compact reaction opposite, without invasion of adjacent structures. There was no fatty infiltration or associated adenopathies.

The process was in favor of a benign origin rather than a chondrosarcoma. Chondromyxoid fibroma was among the diagnoses evoked, and was histologically confirmed after biopsy of the tumor. Surgical excision was indicated.

Tumor recurrence was objectified by a follow-up MRI performed after 5 months. It is noted that the recurrence was larger than the primary tumor (Fig. 1d).

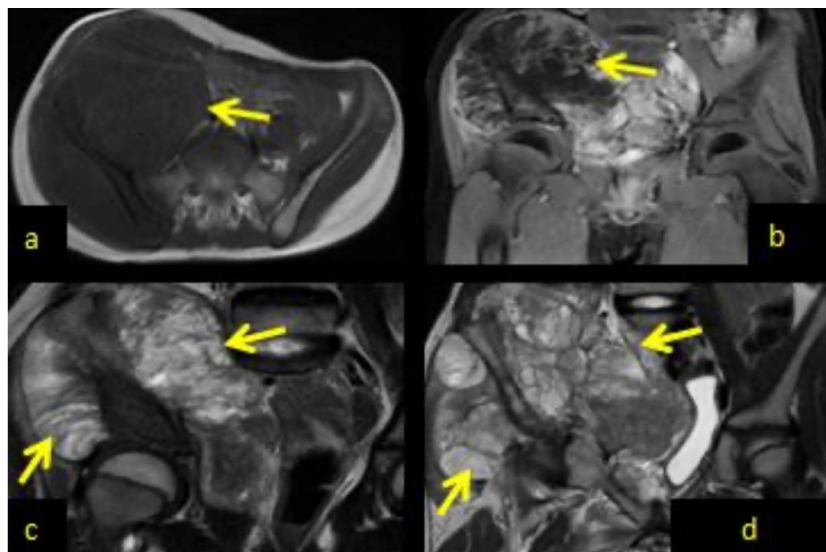


Fig. 1. Pelvic MRI in axial T1-weighted sequence without (a) and after (b) gadolinium injection, and in sagittal section T2-weighted sequence before (c) and 5 months after surgical resection (d). The images show a tumor process centered on the right iliac wing, multi-localized, in hyposignal T1 (a), enhanced by Gadolinium (b). The tumor shows a heterogeneous T2 hypersignal, with multiple thick septa in T2 hyposignal (c). There is a compact periosteal reaction opposite, without invasion of adjacent organs

3. DISCUSSION

Chondromyxoid fibroma usually affects young subjects and manifests clinically as pain and swelling. Pathological fractures are common [1,2].

On standard radiography, in long bones, there is an eccentric geographic gap, blowing out the cortex. On flat bones such as the iliac bone, the tumor is often polycyclic and mixed, combining condensation and bone lysis. Intratumoral microcalcifications may be encountered [3,4].

magnetic resonance imaging (MRI) is the key examination to evoke the diagnosis of chondromyxoid fibroma. The myxoid component appears hyposignal on the T1-weighted sequence, hypersignal on the T2-weighted sequence, and enhanced by Gadolinium. MRI can also detect other associated intratumoral components: fibrous, cystic and calcific [5-8].

Chondromyxoid fibroma is characterized by the absence of intramedullary extension, which makes it possible to differentiate its aggressive form from a chondrosarcoma, the latter being the main differential diagnosis. Hence the interest of a meticulous analysis of the tumor's relationship in MRI. Histological confirmation by biopsy is always indicated [5,6,9,10].

Treatment consists of complete excision of the tumor with curettage and bone filling. It should be noted that total resection is not always possible, hence the frequency of recurrence, which reaches 25% of cases. Malignant tumor transformation is exceptional [1,3,11].

4. CONCLUSION

Imaging and in particular MRI plays multiple and fundamental roles in the management of chondromyxoid fibroma. MRI provides diagnostic guidance, particularly in the case of atypical localization, a precise study of tumor relationships to guide surgical treatment, and the search for postoperative recurrence.

CONSENT

All authors declare that written informed consent was obtained from the parents of the patient (for publication of this case report and accompanying images).

ETHICAL APPROVAL

All authors hereby declare that all experiments have been examined and approved by the

appropriate ethics committee and have therefore been performed in accordance with the ethical standards laid down in the 1964 Declaration of Helsinki.

ACKNOWLEDGEMENTS

All authors provided assistance in preparation, design, collection, analysis and interpretation the writing of the manuscript. No funding to declare.

COMPETING INTERESTS

Authors have declared that no competing interests exist.

REFERENCES

1. Harzallah L, Bouajina E, Rammeh N, Belhadj SK, Ghannouchi M, Kraiem C. Iliac chondroma: A propos d'un Iliac chondroma: A case report. *Tunis Med.* 2005;83(9):578-580.
2. Foster DA, Yellen P, Xu L, Saqçena M. Regulation of g1 cell cycle progression distinguishing the restriction point from a nutrient-sensing cell growth checkpoint (s). *Genes Cance* 2010;1(11):1124–31.
3. Johnson GC, Christensen M. Benign chondromyxoid fibroma of the iliac crest. *J Orthop Sports Phys Ther.* 2018;48(2):122.
4. Jeon D, Koh JS, Cho WH, et al. Clinical outcome of low-grade central osteosarcoma and role of CDK4 and MDM2 immunohistochemistry as a diagnostic adjunct. *J Orthopaedic Sci.* 2015;20(3):529–37.
5. Jerbi Omezzine S, Hafsa C, Ben Ghozlan H, Sassi N, Hamza HA, Gannouni A. A rare localization of chondromyxoid rare location of a chondromyxoid fibroma: The os calcis. *J Radiol.* 2008;89(7-8 Pt 1):897-899.
6. Yalniz E, Alicioglu B, Yalcin O, Yilmaz B. Non specific magnetic resonance features of chondromyxoid fibroma of the iliac bone. *J BUON.* 2007;12(3):407-40.
7. Melo AN, Eischen CM. Protecting the genome from mdm2 and mdmx. *Genes Cancer.* 2012;3(3-4):283–90.
8. Dujardin F, Binh MBN, Bouvier C, et al. MDM2 and CDK4 immunohistochemistry is a valuable tool in the differential diagnosis of low-grade osteosarcomas and other primary fibro-osseous lesions of the bone. *Mod Pathol,* 2011;24(5):624–37.

9. Yoshida A, Ushiku T, Motoi T, et al. MDM2 and CDK4 immunohistochemical coexpression in high-grade osteosarcoma: correlation with a dedifferentiated subtype. Am J Surg Pathol. 2012;36(3): 423–31.
10. Martin JW, Chilton-MacNeill S, Koti M, et al. Digital expression profiling identifies RUNX2, CDC5L, MDM2, RECQL4, and CDK4 as potential predictive biomarkers for neo-adjuvant chemotherapy response in paediatric osteosarcoma. PLoS ONE.2014;9(5):e95843.
11. Ng TL, Gown AM, Barry TS, et al. Nuclear beta-catenin in mesenchymal tumors. Mod Pathol 2005;18(1):68–74.

© 2023 Ziani et al.; This is an Open Access article distributed under the terms of the Creative Commons Attribution License (<http://creativecommons.org/licenses/by/4.0>), which permits unrestricted use, distribution, and reproduction in any medium, provided the original work is properly cited.

Peer-review history:

The peer review history for this paper can be accessed here:
<https://www.sdiarticle5.com/review-history/98718>