



Comparison of Efficacy of the Pap and H & E in Identifying the Various Changes in Liver Samples of High Fat Diet Induced Rat - *In vitro* Study

E. Dhivya Sri^{at}, R. Priyadharshini^{a*#}, Palati Sinduja^{a#} and V. Meghashree^{a#}

^a Department of Pathology, Saveetha Dental College and Hospitals, Saveetha Institute of Medical and Technical Sciences (SIMATS), Saveetha University, Chennai 77, Tamil Nadu, India.

Authors' contributions

This work was carried out in collaboration among all authors. All authors read and approved the final manuscript.

Article Information

DOI: 10.9734/JPRI/2021/v33i54A33757

Editor(s):

(1) Dr. Farzaneh Mohamadpour, University of Sistan and Baluchestan, Iran.

Reviewers:

(1) Christulas Jyoti, GEMS School of Nursing, India.

(2) R. Murphy, Dublin City University, Ireland.

Complete Peer review History, details of the editor(s), Reviewers and additional Reviewers are available here: <https://www.sdiarticle5.com/review-history/77543>

Received 01 October 2021

Accepted 04 December 2021

Published 11 December 2021

Original Research Article

ABSTRACT

Introduction: High fat induced (HFI) liver is associated with a high calorie intake and many other diet-induced complications, such as metabolic syndrome and cardiovascular disease. HFI is the most common chronic liver disease that develops due to high fat intake. A wide range of liver injuries is associated with HFI, ranging from simple steatosis to nonalcoholic steatohepatitis (NASH), advanced fibrosis and cirrhosis. The signs and symptoms of metabolic syndrome may be induced in rats by feeding them a diet rich in carbohydrates and fat. The aim of the study is Comparison of efficacy of the PAP (Papanicolaou) stain and H&E (Hematoxylin and eosin) stain in identifying the various changes in liver samples of high fat diet induced rat.

Materials and Methods: Liver samples of Normal control group animal and High fat diet induced animal were sectioned, weighed fixed 10% neutral buffer formalin and mounted in DPX compound. Four micrometer sections were stained with hematoxylin-eosin and PAP stains for the histological examination of micro-vesicular and macro-vesicular steatosis in the liver tissue. The grading of steatosis was given from 0-3 based on the lipid accumulation (steatosis): grade 0 - absence; grade 1 - mild Steatosis (<30% hepatocyte); grade 2- moderate steatosis (30%-70% hepatocyte); grade 3-

[†] Undergraduate;

[#] Assistant Professor;

*Corresponding author: E-mail: priyadharshinir.sdc@saveetha.com;

severe steatosis (>70% hepatocytes). Efficacy of grade of PAP stain and H&E stain were accessed and statistically evaluated by considering seven parameters and overall staining characters where compared.

Results: Our present study evaluated high fat induced hepatic steatosis of H&E and PAP stain and also evaluated efficacy of both the stain. In our study, Pie chart showing the percentage distribution of Number of micro-vesicles about 70% represents greater than 30, 10% represents 30-70, 20% represents less than 70 (Fig. 1). In our study 20% represents the greater than 30, 30% represents the 30-70, 50% represents Less than 70 (Fig. 2). 30% represents mild steatosis, 20% represents moderate steatosis, 50% represents Severe Steatosis (Fig. 3).

Conclusion: We demonstrated the comparative efficiency of the PAP and H&E high fat diet induced rat liver by in vivo and conclude that both H&E and PAP stain has equal efficacy and clarity in observing the various minute parameters.

Keywords: Papanicolaou; hematoxylin and eosin; innovative technique; high fat diet; steatosis.

1. INTRODUCTION

A high-fat diet (HFD) is a diet consisting of at least 35% of total calories consumed from fats, both unsaturated and saturated [1]. In addition to the popular processed foods, many other foods have a high fat content including but not limited to animal fat, chocolate, butter, and oily fish [2]. In a previous study, it was observed that High fat induces significant lobular inflammation, hepatocellular necrosis, hepatocellular ballooning, portal tract inflammation, pericellular and portal fibrosis as described. Also liver collected from rats in different stages of experiment. Many previous studies performed on mice and rats suggested that obesity can be induced by a high fat diet [3].

High-fat diet intake allows animals to develop obesity, hyperinsulinemia, hyperglycemia, hypertension, and liver damage, similar to the phenotype observed in rats with HFD. Thus, review studies that use this model to study the effects of lipid intake [4]. Consuming a high-fat, high-sugar diet causes a harmful accumulation of fat in the liver that may not reverse even after switching to a healthier diet. A high-fat diet causes liver injury in rats leading to periportal fibrosis. A role for oxidative stress is suggested via increased NADPH oxidase activity, lipid peroxidation, protein carbonyl formation, and low antioxidant defense [5].

Steatosis (fatty liver) is commonly caused by insulin resistance due to obesity. Histologically, it is characterized as hepatocytes containing excess fat and appearing to have multiple round, empty vacuoles in the cytoplasm [5,6]. Hepatic steatosis is an intrahepatic fat of at least 5% of liver weight. Simple accumulation of triacylglycerols in the liver could be

hepatoprotective; however, prolonged hepatic lipid storage may lead to liver metabolic dysfunction, inflammation, and advanced forms of nonalcoholic fatty liver disease [7].

Micro-vesicular steatosis is characterized by the presence of numerous small vesicles of fat that do not displace the nucleus. Macro-vesicular steatosis is characterized by engorgement of the hepatocyte by a large fat globule that displaces the nucleus [8]. Macro-vesicular steatosis is the most common form and is histologically characterized by hepatocytes containing a single vacuole of fat filling up the hepatocyte and displacing the nucleus to the cell's periphery. Macro-vesicular steatosis is typically caused by alcohol, diabetes, or obesity. The term "micro-vesicular steatosis of the liver" refers to a variant form of hepatic fat accumulation whose histologic features contrast with the much more common macro-vesicular steatosis [9].

Hepatic tissue analysis from rats fed with HFD (High Fat Diet) revealed a progressive increase in steatosis and inflammatory damage in comparison with control diet fed animals. Hematoxylin-eosin-stained liver samples obtained from the two groups fed HFD showed initial signs of liver inflammation characterized by the presence of mixed inflammatory cell infiltration and hepatocyte necrosis or apoptosis which appeared throughout the lobule and more evident at 8 weeks. HFD rats showed progressive time-dependent steatosis (from grade 2 to grade 3) with a histological pattern characterized by micro-vesicular steatosis, already evident after 5 weeks of HFD [10]. The hepatocytes showed the cytoplasm filled with small vacuoles which were uniform in size and smaller than the centrally located nucleus. No alterations were observed in the liver of the rats

fed with the control diet. To further characterize the progressive steatosis and inflammation, we assayed hepatic triglycerides, which were significantly increased in 8 weeks HFD-fed animals. The accumulated lipids induce oxidative stress, resulting in production of cytokines and reactive oxygen species which in turn activate apoptosis thereby initiating a sequence of disease events from steatosis to nonalcoholic steatohepatitis [11].

PAP (Papanicolaou) stain is a polychromatic multi-colored stain that differentially stain various components. It is a histological and cytopathological staining technique used to differentiate cells in a smear preparation [12]. It is mainly used for oral and cervical cancer screening in asymptomatic populations and in the follow up of patients with cancer. Hematoxylin and Eosin (H&E) staining is used routinely in histopathology laboratories as it provides the pathologist/researcher a very detailed view of the tissue. It achieves this by clearly staining cell structures including the cytoplasm, nucleus, and organelles and extracellular components [13,14].

The challenges faced by others was that cell sections are prepared and shown by the morphological abnormalities. The novelty of the research is the comparison of the efficacy of PAP and H&E stains in rat liver samples in analyzing the micro-vesicular and macro-vesicular changes and deficiency is fulfilled to identify the specificity and sensitivity of PAP and H&E stain liver structures. The aim of the study is Comparison of efficiency of the PAP and H&E in identifying the various changes in liver samples of high fat diet induced rat.

2. MATERIALS AND METHODS

Liver samples of Normal control group animal and High fat diet induced animal were included in the present study (normal control group - 5 rat archives and high fat diet induced - 5 rat archives), Sectioning samples were collected from randomly 10 rat liver samples was examined at Pink Lab of Saveetha Dental College and Hospitals, Saveetha Institute of Medical and Technical Sciences. The inclusion criterion for choosing the sample was the high fat induced rat liver. It's a cross-sectional in vivo study. The sample was taken from a total of ten rat archival blocks. The validation of the procedure was given by a research guide. The data collected and tabulated in excel

spreadsheet and statistical analysis were done by SPSS - Version 23. The high fat induced liver rat samples and healthy rat liver samples are included in the study. Key risk factors like over weighted and an altered dietary pattern are excluded.

Liver samples of Normal control group animal and High fat diet induced animal were sectioned, weighed and fixed 10% neutral buffer formalin and mounted in DPX compound. Four micrometer sections were stained with hematoxylin-eosin and PAP stains for the histological examination of micro-vesicular and macro-vesicular steatosis in the liver tissue. Our present study evaluated the grading of steatosis based on the lipid accumulation (steatosis): grade 0 - absence; grade 1 - mild Steatosis (<30% hepatocyte); grade 2- moderate steatosis (30%-70% hepatocyte); grade3- severe steatosis (>70%hepatocytes). Efficacy of grade of PAP stain and H&E stain were accessed and statistically evaluated by considering seven parameters and overall staining characters where compared. Grading was given based on the number of lipid micro-vesicular and macro-vesicular steatosis in the liver. The level of significance obtained with both inter and intra observer counting of lipid vacuoles.

2.1 Hematoxylin and Eosin Staining Procedure

The first step in performing an H&E stain, the slide has been kept in the suitable adhering agents, then slightly warm to melt the wax off, remove the wax with xylene by 3 changes and also with propanol for 3 changes, bring the smear to the water for 3 minutes, dip the smear in rapid nuclear stain for 60 sec then add 3 drops of scott's tap water buffer and wash after 10 seconds, dip the smear in eosin stain for 60 sec and also wash the smear for 15 sec to remove the excess water, finally clear with propanol then with xylene and mount with DPX.

2.2 PAP Staining Procedure

Hydrate the fixed smear for 3-5 minutes in tap water and blot out excess water from the slide. Keep the slide on a staining rack and add a few drops of nuclear stain rapid PAP (R1) to cover the smear. Wait for 60 seconds and wash in running tap water. Add 3-5 drops of wash Buffer (R7) and wash after 20 Sec. Blot out excess water from the slide. Dehydrate with RAPID-PAP

DEHYDRANT (R5) for 60 seconds. keep the slide on a staining rack and add a few drops of working CYTOPLASM STAIN (R2A+R2B) to cover the smear. Wait for 60 seconds. Wash in tap water, blot out excess water from the slide and may see under microscopy (unmounted). If the smear requires mounting, dehydrate with RAPID-PAP DEHYDRANT (R5) for 60 seconds and dry in the air. Rinse with Xylene (R6).

Mount with cover glass using a drop of D.P.X.(R4).

3. RESULTS

Our present study evaluated high fat induced hepatic steatosis of H&E and PAP stain and also evaluated efficacy of both the stain. The study implies the high-fat diet induced resistance to insulin in diabetic rat models.

Table 1. Table showing lipid Inclusion in PAP stain

Samples	No. of micro-vesicles	No. of macro-vesicles	Grade
1	<30	30-70	Moderate steatosis
2	<30	>70	Severe steatosis
3	>70	<30	Mild steatosis
4	>70	<30	Mild steatosis
5	<30	>70	Severe steatosis
6	<30	>70	Severe steatosis
7	<30	30-70	Mild steatosis
8	<30	>70	Severe steatosis
9	<30	30-70	Moderate steatosis
10	=30	>70	Severe steatosis

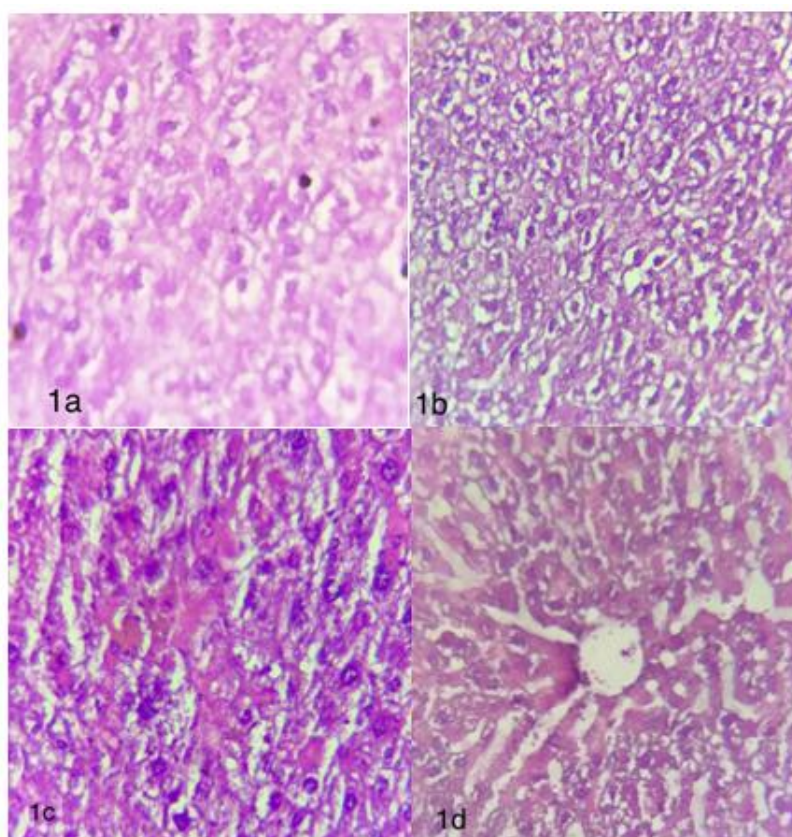


Plate 1. Photomicrograph showing 1a: Lipid accumulation around the nucleus (H&E,40x), 1b: Micro-vesicular and focal macro-vesicular steatosis (H&E,40x), 1c: Coalesced hepatocytes with moderate steatosis (H&E,40x) , 1d: Liver parenchyma with hepatic vein (H&E,40x)

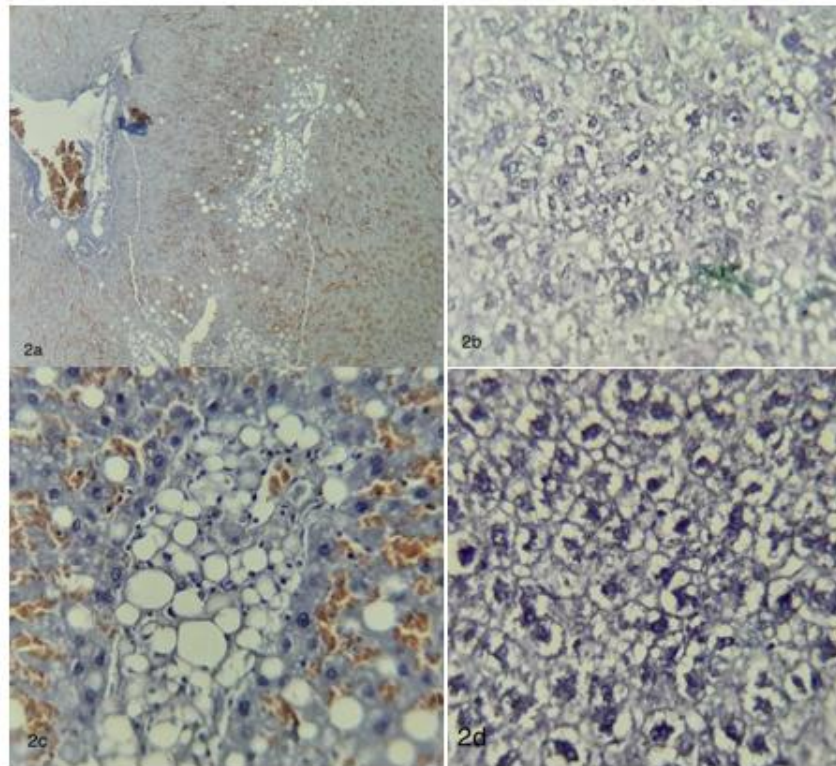


Plate 2. Photomicrograph showing 2a: Liver parenchyma exhibiting steatosis, portal triad and congested sinusoids (PAP,10x), 2b: Liver parenchyma with moderate to severe steatosis (PAP,40x), 2c: Macro-vesicular steatosis with lipid accumulation in the cytoplasm and peripherally pushed nucleus (PAP,40x), 2d: Hepatocytes showing perinuclear lipid accumulation (PAP,40x)

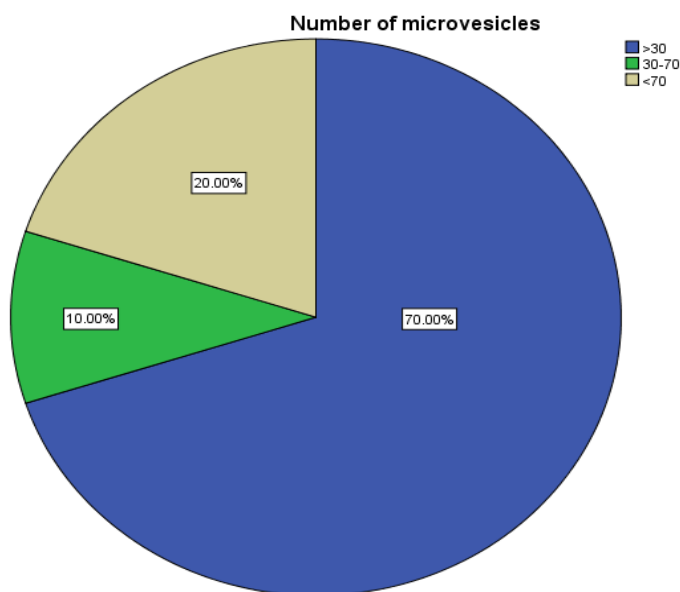


Fig. 1. Pie chart showing percentage distribution of Number of micro-vesicles; 70% (Blue colour) represents the greater than 30, 10% (green colour) represents the 30-70, 20% (beige colour) represents less than 70

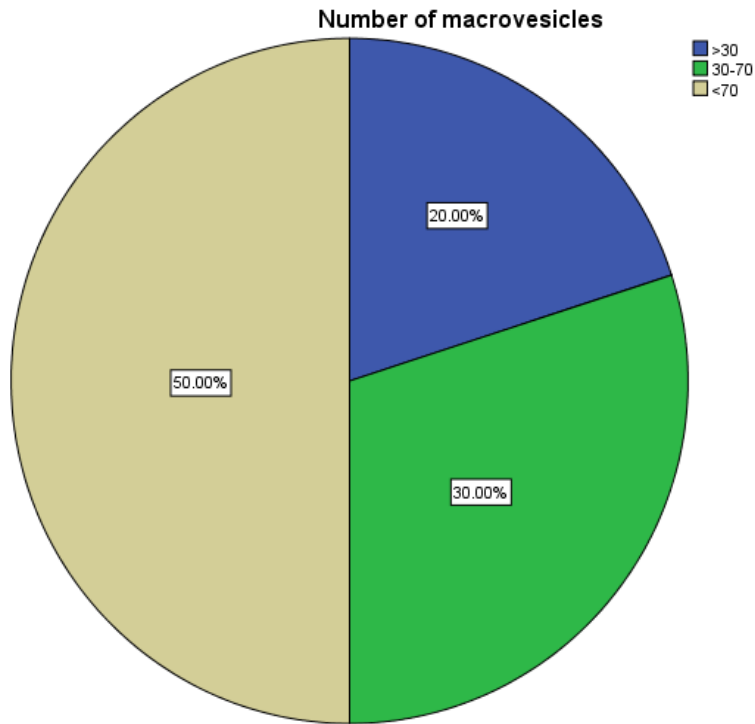


Fig. 2. Pie chart showing percentage distribution of Number of macro-vesicles; 20% (Blue colour) represents the greater than 30, 30% (green colour) represents the 30-70, 50% (beige colour) represents Less than 70

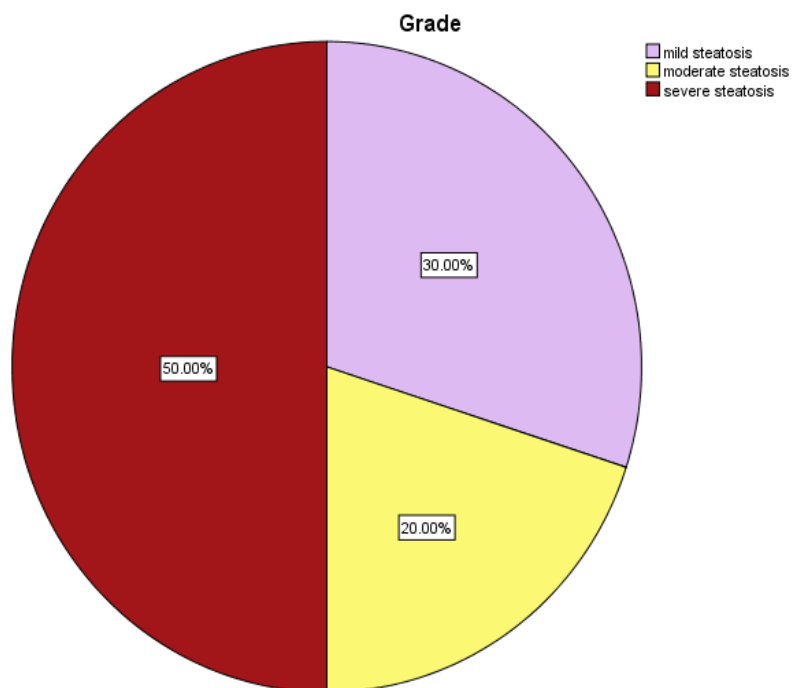


Fig. 3. Pie chart showing percentage distribution of Grade. 30% (Lavender colour) represents mild steatosis, 20% (Yellow) represents moderate steatosis, 50% (Maroon colour) represents Severe Steatosis

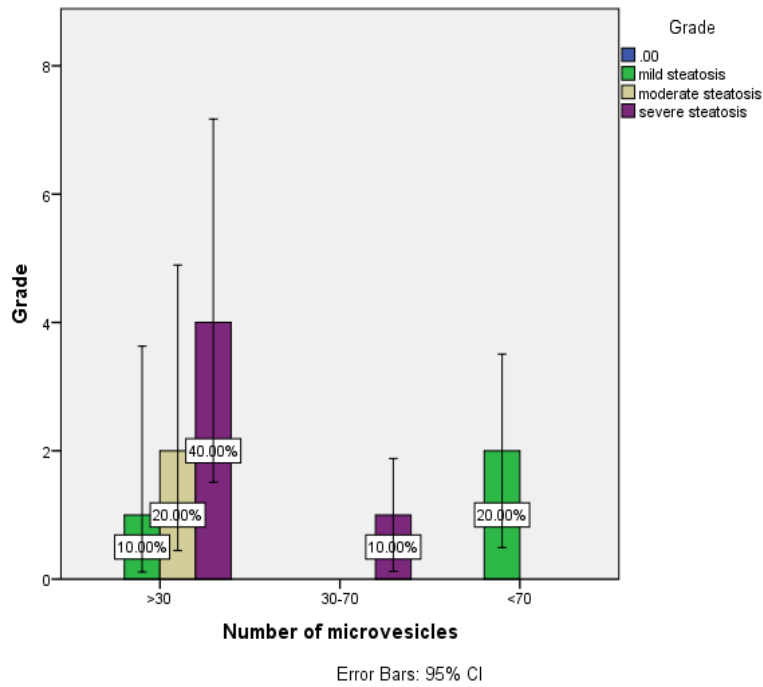


Fig. 4. The above error graph depicts the number of micro-vesicles and Grade. 10% (green colour) represents mild steatosis, 20% (Beige colour) represents moderate steatosis, 40% (Purple colour) represents severe steatosis with number of micro-vesicles >30. 10% (purple colour) represents severe steatosis with number of micro-vesicles 30-70. 20% (green colour) represents mild steatosis with number of micro-vesicles <70

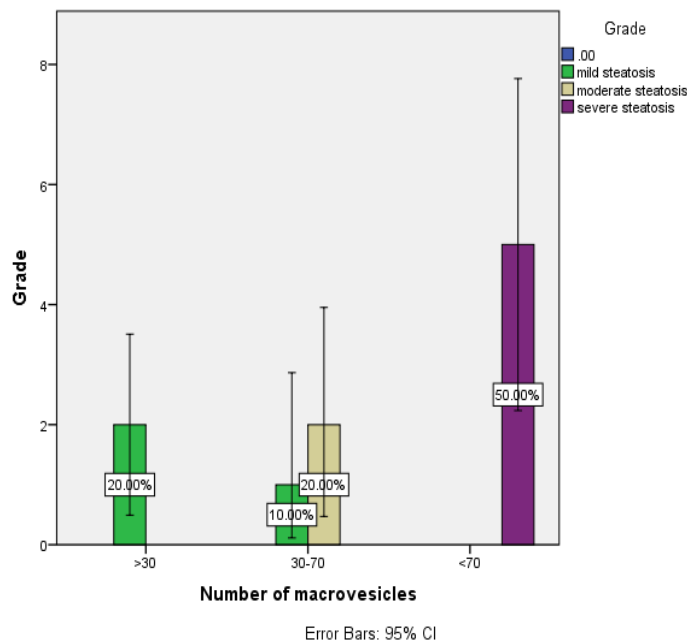


Fig. 5. The above error graph depicts the number of macro-vesicles and Grade. 20% (green color) represents mild steatosis with number of macro-vesicles >30. 10% (green color) represents mild steatosis and 20% (beige color) represents moderate steatosis with number of micro-vesicles 30-70. 50% (purple color) represents severe steatosis with number of macro-vesicles <70

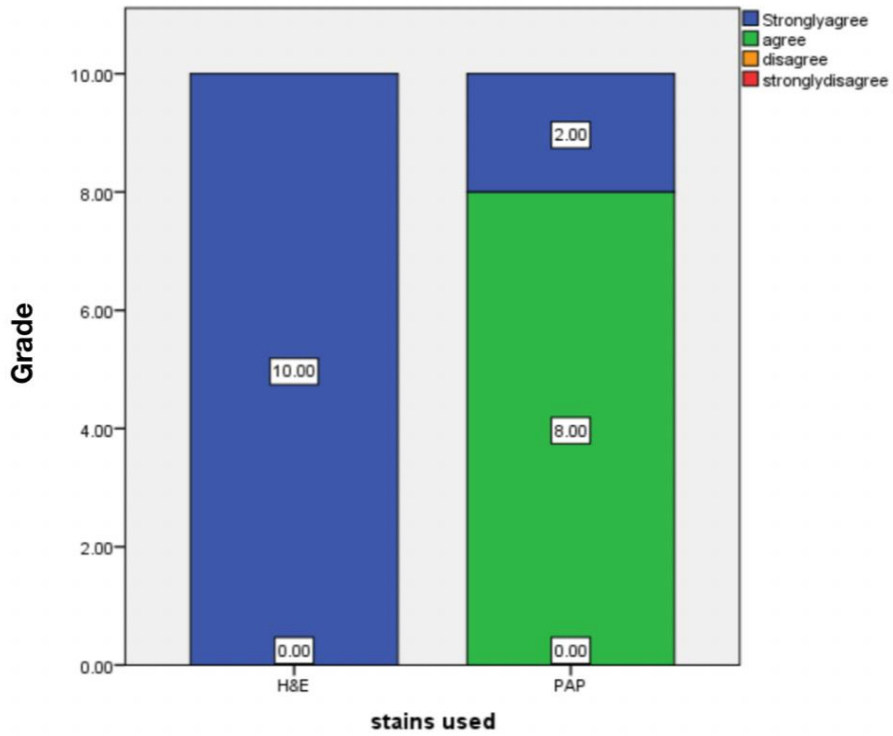


Fig. 6. Bar Chart depicts the association between stain used (X-axis) and grades (Y-axis). In this bar graph it is evident that the Parenchyma 100% strongly agree for Hematoxylin and eosin staining and 80% agree and 20% strongly agree in PAP staining

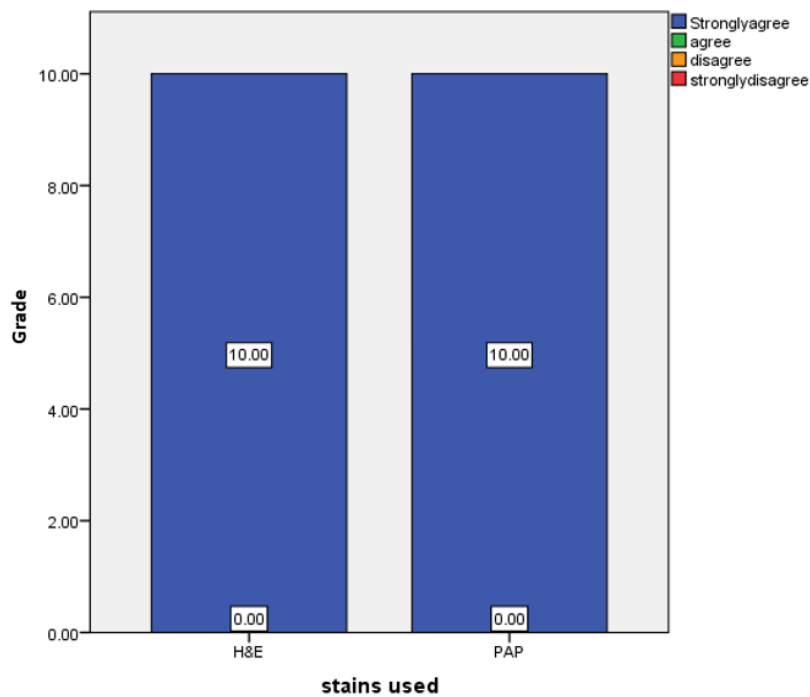


Fig. 7. Bar Chart depicts the association between stain used (X-axis) and Grade (Y-axis). In this bar graph it is evident that the Hepatocytes 100% strongly agree for Hematoxylin and eosin staining and 100% Strongly agree in PAP staining

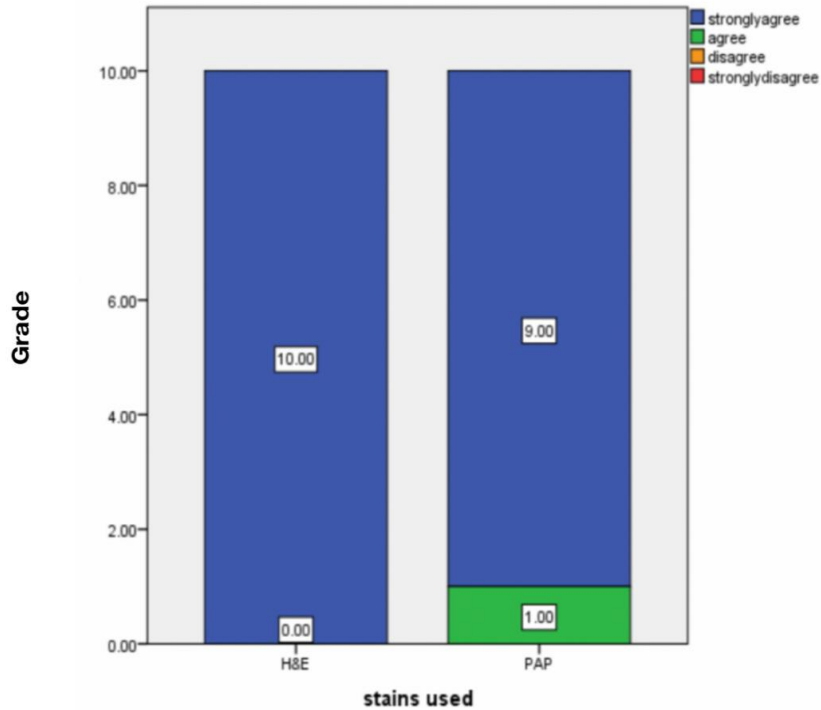


Fig. 8. Bar Chart depicts the association between stain used (X-axis) and Grade (Y-axis). In this bar graph it is evident that the Central vein 100% strongly agree for Hematoxylin and eosin staining and 90% Strongly agree in PAP staining and 10% agree in PAP stain

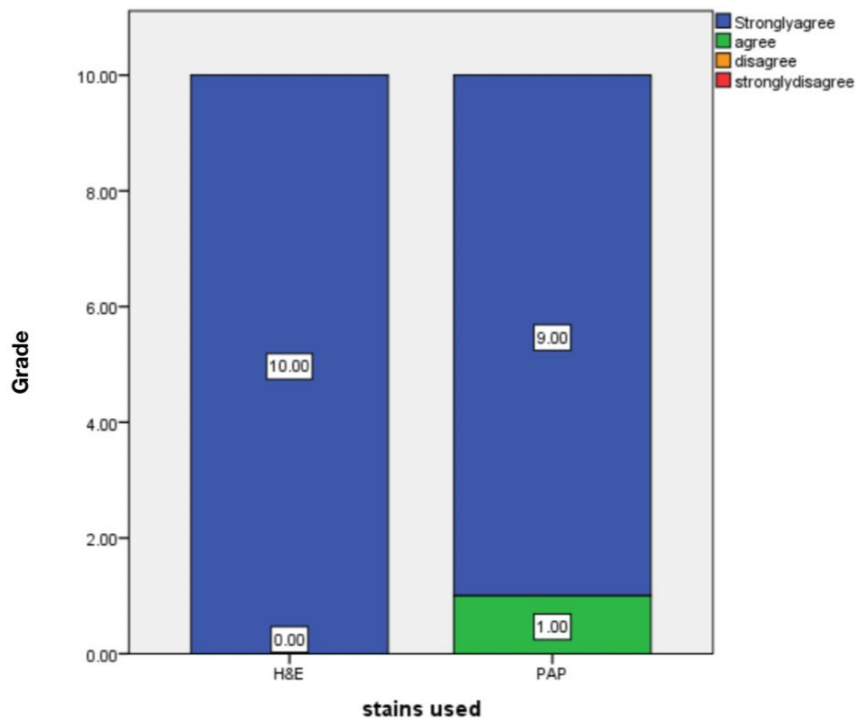


Fig. 9. Bar Chart depicts the association between stain used (X-axis) and Grade (Y-axis). In this bar graph it is evident that the Portal vein 100% strongly agree for Hematoxylin and eosin staining and 90% Strongly agree in PAP staining and 10% agree in PAP stain

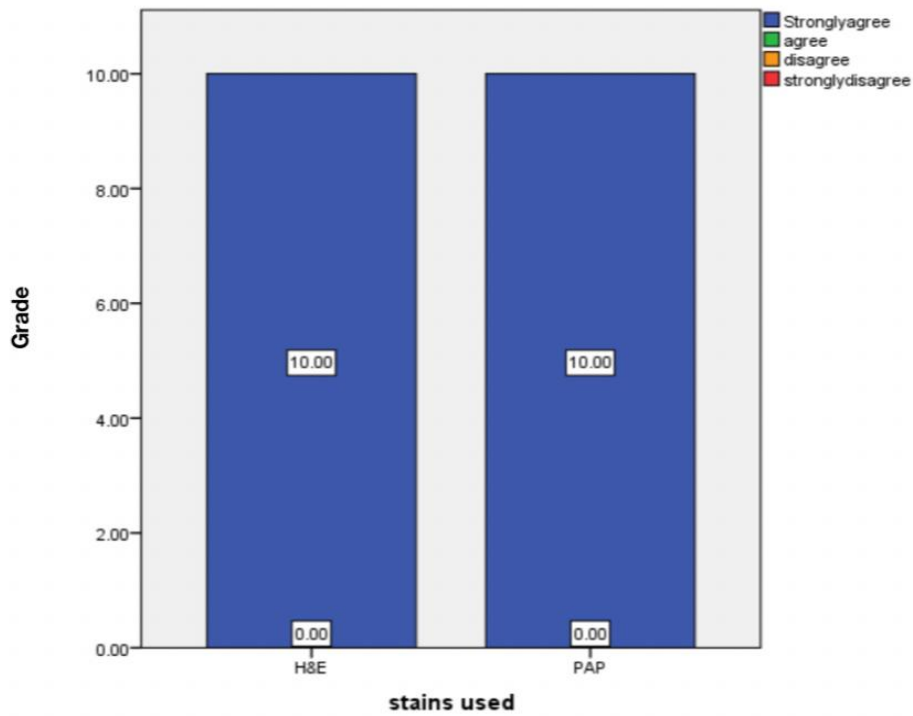


Fig. 10. Bar Chart depicts the association between stain used (X-axis) and Grade (Y-axis). In this bar graph it is evident that the Sinusoids 100% strongly agree for Hematoxylin and eosin staining and 100% Strongly agree in PAP staining

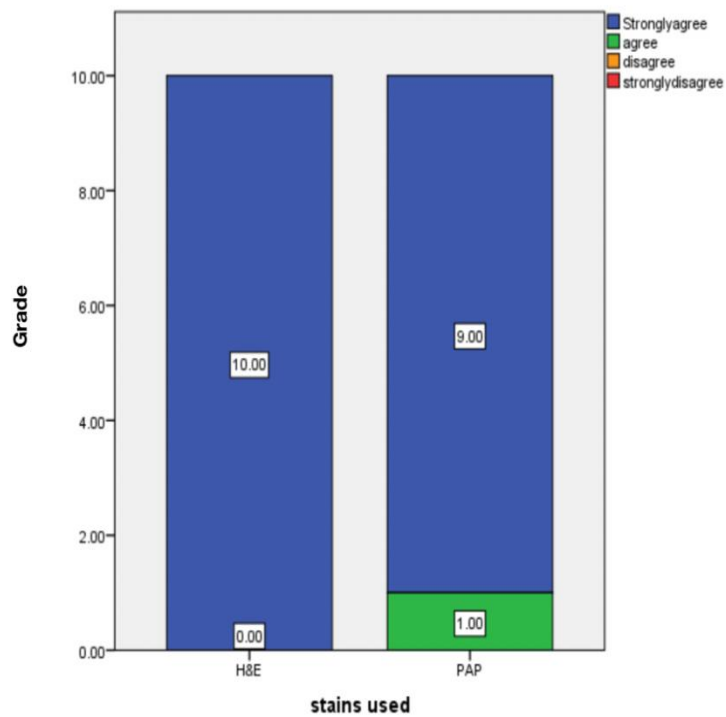


Fig. 11. Bar Chart depicts the association between stain used (X-axis) and Grade (Y-axis). In this bar graph it is evident that the Bile duct 100% strongly agree for Hematoxylin and eosin staining and 90% Strongly agree in PAP staining and 10% agree in PAP stain

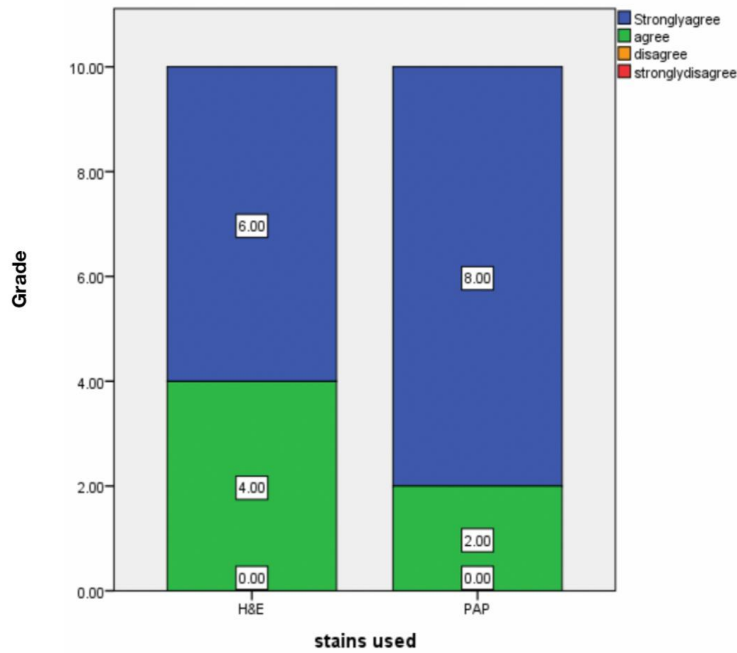


Fig. 12. Bar Chart depicts the association between stain used (X-axis) and Grade (Y-axis). In this bar graph it is evident that the Hepatic vein 60% strongly agree for Hematoxylin and eosin staining and 40% agree for Hematoxylin and eosin staining and 80% strongly agree for PAP stain and 20% agree for PAP Staining

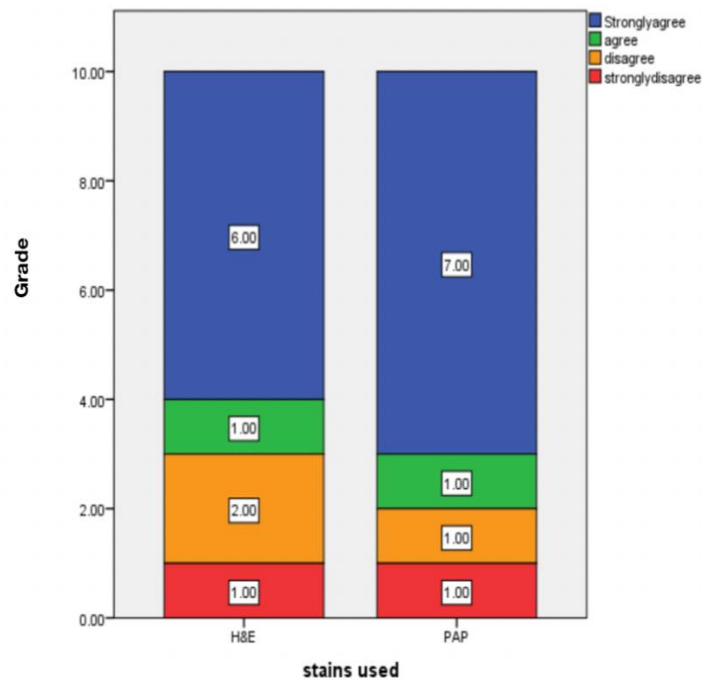


Fig. 13. Bar Chart depicts the association between stain used (X-axis) and Grade (Y-axis). In this bar graph it is evident that Steatosis 60% strongly agree for Hematoxylin and eosin and 10% agree Hematoxylin and eosin and 20% disagree Hematoxylin and eosin and 10% strongly disagree for Hematoxylin and eosin.70% strongly agree for PAP Stain, 10% agree for PAP Stain,10% disagree for PAP Stain and 10% strongly disagree for PAP Stain

4. DISCUSSION

In our study, comparison of efficiency of the PAP and H&E in identifying the various changes in liver samples of high fat diet induced rat showed the percentage distribution of Number of micro-vesicles about 70% represents greater than 30, 10% represents 30-70, 20% represents less than 70 (Fig. 1). In our study 20% represents the greater than 30, 30% represents the 30-70, 50% represents less than 70 (Fig. 2). 30% represents mild steatosis, 20% represents moderate steatosis, 50% represents severe steatosis (Fig. 3). Error graph depicts the number of micro-vesicles and Grade about 10% represents mild steatosis, 20% represents moderate steatosis, 40% represents severe steatosis with number of micro-vesicles is >30. Number of micro-vesicles is 30-70 - 10% represents severe steatosis with number of micro-vesicles is 30-70. 20% represents mild steatosis with the number of micro-vesicles is <70 (Fig. 4). In our study 20% (green colour) represents mild steatosis with number of macro-vesicles >30. 10% (green colour) represents mild steatosis with number of micro-vesicles 30-70. 50% (purple colour) represents severe steatosis with number of macro-vesicles <70 (Fig. 5). In this bar graph it is evident that the Parenchyma 100% strongly agree for Hematoxylin and eosin staining and 80% agree and 20% strongly agree in PAP staining (Fig. 6). In this bar graph it is evident that the Hepatocytes 100% strongly agree for Hematoxylin and eosin staining and 100% Strongly agree in PAP staining (Fig. 7). In this bar graph it is evident that the Central vein 100% strongly agree for Hematoxylin and eosin staining and 90% strongly agree in PAP staining and 10% agree in PAP stain (Fig. 8). In this bar graph it is evident that the Portal vein 100% strongly agree for Hematoxylin and eosin staining and 90% strongly agree in PAP staining and 10% agree in PAP stain (Fig. 9). In this bar graph it is evident that the sinusoids 100% strongly agree for Hematoxylin and eosin staining and 100% strongly agree in PAP staining (Fig. 10). In this bar graph it is evident that the Bile duct 100% strongly agree for Hematoxylin and eosin staining and 90% Strongly agree in PAP staining and 10% agree in PAP stain (Fig. 11). In this bar graph it is evident that the Hepatic vein 60% strongly agree for Hematoxylin and eosin staining and 40% agree for Hematoxylin and eosin staining and 80% strongly agree for PAP stain and 20% agree for PAP Staining (Fig. 12). In this bar graph it is evident that the Steatosis 60% strongly agree for

Hematoxylin and eosin and 10% agree Hematoxylin and eosin and 20% disagree Hematoxylin and eosin and 10% strongly disagree for Hematoxylin and eosin. 70% strongly agree for PAP Stain, 10% agree for PAP Stain, 10% disagree for PAP Stain and 10% strongly disagree for PAP Stain (Fig. 13).

Long-term intake of a high-fat diet combined with high fat induced rats results in an energy imbalance, obesity, and an increased risk of liver disorders. The primary cause of metabolic syndrome is high fat diet, which is a major risk factor for the development of HFI. The accumulated lipids induce oxidative stress, resulting in production of cytokines and reactive oxygen species which in turn activate apoptosis thereby initiating a sequence of disease events from steatosis to HFI. To evaluate the longitudinal changes in liver fat content and unsaturation, on rodents fed with a high-fat diet. HFD is a significant source of fatty acids taken up by the liver. We identified the specific lipid species that are altered in the liver of HFD fed animals due to high fat diet and fatty liver conditions predisposed to high fat induced diet [15].

A number of studies have shown that resistance to a high-fat diet plays a significant role in the development of HFI. Unfortunately, medications that enhance insulin sensitivity have yet to show a significant impact on NAFLD. Octreotide is commonly used in clinical medicine to treat acute pancreatitis and gastrointestinal bleeding [16]. In our study, high-fat diet intake causes obesity, hyperinsulinemia, hyperglycemia, hypertension, and liver damage in animals, which is identical to the phenotype seen in rats on the HFD.

A previous study found that octreotide could help rats with HFD-induced obesity lose weight and improve their metabolism and oxidative stress. A prior study in rats with diet-induced obesity corroborated the action of octreotide, including weight reduction, decreased blood glucose and insulin concentrations with enhanced insulin sensitivity [16,17]. In the current study, high-fat food intake causes obesity, hyperinsulinemia, hyperglycemia, hypertension and liver damage in animals, which is comparable to the phenotype seen in rats on the HFD.

The results of the previous study showed that ipGTT (Intraperitoneal Glucose Tolerance Test) and ipITT (Intraperitoneal Insulin Tolerance Test) further demonstrated that octreotide improves

Table 2. Table showing the findings obtained in various other studies

Author Name	Year	Study	Observation
Shoumen Lasker et al., [1]	2019	High-fat diet-induced metabolic syndrome and oxidative stress in obese rats are ameliorated by yogurt supplementation	To determine the effects of yogurt supplementation on fat deposition, oxidative stress, inflammation and fibrosis in the liver of rats with high-fat diet-induced obesity.
Xiao-Xia Wang et al.,[4]	2017	Effects of octreotide on hepatic glycogenesis in rats with high fat diet-induced obesity	octreotide improved hepatic glycogenesis and decreased FPG concentration in rats with HFD-induced obesity.
Jadegoud Yaligar et al.,[9]	2014	Evaluation of Dietary Effects on Hepatic Lipids in High Fat and Placebo Diet Fed Rats by <i>In Vivo</i> MRS and LC-MS Techniques	They demonstrated the early changes in saturated and unsaturated lipid composition in fatty liver by <i>in vivo</i> MRS and <i>ex vivo</i> LC-MS.
Zuhal Altunkaynak et al.,[45]	2005	Effects of high fat diet induced obesity on female rat livers - A histochemical study.	It was purposed to examine histological effects of fatty diet induced obesity on liver from female obese rats.
Murali Krishna M.D et al., [11]	2013	Role of special stains in diagnostic liver pathology	Diagnostic evaluation of liver tissue is largely based on a thorough examination of sections stained with hematoxylin and eosin (H&E).
M N Berry et al.,[46]	2002	High-yield preparation of isolated rat liver parenchymal cells: a biochemical and fine structural study.	The present paper describes this method and also describes the fine structure of the cells at several stages during the preparative procedures.
G GODLEWSKI, et al., [16]	1997	Liver development in the rat and in man during the embryonic period (Carnegie stages 11–23)	In rats, concerning liver development were somewhat imprecise because the embryonic period was very short and most of the descriptions were established on the observation of a few embryos
Anayt Ulla, et al.[47]	2017	Supplementation of <i>Syzygium cumini</i> seed powder prevented obesity, glucose intolerance, hyperlipidemia and oxidative stress in high carbohydrate high fat diet induced obese rats	The present study,shows the ameliorative potential of <i>Syzygium cumini</i> seed powder on HFD induced glucose intolerance, dyslipidemia, oxidative stress, inflammation and fibrosis in liver.
Chin-Lin Hsu et al.,[48]	2017	Effect of gallic acid on high fat diet-induced dyslipidemia, hepatosteatosis and oxidative stress in rats	These results demonstrate that intake of GA can be beneficial for the suppression of HFD-induced dyslipidemia, hepatosteatosis and oxidative stress in rats.
Panchal, S.K et al., [49]	2012	Ellagic acid attenuates high-carbohydrate, high-fat diet-induced metabolic syndrome in rats	This study has investigated the responses to ellagic acid, present in many fruits and nuts, in a diet-induced rat model of metabolic syndrome.

insulin sensitivity in HFD-induced obese rats [18]. The effect of H&E and PAP Stain efficacy of the high fat diet induced and insulin concentrations was explored in this study, which revealed that a high fat diet increases high fat induced.

The previous study demonstrated that rats with Fat induced by intravenous ALX presented biochemical changes in blood and morphological and ultrastructural lesions in the liver that largely resembled chronic liver disease in humans [19]. In the present study, Liver changes ranged from the fatty degeneration of liver cells to steatohepatitis and periportal fibrosis. The present study showed mild, moderate and severe steatosis in the error bar graph association between the micro-vesicles and grade. More consumption of a high-carbohydrate diet and limited physical activity leads to an energy imbalance, followed by obesity and an increased risk of obesity-associated diseases. High fat diet, the critical risk factor for the development of HFI, is the primary cause of metabolic syndrome [20]. In our study a high fat diet leads to an increased risk factor of rat livers and leads to liver diseases.

A previous study suggested that octreotide may reduce the weight of rats with HFD-induced obesity and improve metabolism and oxidative stress disorders. An additional previous study confirmed the function of octreotide in rats with diet-induced obesity, including weight loss, decreased blood glucose, insulin concentrations and increased insulin sensitivity [20,21]. The present study, investigated the role of high fat intake in rats and obesity, revealing that overweight, altered diabetes and increased insulin sensitivity.

In our study consumption of a high-fat and high-energy diet is considered a major cause of the development of these complications. As shown in the previous study, rats that consumed a high-fat diet developed glucose intolerance, dyslipidemia and oxidative stress in the liver. Moreover, yogurt supplementation prevented the glucose intolerance and decreased plasma lipid levels in high-fat diet-fed rats [22]. Yogurt supplementation also prevented oxidative stress and decreased lipid peroxidation in the plasma and liver by restoring the cellular antioxidants.

Rats that consumed a high-fat diet exhibited increased plasma glucose levels and plasma lipid levels, including cholesterol and triglyceride

levels. The saturated fats present in the high-fat diet are responsible for the increase in the glucose and lipid profiles. According to previous studies, rat fed a high-fat diet display increased serum glucose concentrations. Rats fed a high-fat diet also developed glucose intolerance and were unable to properly utilize glucose to establish homeostasis after a glucose challenge [23].

A previous study demonstrated that increased insulin-induced gluconeogenesis and decreased glycogen synthesis are the major factors underlying the development of type 2 diabetes. These studies may explain the association between GSK3 β activity, GS mRNA expression, hepatic glycogen synthesis and plasma glucose levels in obese rats [24]. The current study may explain the high fat induced diet of the rat liver and major risk factors due to obesity, overweight and altered dietary patterns. Our team has extensive knowledge and research experience that has translate into high quality publications [25–39],[40–44] Study was limited to 5 high fat diet induced liver samples of rat further future study on diabetic rat with high fat induced insulin resistance should be included in the study. Based on the amount of food consumed, diabetic rats treated with Alogliptin received about 10–20 mg/kg rat per day.

5. CONCLUSION

We demonstrated the comparative efficiency of the PAP and H&E high fat diet induced rat liver by in vivo and conclude that both H&E and PAP stain has equal efficacy and clarity in observing the various minute parameters. Further, the perinuclear lipid accumulation was more appreciable in PAP stained sections. Also we detected important histological features such as micro-vesicular steatosis, macro-vesicular steatosis, sinusoids hepatocytes and portal vein and lipid accumulation in the nucleus. We had the chance to examine the course of liver damage closely.

CONSENT

It is not applicable.

ETHICAL APPROVAL

The study was approved by the Institutional Ethical committee with approval number IHEC/SDC/UG-1994/21/209.

SOURCE OF FUNDING

The present project is supported by:

- Saveetha Dental College and Hospitals, Saveetha University
- Saveetha Institute of Medical and Technical Sciences
- Sri Krishna medicals

ACKNOWLEDGEMENTS

We would like to thank Saveetha Dental College and Hospitals, Saveetha Institute of Medical and Technical Sciences, Saveetha University for providing us the support to conduct the study.

COMPETING INTERESTS

Authors have declared that no competing interests exist.

REFERENCES

1. Lasker S, Rahman MM, Parvez F, Zamila M, Miah P, Nahar K, et al. High-fat diet-induced metabolic syndrome and oxidative stress in obese rats are ameliorated by yogurt supplementation. *Sci Rep*. 2019;9(1):20026.
2. Lu YC, Sudirman S, Mao CF, Kong ZL. The Water Extract of *Mytilus edulis* Suppresses Oxidative Stress and Improves Male Reproduction Dysfunction in High-Fat Diet-induced Obese Rats [Internet]. Available:<http://dx.doi.org/10.20944/preprints201806.0112.v1>
3. Watkins MT. Exercise reverses metabolic syndrome in high-fat diet-induced obese rats [Internet]. Vol. 2011, Yearbook of Vascular Surgery. 2011;22-3. Available:<http://dx.doi.org/10.1016/j.yvas.2011.06.032>
4. Wang XX, Ye T, Li M, Li X, Qiang O, Tang C-W, et al. Effects of octreotide on hepatic glycogenesis in rats with high fat diet-induced obesity [Internet]. *Molecular Medicine Reports*. 2017; 16:109-18. Available:<http://dx.doi.org/10.3892/mmr.2017.6586>
5. Kumar V. Antiobesity Activity of Liraglutide on High Fat Diet-Induced Obesity in Wistar Rats [Internet]. *Current Research in Diabetes & Obesity Journal*. 2017;3. Available:<http://dx.doi.org/10.19080/crdoj.2017.03.555602>
6. Goseki-Sone M, Maruyama R, Sogabe N, Hosoi T. Effects of Dietary Lactose on Long-term High-fat-diet-induced Obesity in Rats** [Internet]. *Obesity*. 2007;15:2605-13. Available:<http://dx.doi.org/10.1038/oby.2007.312>
7. Camps J. Oxidative Stress and Inflammation in Non-communicable Diseases - Molecular Mechanisms and Perspectives in Therapeutics. Springer. 2014;223.
8. Institute of Medicine, Food and Nutrition Board, Standing Committee on the Scientific Evaluation of Dietary Reference Intakes, Subcommittee on Interpretation and Uses of Dietary Reference Intakes, Subcommittee on Upper Reference Levels of Nutrients, Panel on the Definition of Dietary Fiber, et al. *Dietary Reference Intakes for Energy, Carbohydrate, Fiber, Fat, Fatty Acids, Cholesterol, Protein, and Amino Acids*. National Academies Press. 2005;1358.
9. Yaligar J, Gopalan V, Kiat OW, Sugii S, Shui G, Lam BD, et al. Evaluation of dietary effects on hepatic lipids in high fat and placebo diet fed rats by in vivo MRS and LC-MS techniques. *PLoS One*. 2014;9(3):e91436.
10. Farrell GC, George J, de la M. Hall P, McCullough AJ. *Fatty Liver Disease: NASH and Related Disorders*. John Wiley & Sons. 2008;336.
11. Krishna M. Role of special stains in diagnostic liver pathology. *Clin Liver Dis*. 2013;2(Suppl 1):S8-10.
12. Arun Kishore RN, Priyadarshini R, Palati Sinduj, Efficacy of Methylene Blue and Papanicolaou Stain in Sex Determination-A Comparative Study, *J Res Med Dent Sci*. 2021;9(10):109-115.
13. Burt AD, Ferrell LD, Hubscher SG, Portmann BC. *MacSween's Pathology of the Liver E-Book*. Elsevier Health Sciences. 2011;820.
14. Vogel H. *Drug Discovery and Evaluation: Pharmacological Assays*. Springer Science & Business Media. 2007;2068.
15. Berry MN, Edwards AM. *The Hepatocyte Review*. Springer Science & Business Media. 2013;606.
16. Godlewski G, Gaubert-Cristol R, Rouy S, Prudhomme M. Liver development in the rat and in man during the embryonic period (Carnegie stages 11-23). *Microsc Res Tech*. 1997;39(4):314-27.

17. Muench MO. Stem Cells and Progenitors in Liver Development. Morgan & Claypool Publishers. 2012;124.
18. Telkkä A, Ahlqvist J. Succinic dehydrogenase activity and sulphhydryl groups in cirrhosis of the rat liver induced by a low protein/high fat diet [Internet]. *Acta Pathologica Microbiologica Scandinavica*. 2009;46:1–10. Available: <http://dx.doi.org/10.1111/j.1699-0463.1959.tb00309.x>
19. Muriel P. High fat diet and liver damage induced by biliary obstruction in the rat [Internet]. *Journal of Applied Toxicology*. 1995;15:125–8. Available: <http://dx.doi.org/10.1002/jat.2550150211>
20. Alghamdi S. Magnetic resonance characterisation of developing hepatocellular carcinoma in a diet induced model of liver cancer in the rat [Internet]. Available:<http://dx.doi.org/10.14264/uql.2017.729>
21. Welles J. A Comprehensive Overview of the Effects of Diet on the Hepatic Transcriptome and Translatome in Rat Liver;2021.
22. Rees AL. Review: Film Art Phenomena * Review: The Undercut Reader: Critical Writings on Artists' Film and Video * Review: Experimental Cinema: the Film Reader (In Focus: Routledge Film Readers Series) [Internet]. *Screen*. 2004;45:440–6. Available:<http://dx.doi.org/10.1093/screen/45.4.440>
23. Misiakiewicz-Has K, Maciejewska-Markiewicz D, Rzeszotek S, Pilutin A, Kolasa A, Szumilas P, et al. The Obscure Effect of Saponins Plus Inulin on Liver Morphology, Liver Fatty Acids, Plasma Glucose, and Lipid Profile in SD Rats with and without Induced Type 2 Diabetes Mellitus. *Int J Mol Sci* [Internet]. 2021;22(16). Available:<http://dx.doi.org/10.3390/ijms22168680>
24. Hsu C-L, Yen G-C. Effect of gallic acid on high fat diet-induced dyslipidaemia, hepatosteatosis and oxidative stress in rats. *Br J Nutr*. 2007;98(4):727–35.
25. Anita R, Paramasivam A, Priyadharsini JV, Chitra S. The m6A readers YTHDF1 and YTHDF3 aberrations associated with metastasis and predict poor prognosis in breast cancer patients. *Am J Cancer Res*. 2020;10(8):2546–54.
26. Jayaseelan VP, Paramasivam A. Emerging role of NET inhibitors in cardiovascular diseases. *Hypertens Res*. 2020;43(12):1459–61.
27. Sivakumar S, Smiline Girija AS, Vijayashree Priyadharsini J. Evaluation of the inhibitory effect of caffeic acid and gallic acid on tetR and tetM efflux pumps mediating tetracycline resistance in *Streptococcus* sp., using computational approach. *Journal of King Saud University - Science*. 2020;32(1):904–9.
28. Smiline Girija AS. Delineating the Immuno-Dominant Antigenic Vaccine Peptides Against *gacS*-Sensor Kinase in *Acinetobacter baumannii*: An in silico Investigational Approach. *Front Microbiol*. 2020;11:2078.
29. Iswarya Jaisankar A, Smiline Girija AS, Gunasekaran S, Vijayashree Priyadharsini J. Molecular characterisation of *csgA* gene among ESBL strains of *A. baumannii* and targeting with essential oil compounds from *Azadirachta indica*. *Journal of King Saud University - Science*. 2020;32(8):3380–7.
30. Girija ASS. Fox3+ CD25+ CD4+ T-regulatory cells may transform the nCoV's final destiny to CNS! *J Med Virol* [Internet]; 2020. Available:<http://dx.doi.org/10.1002/jmv.26482>
31. Jayaseelan VP, Ramesh A, Arumugam P. Breast cancer and DDT: putative interactions, associated gene alterations, and molecular pathways. *Environ Sci Pollut Res Int*. 2021;28(21):27162–73.
32. Arumugam P, George R, Jayaseelan VP. Aberrations of m6A regulators are associated with tumorigenesis and metastasis in head and neck squamous cell carcinoma. *Arch Oral Biol*. 2021;122:105030.
33. Kumar SP, Girija ASS, Priyadharsini JV. Targeting NM23-H1-mediated inhibition of tumour metastasis in viral hepatitis with bioactive compounds from *Ganoderma lucidum*: A computational study. *pharmaceutical-sciences* [Internet]. 2020;82(2). Available:<https://www.ijpsonline.com/article/s/targeting-nm23h1mediated-inhibition-of-tumour-metastasis-in-viral-hepatitis-with-bioactive-compounds-from-ganoderma-lucidum-a-comp-3883.html>
34. Girija SA, Priyadharsini JV, Paramasivam A. Prevalence of carbapenem-hydrolyzing OXA-type β -lactamases among

- Acinetobacter baumannii in patients with severe urinary tract infection. Acta Microbiol Immunol Hung. 2019;67(1):49–55.
35. Priyadharsini JV, Paramasivam A. RNA editors: key regulators of viral response in cancer patients. Epigenomics. 2021;13(3):165–7.
36. Mathivadani V, Smiline AS, Priyadharsini JV. Targeting Epstein-Barr virus nuclear antigen 1 (EBNA-1) with Murraya koengii bio-compounds: An in-silico approach. Acta Virol. 2020;64(1):93–9.
37. Girija As S, Priyadharsini JV, AP. Prevalence of Acb and non-Acb complex in elderly population with urinary tract infection (UTI). Acta Clin Belg. 2021;76(2):106–12.
38. Anchana SR, Girija SAS, Gunasekaran S, Priyadharsini VJ. Detection of csgA gene in carbapenem-resistant Acinetobacter baumannii strains and targeting with Ocimum sanctum biocompounds. Iran J Basic Med Sci. 2021;24(5):690–8.
39. Girija ASS, Shoba G, Priyadharsini JV. Accessing the T-Cell and B-Cell Immuno-Dominant Peptides from A.baumannii Biofilm Associated Protein (bap) as Vaccine Candidates: A Computational Approach. Int J Pept Res Ther. 2021;27(1):37–45.
40. Arvind P TR, Jain RK. Skeletally anchored forsus fatigue resistant device for correction of Class II malocclusions-A systematic review and meta-analysis. Orthod Craniofac Res. 2021 Feb;24(1):52–61.
41. Venugopal A, Vaid N, Bowman SJ. Outstanding, yet redundant? After all, you may be another Choluteca Bridge! Semin Orthod. 2021;27(1):53–6.
42. Ramadurai N, Gurunathan D, Samuel AV, Subramanian E, Rodrigues SJL. Effectiveness of 2% Articaine as an anesthetic agent in children: randomized controlled trial. Clin Oral Investig. 2019;23(9):3543–50.
43. Varghese SS, Ramesh A, Veeraiyan DN. Blended Module-Based Teaching in Biostatistics and Research Methodology: A Retrospective Study with Postgraduate Dental Students. J Dent Educ. 2019; 83(4):445–50.
44. Mathew MG, Samuel SR, Soni AJ, Roopa KB. Evaluation of adhesion of Streptococcus mutans, plaque accumulation on zirconia and stainless steel crowns, and surrounding gingival inflammation in primary molars: randomized controlled trial [Internet]. Clinical Oral Investigations. 2020;24:3275–80. Available: <http://dx.doi.org/10.1007/s00784-020-03204-9>
45. Altunkaynak Z. Effects of high fat diet induced obesity on female rat livers (a histochemical study) [Internet]. Electronic Journal of General Medicine. 2005;2. Available: <http://dx.doi.org/10.29333/ejgm/82319>
46. Berry MN, Friend DS. High-yield preparation of isolated rat liver parenchymal cells: a biochemical and fine structural study. J Cell Biol. 1969;43(3):506–20.
47. Ulla A, Alam MA, Sikder B, Sumi FA, Rahman MM, Habib ZF, et al. Supplementation of Syzygium cumini seed powder prevented obesity, glucose intolerance, hyperlipidemia and oxidative stress in high carbohydrate high fat diet induced obese rats. BMC Complement Altern Med. 2017;17(1):289.
48. Marti A, Aguilera CM. Obesity: Oxidative Stress and Dietary Antioxidants. Academic Press; 2018;304.
49. Panchal SK, Ward L, Brown L. Ellagic acid attenuates high-carbohydrate, high-fat diet-induced metabolic syndrome in rats. Eur J Nutr. 2013;52(2):559–68.

© 2021 Sri et al.; This is an Open Access article distributed under the terms of the Creative Commons Attribution License (<http://creativecommons.org/licenses/by/4.0>), which permits unrestricted use, distribution, and reproduction in any medium, provided the original work is properly cited.

Peer-review history:

The peer review history for this paper can be accessed here:
<https://www.sdiarticle5.com/review-history/77543>