



# Wound Healing Activity of Two Honeys from the Southern Regions of Senegal (Casamance)

Mbaye AI <sup>a\*</sup>, Diatta K <sup>a</sup>, Sarr A <sup>a</sup>, Dieng SIM <sup>a</sup>, Dieng ML <sup>a</sup>,  
Diatta W <sup>a</sup>, Sene M <sup>b</sup> and Fall AD <sup>a</sup>

<sup>a</sup> Laboratoire de Pharmacognosie et Botanique, Université Cheikh Anta Diop (UCAD), Sénégal.

<sup>b</sup> Laboratoire de Pharmacologie et Physiologie, Université Cheikh Anta Diop (UCAD), Sénégal.

## Authors' contributions

This work was carried out in collaboration among all authors. Authors SM and FAD conceptualized and validated the study. Authors MAI and SA performed the methodology. Authors MAI, DML and DSIM tested the samples. Authors DK and MAI edited the manuscript and did data analysis. Authors DW and FAD contributed to supervised the study. All authors read and approved the final manuscript.

## Article Information

DOI: <https://doi.org/10.9734/ajrb/2024/v14i6328>

## Open Peer Review History:

This journal follows the Advanced Open Peer Review policy. Identity of the Reviewers, Editor(s) and additional Reviewers, peer review comments, different versions of the manuscript, comments of the editors, etc are available here: <https://www.sdiarticle5.com/review-history/125136>

Original Research Article

Received: 14/08/2024

Accepted: 16/10/2024

Published: 19/10/2024

## ABSTRACT

**Aim:** The aim of this study was to evaluate the healing activity of two honeys from Casamance (Senegal) in a second-degree experimental burn model in the Wistar strain rat.

**Methodology:** Experimental burns were induced using a metal cylinder 3 cm in diameter and heated for 5 min. The cylinder was applied for 20 seconds, pressing lightly on the surface of the rats' shaved skin to induce second-degree burns.

**Results:** The daily application of honey induces a healing dependent on concentration and topology. The healing rate is higher with AF, with a score of  $0.60 \pm 0.48$  vs  $1.00 \pm 0.00$  for MZ which induces almost complete tissue repair after 21 days of treatment.

\*Corresponding author: E-mail: amembaaye@gmail.com;

**Cite as:** AI, Mbaye, Diatta K, Sarr A, Dieng SIM, Dieng ML, Diatta W, Sene M, and Fall AD. 2024. "Wound Healing Activity of Two Honeys from the Southern Regions of Senegal (Casamance)". *Asian Journal of Research in Biochemistry* 14 (6):71-78. <https://doi.org/10.9734/ajrb/2024/v14i6328>.

**Conclusion:** The results of this study demonstrate the use of traditional honey in wound healing and burns.

*Keywords:* Honeys; burns, wounds; cicatrization; Casamance.

## ABBREVIATIONS

MZ : Mangrove Ziguinchor

AF : Anacardium Faoune

## 1. INTRODUCTION

Hippocrates (460-377 BC), the “spiritual father” of medicine, said that the use of honey led to greater old age, and prescribed it to combat fever, wounds, ulcers and purulent wounds [1]. In the Middle Ages, honey was used to make gingerbread, but also to make bandages without first disinfecting wounds [2]. During the First and Second World Wars, honey was used extensively to accelerate the healing of soldiers' wounds [2]. Wound healing is a dynamic physiological process initiated and influenced by many factors. This process can be divided into four phases: hemostasis, inflammation, proliferation (including granulation, contraction and epithelialization) and final remodelling [3]. The duration of each phase will depend on the nature of the wound, its severity and the care provided [4]. Today, many scientists have conducted therapeutic trials of honey in the treatment of wounds in Wistar rats, horses and humans [5-9]. Chemically, honey is composed of sugar (70-80%), water (10-20%), organic acids, minerals, vitamins, proteins, phenolic compounds and free amino acids. The main monosaccharide components of honey are glucose and fructose. Honey has long been used to treat wounds and other skin conditions [10,11] and has been known to improve healing time, for example, in superficial and partial-thickness mild to moderate burns, although evidence of efficacy in others is inconclusive at present [12,13]. Honey has been shown to have antimicrobial effects [14,15 and 11] which are due to a combination of low water activity, low pH, hydrogen peroxide production etc. [16]. Many of the compounds present in honey are also antioxidants [17-19]. Various dressings and gels containing honey are now available [7,12,13], but the effect of honey on wound healing parameters has not been well studied, especially in Senegal, where according to the bibliography no studies have been carried out to date. With this in mind, we set out to investigate the wound-healing effects of two honeys harvested in Casamance (Senegal) in a model of

experimental second-degree burns in Wistar rats.

## 2. MATERIALS AND METHODS

### 2.1 Sampling

The honey was obtained from beekeepers owning honey production units on 17 Mars 2024. The honeys are of *Avicennia* (MZ) and *Anacardium* (AF) origin. They were placed in hermetically sealed jars and kept in the refrigerator at the Laboratory of Pharmacognosy and Botany at the Faculty of Medicine, of Pharmacy and of Odontology of the Cheikh Anta DIOP University (UCAD) of Dakar.

### 2.2 Animals

The weights of the rats varied between 167 and 356 g. The animals were housed in a cage under conditions of  $25 \pm 2^{\circ}\text{C}$  temperature, 12 h light cycle and provided with food and water ad libitum.

### 2.3 Methodology

Healing activity was assessed in an experimental rat burn model [20]. Twenty rats were divided into 4 batches of 5 as follows : - Batch 1 : untreated rats - Batch 2 : sulfadiazine (healing drug) -- Batch 3 : rats treated with Mangrove Z honey (MZ) and Batch 4 : rats treated with Anacarde F honey (AF). Rats were then anaesthetized with 3% chloral solution by intraperitoneal injection (1 mL /100 g). The rats' dorsal flanks were shaved and cleaned. Experimental burns were induced using a 3 cm diameter metal cylinder and heated for 5 min. The cylinder was applied for 20 seconds by pressing a little on the surface of the rats' shaved skin to induce second-degree burns [21].

Healing activity was assessed by a method of determining scores varying according to the extent of the burn (Table 1) [22]. Scores were assessed every four days for 28 days.

### 2.4 Statistical Analysis

Data were expressed as mean  $\pm$  standard error of the mean (SEM). They were analyzed by

**Table 1. Scores of the evolution of experimental burns**

Score	Cicatrizization process evaluation
0	Healing is complete and tissue repair is complete
1	Tissue healing is almost complete
2	Remnants of the crust remain the size of the lesion decreases (skin reconstruction)
3	All dead tissues (scabs) are removed, wounds and oozing
4	Necrotic skin is partially removed, ulcerated and oozing
5	Necrotic skin completely covers the burned area

GraphPad 10.0 software. A one-way analysis of variance (ANOVA) followed by Dunnett's post hoc test against the control group. P-values <0.05 Table 1: Scores of the evolution of experimental burns.

### 3. RESULTS AND DISCUSSION

#### 3.1 Results

##### 3.1.1 Evolution of experimental second-degree burn scores in untreated rats

Seven days after induction of the experimental burn, the burned area was still covered with necrotic skin, corresponding to a score of 5. After 3 weeks, in the absence of treatment, the burned skin showed ulceration that was still oozing (score 4). After 4 weeks, the experimental burn consists of an open, oozing wound (score 2.75), corresponding to a total absence of healing.

##### 3.1.2 Evolution of experimental second-degree burn scores in rats after daily application of sulfadiazine

The experimental burn score in the sulfadiazine group after 2 weeks of treatment was not significantly different from that in the untreated

group or after the application of Vaseline. After 3 weeks, the burn score was 3.5, corresponding to an oozing wound. Tissue repair, although significant, was incomplete after 4 weeks, confirming that this was indeed a second-degree burn.

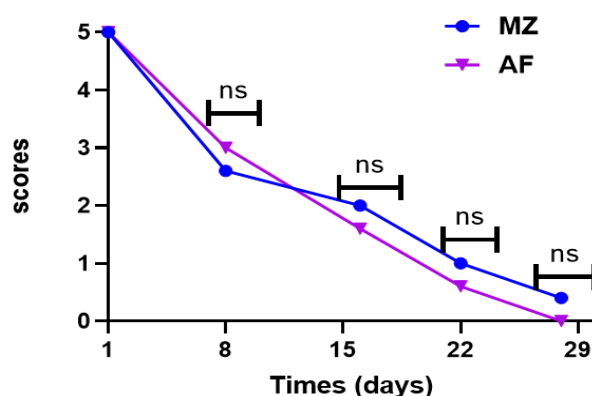
##### 3.1.3 Evolution of scores in a burn treated with MZ and AF honey

Daily application of the honey showed a score equal to 2.75 after 14 days for MZ honey and a score equal to 1.6 after 14 days for AF. These scores were significantly different from those of the untreated group. The speed of healing is greater with AF honey, which induces almost complete tissue repair after 21 days (score 0.6) (Fig. 1).

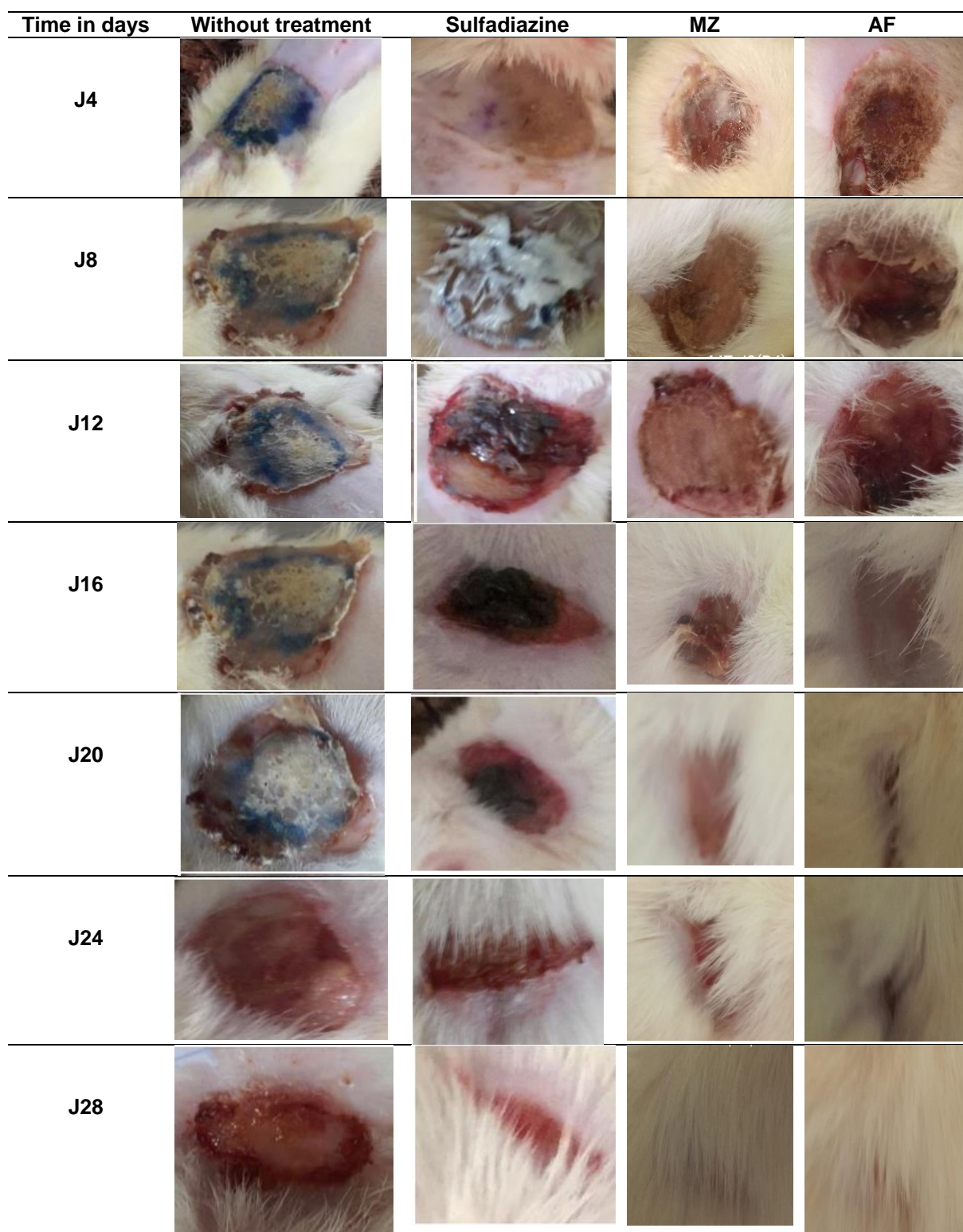
#### 3.2 Discussion

The aim of the present study was to demonstrate the healing activity of honey in a model of experimental second-degree burns in Wistar rats.

Sulfadiazine applied daily to the burn for 4 weeks, was not associated with complete healing. Sulfadiazine is most often used as a reference product in clinical trials of first-degree



**Fig. 1. Evolution of deep second-degree experimental burn scores in rats AF and MZ application**  
 ns: no significant



**Fig. 2. Images of the healing activity of MZ and AF honey in a deep second-degree burn**

burns [23]. The lack of healing after four weeks of sulfadiazine treatment in this study suggests that the experimental burn caused at least a deep second-degree burn. Our results are similar

to several other studies of honey in a second-degree burn model, and the rate of healing is almost complete beyond three weeks [5,24].

Honeys induce concentration-dependent wound healing in the Wistar rat model of experimental deep second-degree burns. Indeed, healing is faster with AF than MZ honey.

Four studies [25-28] have demonstrated the benefits of honey for ulcer healing. Results demonstrated shorter average healing times, higher total healing rates and more effective elimination of wound infection. According to [25], honey therapy has been shown to be cost-effective.

In a study by [29], wound odour and pain were reduced, but the difference in healing time was not statistically significant.

We have found that honey can be beneficial for wounds. It is a curative treatment used locally in various healing models. According to [30], honey's acidic pH and excessive tonicity are the main elements that promote burn healing. According to our experiments, honey can also promote wound healing when administered to rats. The glycolytic enzyme activity in honey accelerates wound healing by providing sufficient energy for cell repair. Collagen formation, wound contraction and epithelialization remain crucial phases in wound healing. In this way, intervention in any of these stages can lead to stimulation or reduction of the collagen production phase of healing [31]. According to [32] complete healing is due to the presence of flavonoids and tannins in plants. In addition to the mechanisms involved in wound healing, there are also antioxidant, anti-inflammatory and antimicrobial properties present in plants [33]. These properties are also confirmed in different types of honey [34-36].

During our manipulations, we noted an absence of stench and tingling phenomena leading to scratching of the wounds. This finding has been observed by other authors in surgical wound treatments using honey [37].

#### 4. CONCLUSION

The aim of this study was to evaluate the healing activity of Senegalese honey in a model of experimental second-degree burns in Wistar rats. AF honey achieved almost complete tissue repair after 22 days. This healing effect may be linked to the presence of hydrogen peroxide methylglyoxal. The results obtained highlight the therapeutic potential of these honeys in the treatment of second-degree burns, which would

justify their use in traditional settings for the treatment of wounds and burns. Future studies should focus on the use of honeys in the healing process of surgical wounds.

#### DISCLAIMER (ARTIFICIAL INTELLIGENCE)

Author(s) hereby declare that NO generative AI technologies such as Large Language Models (ChatGPT, COPILOT, etc) and text-to-image generators have been used during writing or editing of this manuscript.

#### ETHICAL APPROVAL

The experimental protocols were conducted in accordance with the guidelines of the Institutional Ethics Committee (Research Ethics Committee of CADU).

#### ACKNOWLEDGEMENT

We would like to thank all the staff of the Pharmacognosy and Botany Laboratory and the Pharmacology and Physiology Laboratory of Cheikh Anta Diop University, Dakar, Senegal.

#### COMPETING INTERESTS

Authors have declared that no competing interests exist.

#### REFERENCES

1. Domeregov R. Santé, bien-être, apithérapie. In *Le traité rustica de l'apiculture*. Paris, Rustica. 2002;390-416.
2. Rossantv A. Le miel, un composé complexe aux propriétés surprenantes, Thèse de doctorat d'état, Université de Limoges, France, 2011 ;136.
3. Meaume S, Dereure O, Téot L. Plaies et cicatrisations. Paris: Masson. 2005;456.
4. Monstrey S. Honey in modern wound care: a systematic review. *Burns*. 2013;39(8): 1514–1525. PMID: 23896128. DOI: 10.1016/j.burns.2013.06.014
5. Prafulla CT, Ahamed N, Keshari C, Kalpesh N. Comparative study of wound healing activity of soframycin & honey in excision wound model. *International Journal of Pharmacy & Technology*. 2015; 5(1):5378-5382. ISSN : 0975-766X.
6. Khiati B, Bacha S, Aissat S, Ahmed M. The use of Algerian honey on cutaneous

- wound healing: A case report and review of the literature *Asian Pac J Trop Dis.* 2014;(Suppl 2):S867-S869:3.  
DOI:[https://doi.org/10.1016/S2222-1808\(14\)60748-9](https://doi.org/10.1016/S2222-1808(14)60748-9).
7. Gulati S, Qureshi A, Srivastava A, Kataria K, Kumar P. A prospective randomized study to compare the effectiveness of honey dressing vs. povidone iodine dressing in chronic wound healing Balakrishna J.A. *Indian J Surg.* 2014; 76(3):193-198.  
DOI: <https://doi.org/10.1007/s12262-012-0682-6>
  8. Samarghandian S, Farkhondeh T, Samini F. Honey and Health: A review of recent clinical research. *Pharmacognosy Res.* 2017;9(2):121-7.  
DOI: 10.4103/0974-8490.204647
  9. Tsang KK, Kwong EWY, Shun To TSS, Chung JWY, Wong TKS. A pilot randomized, controlled study of nanocrystalline silver, Manuka honey, and conventional dressing in healing diabetic foot ulcer Evidence-Based Complementary and Alternative Medicine; 2017.  
ISSN: 1741-427X.  
DOI: 10.1155/2017/5294890
  10. Chuemere AN, Ilochi O, Nwafor C. Evaluation of Blood Glucose-regulating Potential of Honey, Coffee and Vitamin E in Normoglycaemic Male Wistar Rats *Asian Journal of Research in Medical and Pharmaceutical Sciences.* 2018;4(4)  
ISSN: 2457-0745.  
DOI:<https://doi.org/10.9734/AJRIMPS/2018/4413311>
  11. Amaravathi D. Evaluation of Antimicrobial Efficacy and Physico Chemical Properties of Raw and Processed Honey, *International Journal of Science and Research (IJSR).*2021;10(2):8.  
ISSN: 2319-7064.  
DOI:<https://doi.org/10.21275/SR21217090113>
  12. Evans J, Flavin S. Honey: A guide for healthcare professionals. *Br J Nurs.* 2008;17(15):S24, S26:S28-30.  
Available:<https://doi.org/10.12968/bjon.2008.17.Sup6.30707>
  13. Jull AB, Rodgers A, Walker N. Honey as adjuvant leg ulcer therapy trial collaborators. Randomized clinical trial of honey-impregnated dressings for venous leg ulcers. *Cochrane Database Syst Rev.* 2008;(4):CD005083.  
Available:<https://doi.org/10.1002/14651858.CD005083.pub4>
  14. Uran H, Filiz A, Dilek DA. A research on the chemical and microbiological qualities of honeys sold in Istanbul. *Food Sci. Technol, Campinas.* 2017;37(Suppl.1):30-33.  
DOI: <http://dx.doi.org/10.1590/1678-457X.32016>
  15. Adamu HI, Rabi'u I, Inah MB. A Review on the Use of Honey in the Treatment of Wound Infection *Asian Food Science Journal.* 2021;20(1):51-59.  
ISSN: 2581-7752  
DOI:<https://doi.org/10.9734/AFSJ/2021/v20i130253>
  16. Mundo MA, Padilla-Zakour OI, Worobo RW. Growth inhibition of food-borne pathogens and food spoilage organisms by select raw honeys. *Int J Food Microbiol.* 2004;97(1):1-8.
  17. Gül A, Pehlivan T. Antioxidant activities of some monofloral honey types produced across Turkey. *Saudi Journal of Biological Sciences.* 2018;25(6):1056-1065.  
ISSN:1319-562X  
Available:<https://doi.org/10.1016/j.sjbs.2018.02.011>
  18. Louaifi S, Takka Y. Activité antioxydante de quelques produits de la ruche, Mémoire de master, Université de Béjaïa, Algérie, 2019 ;56.
  19. Aker D, Nisbet C. Antioxidant activities, total phenolic and flavonoid contents of honey collected from different botanical origins. *Ankara Üniv Vet Fak Derg.* 2020;6:133-136.  
DOI:<https://doi.org/10.33988/auvfd.523745>
  20. Gurung S, Škalko-Basnet N. Wound healing properties of *Carica papaya* latex: in vivo evaluation in mice burn model. *J. Ethnopharmacol.* 2009;121(2):338-341.  
DOI:<https://doi.org/10.1016/j.jep.2008.10.030>
  21. Hoşnuter M, Gürel A, Babuççu O, Armutcu F, Kargı E, İşikdemir A. The effect of CAPE on lipid peroxidation and nitric oxide levels in the plasma of rats following thermal injury. *Burns.* 2004;30(2):121-125.  
DOI:<https://doi.org/10.1016/j.burns.2003.09.022>

22. Adhya A, Bain J, Ray O, Hazra A, Adhikari S, Dutta G, Ray S. Healing of burn wounds by topical treatment: A randomized controlled comparison between silver sulfadiazine and nano-crystalline silver. Majumdar, B.K. J. Basic Clin. Pharmacol. 2015;6(1):29-34.  
DOI:<https://doi.org/10.4103/09760105.145776>
23. SFETB. Société Francophone de Brûlologie. Consulté le 23 Septembre 2024; 2006.  
Available:<http://www.sfbbrulure.com/docs/2017/soins-locauxbrules-suivis-ambulatoire.pdf>
24. Iftikhar F, Arshad M, Rasheed F, Amraiz D, Anwar P and Gulfraz M. Effects of Acacia Honey on Wound Healing in Various Rat Models Phytother. Res. 2010;24:583–586.  
DOI: 10.1002/ptr.2990
25. Moghazy AM, Shams ME, Adly OA, Abbas AH, El-Badawy MA, Elsakka DM, Hassan SA, Abdelmohsen WS, Ali OS, Mohamed BA. The clinical and cost effectiveness of bee honey dressing in the treatment of diabetic foot ulcers. Diabetes Research and Clinical Practice. 2010;89(3):276–281.  
DOI: 10.1016/j.diabres.2010.05.021
26. Kamaratos A, Tzirogiannis K, Iraklianos S, Panoutsopoulos G, Kanellos I, Melidonis A. Manuka honey-impregnated dressings in the treatment of neuropathic diabetic foot ulcers. International Wound Journal. 2014;11(3):259–263.  
DOI: 10.1111/j.1742-481X.2012.01082.x
27. Al Saeed M. Therapeutic efficacy of conventional treatment combined with manuka honey in the treatment of patients with diabetic foot ulcers: a randomized controlled study The Egyptian Journal of Hospital Medicine. 2013;53:1064–1071.  
DOI: <https://doi.org/10.12816/0001668>
28. Imran M, Hussain MB, Baig M. A randomized, controlled clinical trial of honey-impregnated dressing for treating diabetic foot ulcer. J Journal of the College of Physicians and Surgeons - Pakistan: JCPSP. 2015;25(10):721–725.  
PMID: 26454386  
DOI:<https://doi.org/10.2015/JCPSP.721725>
29. Shukrimi A, Sulaiman AR, Halim AY, Azril AA. Comparative study between honey and povidone iodine as dressing solution for Wagner type II diabetic foot ulcers. Med J Malaysia. 2008;63(1):44–46.  
PMID: 18935732.
30. Postmes TJ, Bosch MMC, Dutrieux R, van Baare J, Hoekstra MJ. Speeding up the healing of burns with honey. An experimental study with histological assessment of wound biopsies. In Bee products: Properties, applications and apitherapy, Mizrahi A, Lensky Y (eds). Plenum Press: New York. 1997;27–37.  
DOI: [https://doi.org/10.1007/978-1-4757-9371-0\\_6](https://doi.org/10.1007/978-1-4757-9371-0_6)
31. Vyhlídalová D, Kozáková R, Zeleníková R. Management of non-healing wounds with honey dressings: a literature review Cent Eur J Nurs Midw. 2018;9(3):880–888  
DOI:<https://doi.org/10.15452/CEJNM.2018.09.0019>
32. Sène M, Tine Y, Keita F, Zougouri KAD, Sarr A, Diatta C, Barboza FS, Ndiaye M, Sy AN and Sy G Y. In vivo anti-inflammatory and healing activities of the methanolic fraction of *Combretum glutinosum* Perr. Bark. Phytomol. Pharmacol. 2023;2(2):55-63.  
Available :<https://doi.org/10.56717/jpp.2023.v02i02.018>
33. Sène M, Ndiaye M, Barboza FS, Sene M, Diatta W, Sarr A, Ndiaye SA, Dieye AM and Sy GY. Activité anti-inflammatoire de l'extrait aqueux des feuilles d'*Elaeis guineensis* Jacq. (Arecaceae) sur l'œdème aigu de la patte de rat induit par la carraghénine Int. J. Biol. Chem. Sci. 2016;0(6):2568-2574.  
DOI:<http://dx.doi.org/10.4314/ijbcs.v10i6.13>
34. Goutam M, Sangita RC, Sanchita M. A Review on change in chemical, morphological and therapeutic activity of honey. Asian Journal of Pharmacy and Pharmacology. 2018;4(5):582-588. DOI: <https://doi.org/10.31024/ajpp.2018.4.5.6>
35. Asaduzzaman M, Sohanur MR, Sirajam M, Muedur MR, Minarul I, Mahadi H, Abdul MH, Shahangir B, Masudul HK, Matiar R , Mohammad AI. Analysis of Biochemical Composition of Honey and its Anti-Oxidant, Phytochemical and AntiBacterial Properties. Journal of Biomedical and Pharmaceutical Research. 2015;4(4).  
ISSN: 2279–0594:69-81.

36. Mohamed H, Salma MA, Al Lenjawi B, Abdi S, Gouda Z, Barakat N, Elmahdi H, Abraham S, Hamza AH, Al Khozaei D, Al Majid S, Al Majid H, Abdini J, Al Jaber M, Al Maseh F, Al Ali AA. The efficacy and safety of natural honey on the healing of foot ulcers: a case series. *Wounds*. 2015;27(4):103–114. PMID: 25855854.
37. Sène M, Barboza FS, Sarr A, Sarr A, Fall AD, Ndione Y, SY G. Healing and topical anti-inflammatory activities of the total aqueous bark extract of *Combretum glutinosum* Perr. (Combretaceae). *J. Med. Plants Res*. 2020;14(5):215-24.

**Disclaimer/Publisher's Note:** The statements, opinions and data contained in all publications are solely those of the individual author(s) and contributor(s) and not of the publisher and/or the editor(s). This publisher and/or the editor(s) disclaim responsibility for any injury to people or property resulting from any ideas, methods, instructions or products referred to in the content.

© Copyright (2024): Author(s). The licensee is the journal publisher. This is an Open Access article distributed under the terms of the Creative Commons Attribution License (<http://creativecommons.org/licenses/by/4.0>), which permits unrestricted use, distribution, and reproduction in any medium, provided the original work is properly cited.

*Peer-review history:*

*The peer review history for this paper can be accessed here:*

<https://www.sdiarticle5.com/review-history/125136>