

---

## PROTECTIVE AND THERAPEUTIC EFFECTS OF OLIVE OIL AND *FICUS CARICA* ON THE HISTOLOGICAL AND CYTOLOGICAL INJURIES OF LIVER AND KIDNEY IN $\gamma$ -IRRADIATED MALE ALBINO RATS

---

Ahmed A. Gafar<sup>a</sup>, Mahmoud A. Khalifa<sup>a</sup>, Fathy Elshaer<sup>a</sup>,

<sup>a</sup> Zoology Department, Faculty of Science, Al-Azhar University, Cairo, Egypt.

---

### ABSTRACT

The present study was designed to determine the possible protective and therapeutic effects of olive oil and/or *Ficus carica* against radiation-induced cytological and histological changes in liver and Kidney of male albino rats. Irradiation was performed by whole-body exposure of rats to an acute single dose gamma radiation of 6 Gy. Irradiated rats received, via gavage, extra virgin olive oil (7.6 ml/kg b.wt), and/or extract of *Ficus carica* fruit (1 g/kg b.wt) before and/or after radiation exposure. Six rats were sacrificed on the 1<sup>st</sup> and 15<sup>th</sup>-day post-irradiation exposure at the control and treated irradiated subgroups. Time duration for this experiment was one month.

The  $\gamma$ -Irradiation treated group revealed histopathological alterations in the hepatic and renal tissues on the 1<sup>st</sup> and 15<sup>th</sup>-day post-irradiation as compared to the control rats. The administration of the olive oil and/or *Ficus carica* showed beneficial results against the deleterious effects of  $\gamma$ -irradiation. A better ameliorative effect was noticed with the combined treatments that revealed the synergistic effect between them.

In conclusion, the administration of the olive oil and/or *Ficus carica* provides considerable radioprotective and radiotherapeutic effects against whole body  $\gamma$ -radiation in male Wistar albino rats.

**Keywords:** Olive oil; *Ficus carica*;  $\gamma$ -radiation; histology; cytology.

### 1. INTRODUCTION

Exposure to ionizing radiation is characterized by the production of reactive oxygen species (ROS) and reactive nitrogen species (RNS) which cause tissue damage and cell death (Maith *et al.*, 1999). ROS are chemically reactive molecules containing oxygen. The ROS react with biological molecules and destroy the structure of cells (Baatout *et al.*, 2004). They are often responsible for lipid peroxidation, protein denaturation and impaired enzyme activity (Karbownik and Reiter, 2000). Oxidative stress is an expression used to describe various deleterious processes resulting from an imbalance between the excessive formation of ROS and limited antioxidant defenses and that affect cells and tissues (Turrens, 2003).

Many reports pointed out that the uses of chronic administration of plant extracts might augment the major cellular endogenous antioxidants, and so it could be identified as a promising strategy to combat oxidative stress (El Habit *et al.*, 2000; Saada and Azab, 2001 and Lemos *et al.*, 2012).

The major benefit of the Mediterranean diet is its high level of natural antioxidants, derived from vegetables and fruits, including olive oil and figs, which contribute antioxidant vitamins, minerals and higher polyphenol content (Solomon *et al.*, 2006). In addition, the mixed plant extract showed a higher diversity of polyphenols resulted in greater stability and bioaccessibility of antioxidants compared with the single extract (Kamiloglu *et al.*, 2014 and Rubio *et al.*, 2014).

### MATERIALS AND METHODS

#### Ethics statement

All animals in our study were handled in accordance with the ethical guidelines for investigations using laboratory animals and complied with the guide for the care and use of laboratory animals (Institute of Laboratory Animal Resources 1996).

#### Animal care and handling

A patch of 114 male Wistar albino rats averaged weights  $120 \pm 5$  g were used at the beginning of the experiment and were divided

into 8 main groups and 19 subgroups according to the treatment and requirements of the experiment. Time duration for this experiment was one month.

The rats obtained from the Egyptian Holding Company for Biological Products and Vaccines. The rats were transferred to the animal house in Zoology Department, Faculty of Science, Al-Azhar University, and placed in regular designed cages and maintained in conditions of good ventilation, normal temperatures, and humidity range. Six rats were placed in each cage. Food and water were provided *ad libitum* to the animals.

\* Protective group: male rats orally injection with olive oil (single daily dose for 14

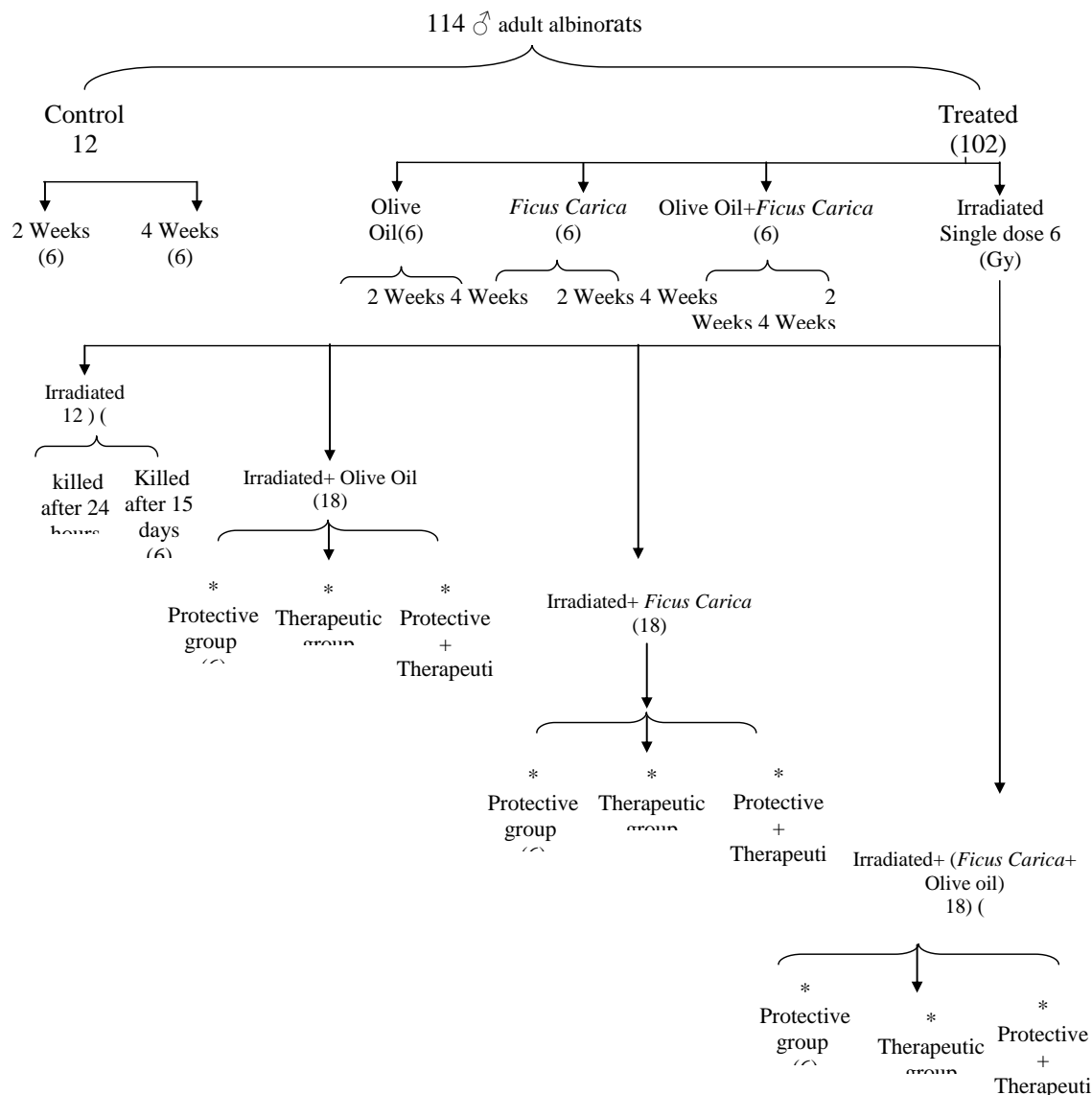
successive days), then after one hour of the last administration, animals irradiated a single dose of whole-body  $\gamma$ -rays (6 Gy) and then killed after 24 hours.

\* Therapeutic group: animals were irradiated with a single dose (6 Gy) of whole-body  $\gamma$ -rays then after one hour they administered olive oil for 15 days then killed.

\* Protective + Therapeutic group: animals received olive oil for 14 consecutive days, then after one hour of the last administration, animals irradiated a single dose of whole-body  $\gamma$ -rays (6 Gy) and received again olive oil in same dose for 15 days.

Figure (1): Steps of experimental design of the present study.

• **Group 1:** Normal male rats for 2 weeks.



- **Group 2:** Normal male rats for 4 weeks.
- **Group 3:** Male rats orally injection with olive oil (single daily dose (7.6 ml/kg b.wt) for 14 successive days) then killed in day 15. (6 Rats).
- **Group 4:** Male rats orally injection with olive oil (single daily dose (1 g/kg b.wt) for 30 successive days) then killed in day 31. (6 Rats).
- **Group 5:** Male rats orally injection with *Ficus carica* extract ( single daily dose for 14 successive days) then killed in day 15. (6 Rats).
- **Group 6:** Male rats orally injection with *Ficus carica* extract (single daily dose for 30 successive days) then killed in day 31. (6 Rats).
- **Group 7:** Male rats orally injection with olive oil and *Ficus carica* (single daily dose for 14 successive days) then killed in day 15. (6 Rats).
- **Group 8:** Male rats orally injection with olive oil and *Ficus carica* (single daily dose for 30 successive days) then killed in day 31. (6 Rats).
- **Group 9:** Irradiated rats, male rats exposed to acute single dose 6 Gy whole body gamma rays then killed after 24 hours (6 Rats).
- **Group 10:** IR group, animals were irradiated with a single dose (6 Gy) of whole-body  $\gamma$ -rays and left for 15 days then killed.
- **Group 11:** Male rats orally injection with olive oil (single daily dose for 14 successive days), then after one hour of the last administration, animals irradiated a single dose of whole-body  $\gamma$ -rays (6 Gy) and then killed after 24 hours. (6 Rats).
- **Group 12:** Ionizing Radiation (IR) + (olive oil) group, animals were irradiated with a single dose (6 Gy ) of whole-body  $\gamma$ -rays then after one hour they administered olive oil for 15 days then killed.
- **Group 13:** olive oil + IR group, animals received olive oil for 14 consecutive days, then after one hour of the last administration, animals irradiated a single dose of whole-body  $\gamma$ -rays (6 Gy) and received again olive oil in same dose for 15 days then killed.
- **Group 14:** Male rats orally injection with *Ficus carica* (single daily dose for 14 successive days) , then after one hour of the last administration, animals irradiated a single dose of whole-body  $\gamma$ -rays (6 Gy) and then killed after 24 hours. (6 Rats).
- **Group 15:** IR + (*Ficus carica*) group, animals were irradiated with a single dose (6 Gy ) of whole-body  $\gamma$ -rays then after one hour they administered *Ficus carica* for 15 days then killed.(6 Rats).
- **Group 16 :** *Ficus carica* + IR group, animals received *Ficus carica* for 14 consecutive days, then after one hour of the last administration, animals irradiated a single dose of whole-body  $\gamma$ -rays (6 Gy) and received again *Ficus carica* in same dose for 15 days (6 Rats).
- **Group 17:** Male rats orally injection with olive oil and *Ficus carica* ( single daily dose for 14 successive days) , then after one hour of the last administration, animals irradiated a single dose of whole-body  $\gamma$ -rays (6 Gy) and then killed after 24 hours. (6 Rats).
- **Group 18:** IR + (olive oil and *Ficus carica*) group, animals were irradiated with a single dose (6 Gy) of whole-body  $\gamma$ -rays then after one hour they administered olive oil and *Ficus carica* for 15 days then killed (6 Rats).
- **Group 19:** (olive oil and *Ficus carica*) + IR group; animals received olive oil and *Ficus carica* for 14 consecutive days, then after one hour of the last administration, animals irradiated a single dose of whole-body  $\gamma$ -rays (6 Gy) and received again olive oil and *Ficus carica* in same dose for 15 days (6 Rats).

### Irradiation

The radiation facility was the Canadian Gamma cell-40 ( $^{137}\text{Cs}$ ) housed at the National Center for Radiation Research and Technology (NCRRT), Cairo, Egypt. Rats of irradiated groups were exposed totally to gamma irradiation with a single acute dose (6 Gy). The dose rate at the time of the experiment was 0.45 Gy/min.

### ***Ficus carica* fruit extract**

The dried ripe fruits of *Ficus carica* (Family: Moraceae) were procured from Turkish dried fruit exporter, called Kafoods Ltd. *Ficus carica* fruit crude extract was prepared and lyophilized according to the method of **Gilani *et al.* (2008)**. The extract was prepared to supplementation by dissolving 50 g crude extract (lyophilized) in 50 ml distilled water at a concentration of 1000 mg/ml just before experimental use. This suspension was given to rats by oral gavage before and/or after radiation exposure. The selected dose of *Ficus carica* crude extract was based on the human recommended antioxidant dose of dry figs (**Vinson *et al.*, 2005**) after conversion to albino rat dose (**Reagan-Shaw *et al.*, 2007**).

### **Extra virgin olive oil**

Extra virgin olive oil was procured from The Spanish Group Pons Company with a brand of Monumental extra virgin olive oils (3 Liters). The purchased extra virgin olive oil density was 920 g/L and the selected olive oil dose was seven times that of the *Ficus carica* fruit extract (7.6 ml olive oil/kg body weight rat). The selected dose was in accordance with (**Fang *et al.*, 2008**). The extra-virgin olive oil was used for supplementation to rats by oral gavage. Every rat has received the extra virgin olive oil in a concentration of 7.6 ml/kg body weight before and/or after radiation exposure.

### ***Ficus carica* fruit extract and extra virgin olive oil**

Rats in this group received both treatments as described previously. The selective doses of both fig extract and olive oil were Qur'anic based, the ratio contained in the Qur'an (one fig: seven olives).

### **Histological study**

Liver and kidney tissues were collected from rats, washed by normal saline solution (0.9%), and then fixed in 10% formalin solution, processed, and embedded in paraffin, and sectioned for histopathological studies. The sections were stained with hematoxylin and eosin and observed under a light microscope.

### **Ultrastructure study**

Transmission electron microscopy assay; liver pieces were fixed in Karnovsky's solution

pH 7.4 for 4 h at 4°C. for overnight then washed in sodium cacodylate buffer at 4 °C, the specimens were postfixed with 1% osmium tetroxide in 0.1 M phosphate buffer (pH 7.4), dehydrated in ethanol and then embedded in Araldite resin, and semithin sections (1 µm) were removed for optical microscopy. Ultrathin sections (40-60 nm) were placed on copper mesh grids and doubly stained with uranyl acetate and lead citrate. Sections were examined using a transmission electron microscope (Morgagni 268D by the Netherlands), and photomicrographs were taken.

## **RESULTS**

### ***Histological investigation***

Plate 1 shows the control untreated rat's liver and groups treated with olive oil and/or *Ficus carica* show normal hepatic structure as the control group.

The liver tissue of the gamma-irradiated group show degeneration and atrophy of some hepatic cells, apoptotic bodies, necrotic hepatocytes, hydropic degeneration, infiltration of leukocytes and acute inflammation leads to micronodular cirrhosis in the surface of liver organ.(PLATE II A and B).

There are remarkable improvements in the microscopic appearance of the liver tissue of irradiated rats treated with *Ficus carica* fruit extract. Administrations of Ficus extract for 2weeks after radiation exposure show improvements in the liver structure of the rats such as well-developed hepatic cells with round nucleus arranged in strands , normal central vein but still some apoptotic bodies (PLATE III-A).

Administration of olive oil to the rats for 2weeks after radiation exposure show moderate improvements and some histopathological changes such as some hemorrhage, a few of endothelial lining and dilated congested central vessels (PLATE III B).

Administrations of *Ficus carica* and olive oil to the rats for 2 weeks after radiation exposure show the prominent improvements of the liver tissue and hepatocytes appeared arranged in strands (PLATE III C).

There are observable improvements and some histopathological changes in the microscopic appearance of the liver tissues of irradiated rats which protected with extra virgin olive oil and/or *Ficus carica* fruit extract. Administration of olive oil to the rats for 2 weeks before radiation exposure show moderate improvement in liver tissue and hepatocytes appeared arranged in strands. There are some infiltrations of polymorpho leukocytes and Kupffer cells were observed (PLATE IV A).

Administrations of *Ficus carica* aextract for 2 weeks before radiation exposure show moderate histopathological changes such as some hepatic strands appear abnormal and not arranged in normal shape, necrotic hepatocytes, pyknotic hepatocytes and infiltration of polymorpho leukocytes were observed (PLATE IV B).

Administrations of *Ficus carica* and olive oil to the rats for 2 weeks before radiation exposure show moderate improvements and some histopathological effect were recorded such as congested central vein but still hepatocytes appeared arranged in chords or strands(PLATE IV C).

PLATE V show the normal kidney tissue structure of the control rat group which show normal Bowman's capsule, glomeruli, and renal tubules. The rats treated with gamma radiation show severe damage of renal cells and shrinkage of the glomeruli leading to increasing of Bowman's space, abnormal renal tubules, and distortion of some tubules with desquamation of the epithelial layer of renal tubules. Also, there is degeneration of renal tubules and aggregation of melano-macrophages cells. A complete breakdown of each renal cortex tissue components and collapsed renal tubules in medullary region (PLATE VI A and B).

There are observable improvements in the microscopic appearance of the Kidney tissue of irradiated rats with extra virgin olive oil and/or *Ficus carica* fruit extract. Administration of Ficus for 2weeks after radiation exposure show moderate improvements in renal cells close to normal structure (PLATE VIIA). Administration of olive oil for 2 weeks after

radiation exposure shows relatively improvements in renal cells (PLATE VII B). Whereas the administration of *Ficus carica* and olive oil for 2 weeks after radiation exposure show improvement in renal tissue(PLATE VII C).

There are observable improvements in the microscopic appearance of the Kidney tissue of irradiated rats with extra virgin olive oil and/or *Ficus carica* fruit extract. Administration of olive oil for 2 weeks before radiation exposure show some pathological changes in renal tissuesuch as degeneration of proximal tubules(necrosis) and in epithelial wall of Bowman's capsule. Glomerulus still have normal shapes (PLATE VIIIA). Administration of *Ficus carica* for 2 weeks before radiation exposure shows relatively improvements in renal cells (PLATE VIII B). Whereas the administration of *Ficus carica* and olive oil for 2 weeks before radiation exposure show some histopathological changes such as shrunked distal tubules and degeneration of proximal tubules (PLATE VIII C).

#### **Cytological investigation:**

The ultra-structural examinations of the control rat group manifest normal hepatocyte structure with a normal nucleus, normal distribution of chromatin, and prominent nucleolus. The cytoplasm of hepatocytes is rich in healthy pleomorphic mitochondria appeared with double walled membrane and intact cristae (plate IX A).

In the case of irradiated rats the ultra-structure of the hepatic cells show irregular nucleus envelop with dispersed chromatin. The cytoplasm of hepatocytes show abnormally shaped mitochondria and dilated fragmented rough endoplasmic reticulum (plate IX B).

Administrations of Ficus and olive oil to the rats for 2 weeks before and after radiation exposure of rats show relatively normal shaped mitochondria in other field and multiple large peroxysomes (plate IX C). In addition, Ficus and olive oil administrations to the rats for 2weeks after radiation exposure show normal shaped euchromatic nucleus with more or less vacuoles in the cytoplasm, few collagen fibers

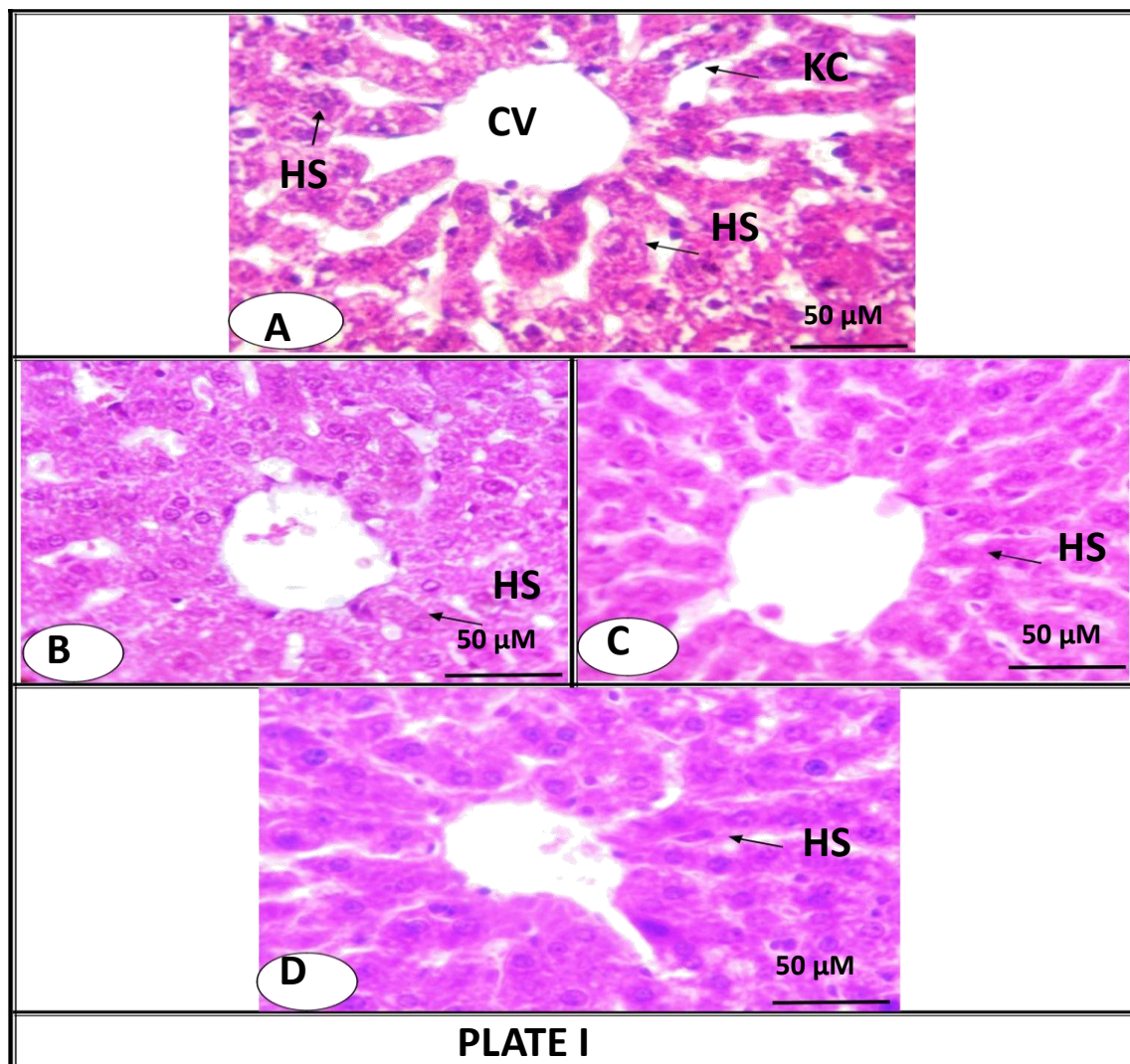
and normally shaped mitochondria (plate IX D).

*Ficus carica* extracts administration to the rats for 2 weeks after ionizing radiation exposure show the improvements in cell organells and with some large fat droplets in hepatocytes and phagolysosomes in other fields (plate X A).

On the other hand, administration of *Ficus carica* to the rats for 2 weeks before ionizing radiation exposure show normal euchromatic

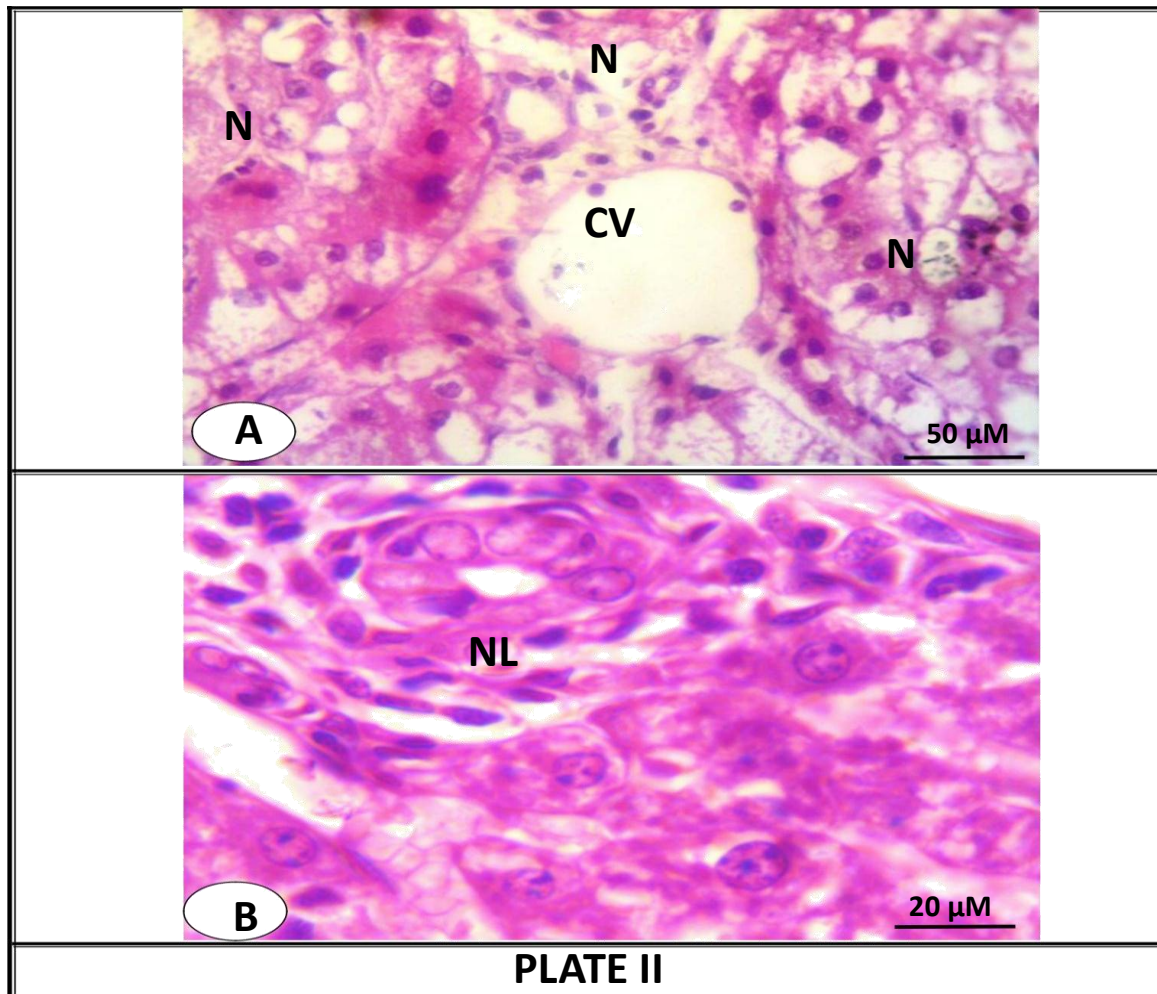
nuclei with prominent nucleoli and the cytoplasm show well developed rough endoplasmic reticulum and normal mitochondria with electron dense matrix (plate X B).

Administration of *Ficus carica* to the rats for 2 weeks before and after ionizing radiation exposure show normal hepatocytes with prominent nuclei well developed rough endoplasmic reticulum and mitochondria (plate X C).

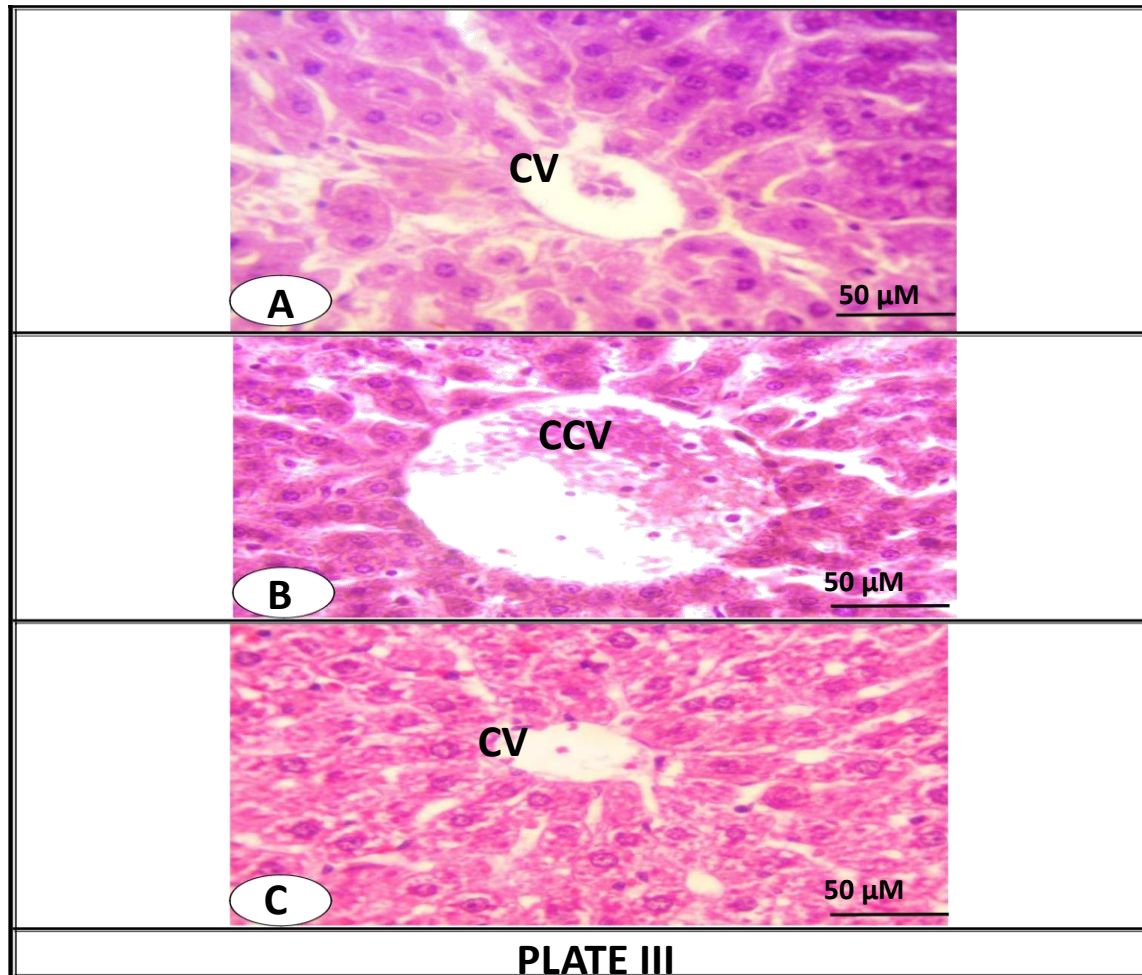


**PLATE I:** Photomicrographs of A: normal liver structure of adult albino rat, B: liver section of the group treated with olive oil for 2 weeks, C: liver section of the group treated with *Ficus* for 2 weeks, D: liver of the group treated with olive oil and *Ficus* for 2 weeks (HC, hepatic polygonal cells; HS, hepatic strands; CV, Central vein; KC, kupffer cells; Bar= 50  $\mu$ M ).



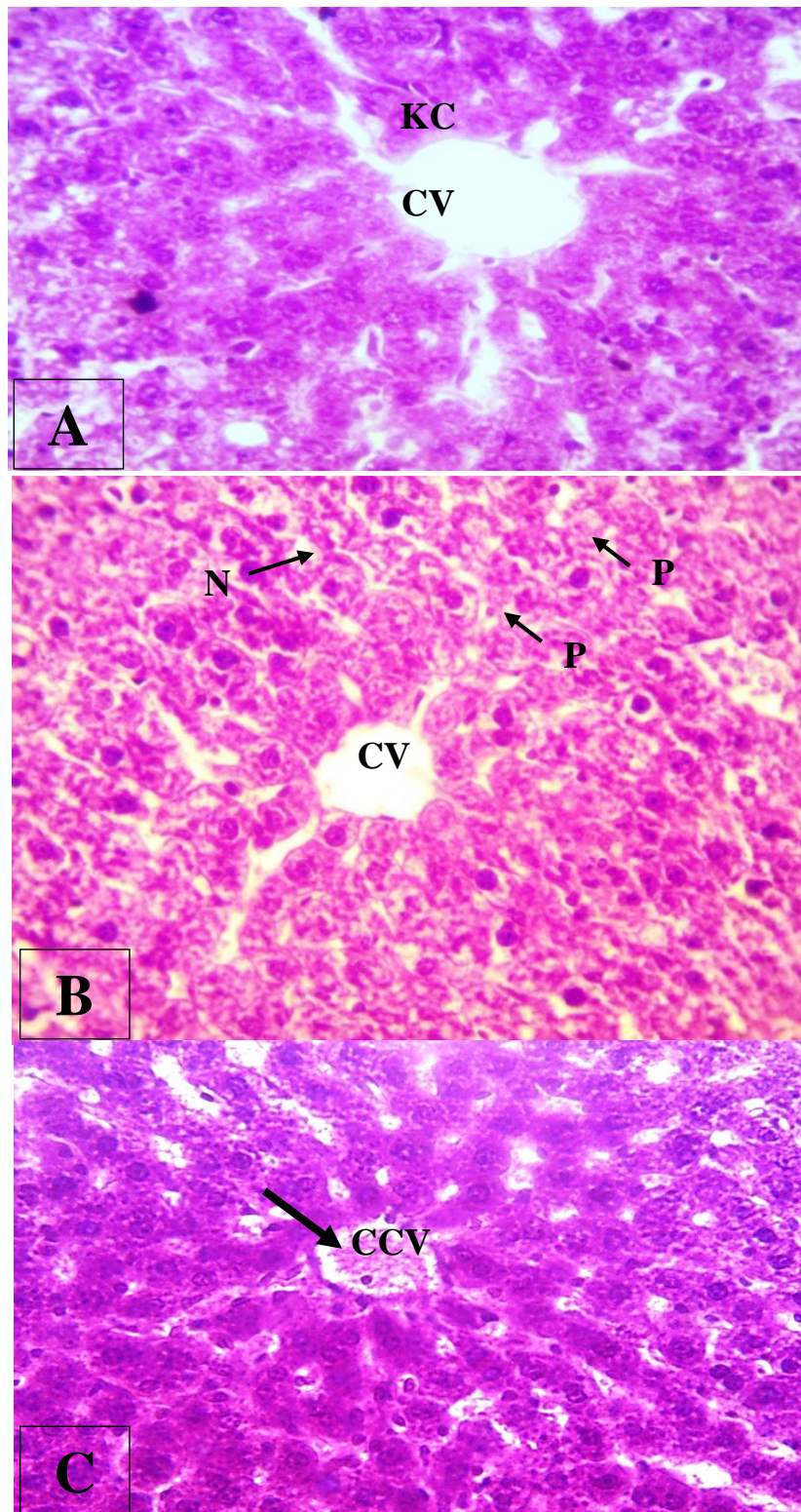


**PLATE II:** photomicrographs of liver sections of the irradiated group after 24 hours showing the degenerative changes in the liver, A and B (N, necrotic hepatocyte; L, Leukocyte; CV, Central vein; Bar= 50 μM in A, Bar= 20in B).



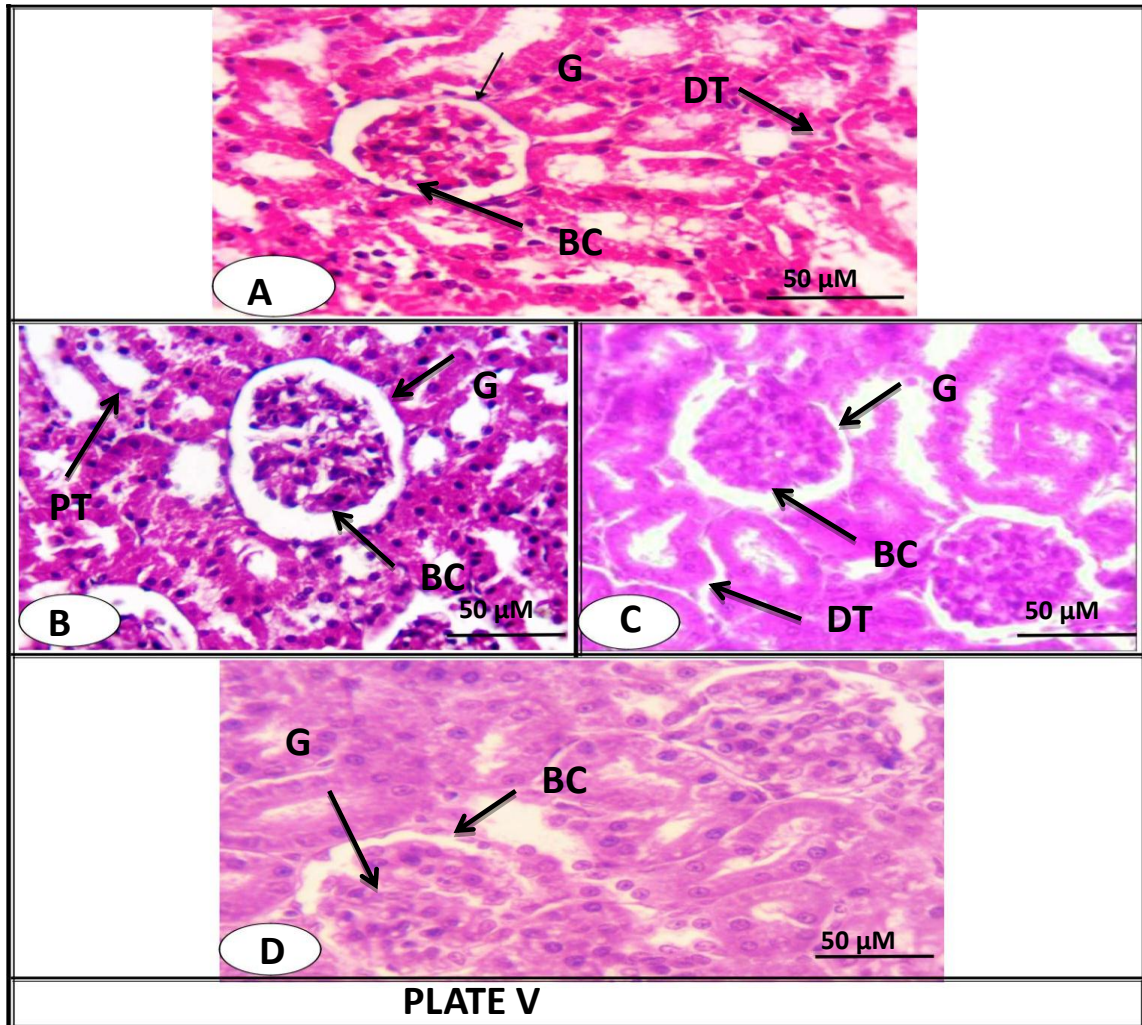
**PLATE III:** Photomicrographs of liversections after 2 weeks of irradiation, A: liver of the group treated with *Ficus*, B; liver of the group treated with olive oil, C: liver of the group treated with *Ficus* and olive oil (CV, Central vein; CBV, congested Central vein; Bar= 50  $\mu$ M;).





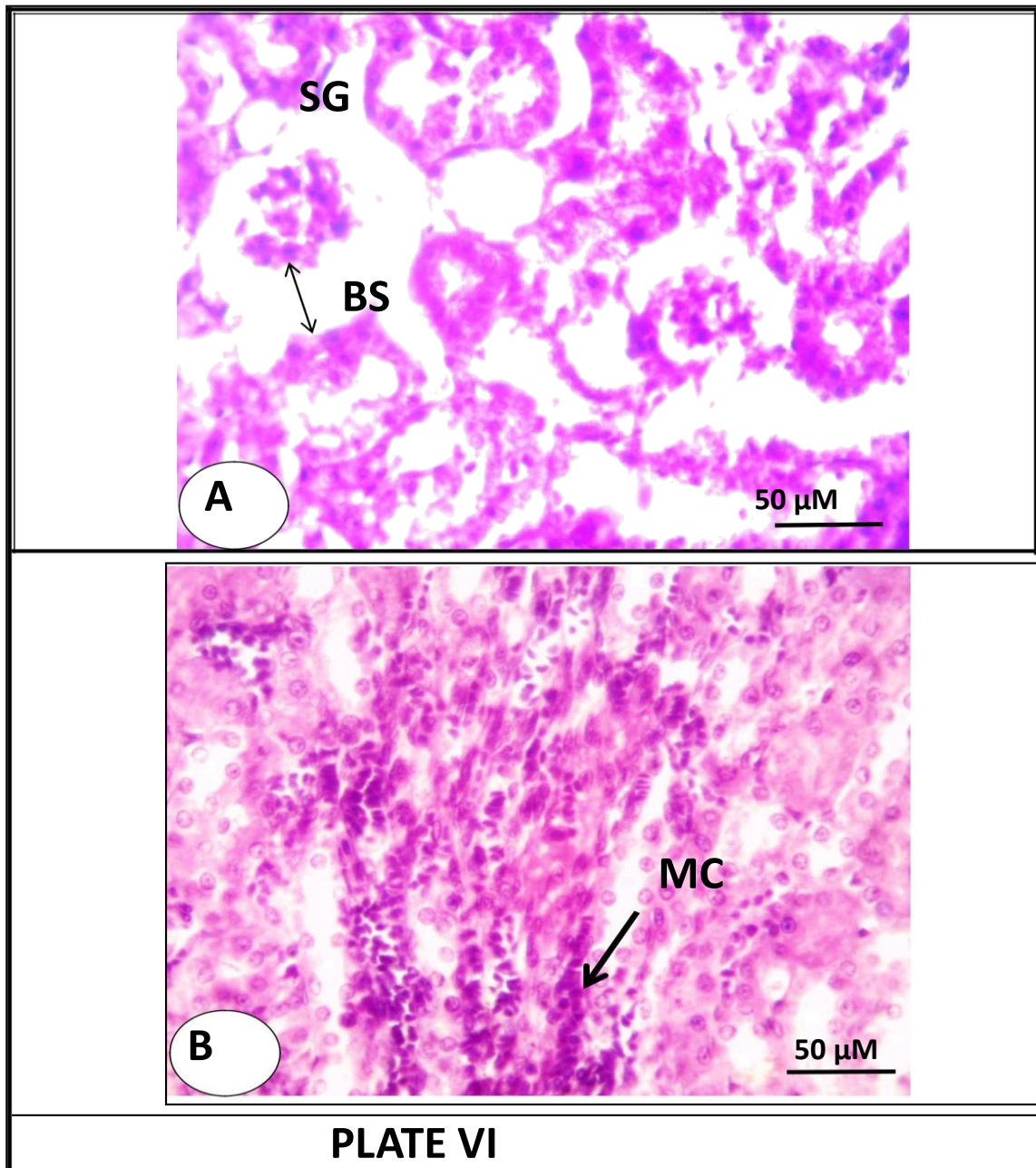
#### PLATE IV

**PLATE IV:** Photomicrographs of livers before 2 weeks of irradiation, A: liver of the group treated with olive oil, B: liver of the group treated with *Ficus carica*, C: liver of the group treated with Ficus and olive oil (CV, Central vein; P, Pyknosis; N, Necrosis; KC, Kupffer cell; CCV, congested Central vein; Bar= 50  $\mu$ M).

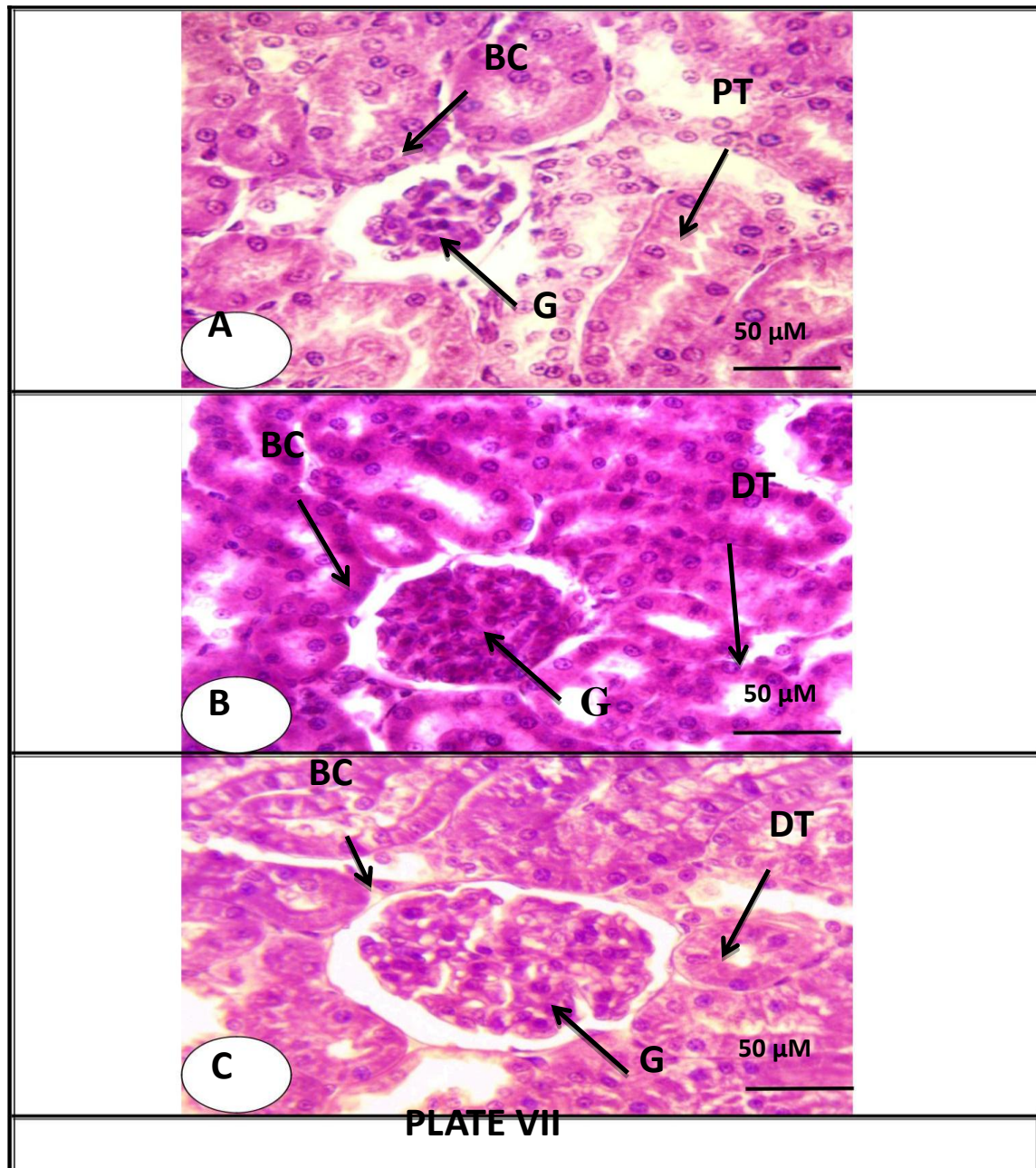


**PLATE V:** Photomicrographs of A: normal kidney structure in adult albino rat, B: kidney of the group treated with olive oil for 2 weeks, C: kidney of the group treated with *Ficus* for 2 weeks, D: kidney of the group treated with olive oil and *Ficus* for 2 weeks (BC, Bowman's capsule; G, glomeruli; PT, proximal tubules; Bar= 50  $\mu$ M).



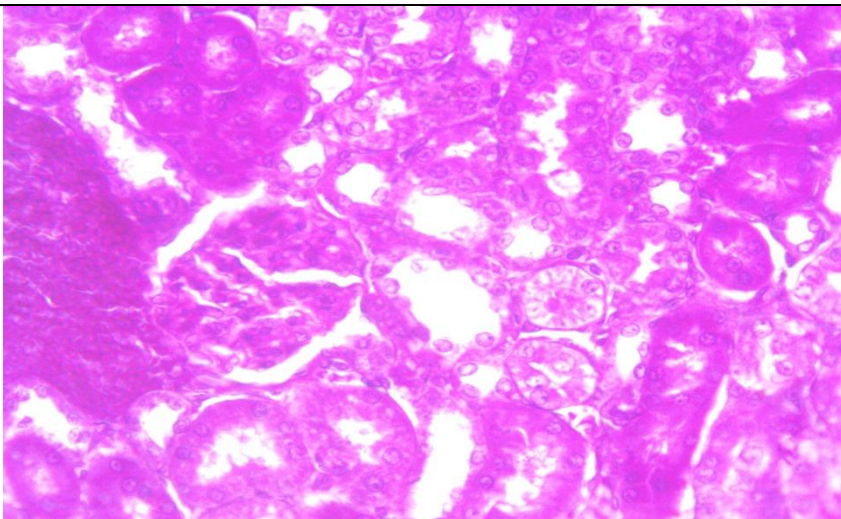
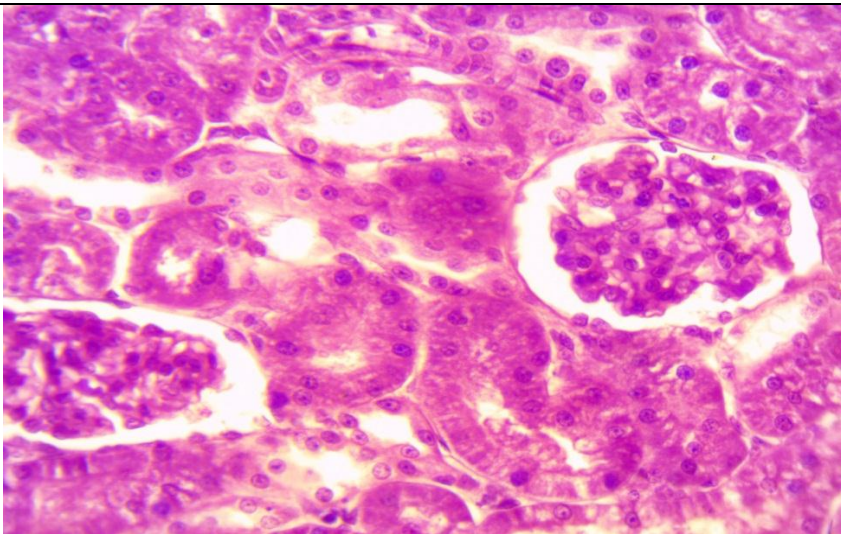
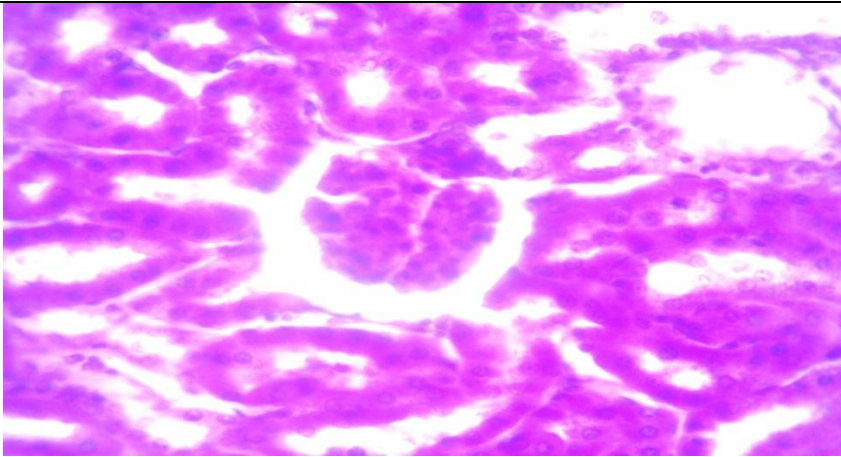


**PLATE VI:** Photomicrographs of the kidney of the irradiated group after 24 hours, A and B (SG, shrinkage of glomerulus; BS, Bowman's space; MC, Melano-macrophages cells; Bar= 50 μM in A, Bar= 20 μM in B).



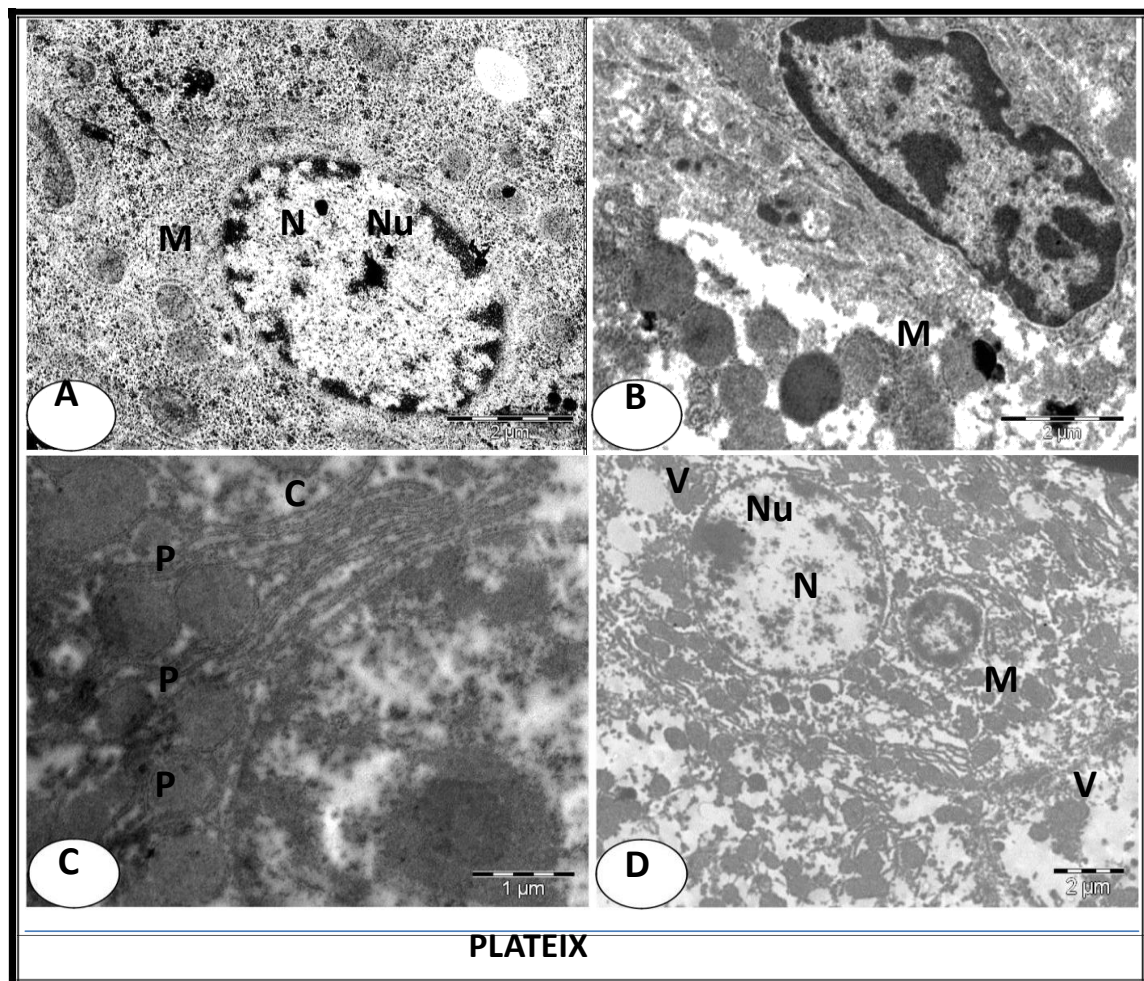
**PLATE VII:** Photomicrographs of kidney after 2 weeks of irradiation, A: kidney of the group treated with *Ficus*, B; kidney of the group treated with olive oil, C: kidney of the group treated with *Ficus* and olive oil (BC, Bowman's capsule; G, glomeruli; PT, proximal tubules; Bar= 50  $\mu$ M).






### PLATE VIII

**PLATE VIII:** Show photomicrographs of kidney before 2 weeks of irradiation, A: kidney of the group treated with olive oil, B; kidney of the group treated with *Ficus scarica*, C: kidney of the group treated with *Ficus* and olive oil (BC, Bowman's capsule; G, glomeruli; PT, proximal tubules; DT, distal convoluted tubules; Bar= 50  $\mu$ M).



**PLATE IX:** Electron micrographs of A: normal hepatocyte structure in adult albino rat, B: liver cell of the irradiated group after 24 hours, C: liver cell of the group treated with olive oil and *Ficus* for 2 weeks then irradiated then treated with olive oil and *Ficus* for 2 weeks, D: liver cell of the group exposed to radiation then treated with olive oil and *Ficus* for 2 weeks. (N, Normal nucleus; Nu, prominent nucleolus; M, pleomorphic mitochondria; C, cristae ; P, Peroxisomes or Microbodies; TEM, Scale = 2 $\mu$ M in A,B and D; 1 $\mu$ M in C).





**PLATE X:** Electron micrographs of A: Hepatocyte of rat exposed to radiation then treated with *Ficuscarica* for 2weeks., B: liver cell of the group treated with *Ficuscarica* for 2 weeks then exposed to ionizing radiation , C: liver of the group treated with *Ficuscarica* for 2weeks then irradiated then treated with *Ficuscarica* for 2weeks, (N, Normal nucleus; Nu, prominent nucleolus;M, pleomorphic mitochondria; L, Fattydroplet; RER, Rough endoplasmic reticulum; TEM, Scale = 2μM).

## DISCUSSION

The exposure to ionizing radiation is known to induce oxidative stress through the generation of reactive oxygen species (ROS) resulting in an imbalance of the pro-oxidant and antioxidant activities ultimately resulting in cell death (Srinivasan et al., 2006). ROS and oxidative stress may contribute to radiation-induced cytotoxicity and to metabolic and morphological changes in animals and humans during radiotherapy (Fang et al., 2002).

The evidence is combine to demonstrate that extra virgin olive oil is remarkably rich in effective phenolic antioxidants that could provide protection by inhibiting oxidative damage (Owen et al., 2000; Visioli and Galli, 2002; Rubio et al., 2014). According to Tuck and Hayball (2002), olive oil is a source of at least 30 phenolic compounds. The phenolic compounds present in virgin olive oils are strong antioxidants and radical scavengers. Olive and extra virgin olive oils contain a considerable amount of oleuropein, hydroxytyrosol, and tyrosol, which all have potent inhibiting effects against ROS (Owen et al., 2000). In addition, Tuck et al. (2002) have shown that hydroxytyrosol is the major phenolic antioxidant in the olive oil; It is highly effective against DNA damage (Deiana et al., 1999).

The *Ficus carica* results in the present study are in accordance with Solomon et al. (2010) who attribute the antioxidant effect of the fresh figs to a very effective antioxidant component called Cyanidin-3-rhamnoglucoside (C3R) identified to inhibit lipid peroxidation and reduced the oxidative stress.

Both *Ficus carica* and extra virgin olive oil are rich in polyphenolics substances; polyphenolics have received widespread attention because of their potential for preventing some highly prevalent chronic diseases. In fact, it has been reported that polyphenols are endowed with interesting biological activities such as anti-inflammatory, antioxidant, antidiabetic, and hepatoprotective activities (Obied et al., 2005). Inconsistent with the present results, hydroxytyrosol of

*Ficus carica* and extra virgin olive oil reported being an effective scavenger. This antioxidant activity protects cells from damage and death (Nivitabishekam et al., 2009).

Most of the hepatoprotective drugs are belonging to the group of the free radical scavenger, their mechanisms of action involving membrane stabilization, neutralization of free radicals and immunomodulation (Azab and Nada, 2004). In the present work, the possible mechanism of the anti-hepatotoxic effect of *Ficus carica* extract and olive oil may be attributed to its antioxidant activity.

The results of the present study revealed that the fig extract and olive oil have a strong antioxidant effect, and since they contained high amounts of phenolic compounds, they have been reported as free radical scavengers and have a therapeutic effect against cancer, tissue inflammation and cardiovascular diseases (Cai and Cherian, 2003).

The free radical toxicity in the present study counteracted by the extra virgin olive oil, *Ficus carica* fruit extract and the combined supplementation of both, which had a better amelioration. Treatment with both fig and olive oil revealed the presence of numerous and varied antioxidant agents. The diverse natural antioxidants act synergistically with each other to produce a broad spectrum of antioxidative activities that create an effective defense system against free radical attack (Viola and Viola, 2009). Moreover, the polyphenols present in the plants may up-regulate mRNAs of antioxidant enzymes such as catalase, glutathione, superoxide dismutase and thus, may counteract the oxidative stress-induced by ionizing radiations. Reduction in lipid peroxidation and protein oxidation may also contribute, to some extent, to their radioprotective activity. The plants may also inhibit activation of protein kinase C (PKC), mitogen-activated protein kinase (MAPK), cytochrome P-450, nitric oxide and several other genes that may be responsible for inducing damage after irradiation (Jageti, 2007).

The antioxidant effect of both fig and olive oil is mainly due to phenolic compounds, which are able to donate a hydrogen atom to the free radicals, thus stopping the propagation chain reaction during the lipid peroxidation process (Sanchez-Mareno et al., 1998; Yanishlieva and Marinova, 1998).

Groups treated with *Ficus carica* and/or olive oil showed no pathological effect in liver or kidney sections which indicate their safety in the treated doses. These results are in line with those of Singabet al. (2010) who found that methanol extracts of *Ficus carica* showed potent antioxidant and hepatoprotective activities in liver sections of male rats. On the other hand, the irradiated groups show severe toxicity and many pathological features in liver sections such as degeneration and atrophy of some hepatic cells, apoptotic bodies, necrotic hepatocytes and hydropic degeneration. The present work showed rat kidney sections of irradiated groups show severe damage of renal cells and shrinkage of the glomeruli leading to increasing of Bowman's space, and abnormal renal tubules.

Previous studies showed that ethanolic olive leaves extract ameliorated the induced kidney tissue damage of the irradiated kidney of male rats (Abdelhafez et al., 2017).

The present results are in line with those of Cheng et al. (2014) who found fibrosis proliferation in the liver tissue observed for 2 weeks after irradiation. Numerous apoptotic cells were also observed in the liver tissue 4 weeks after irradiation.

Rat groups treated with *Ficus carica* and/or olive oil before and after radiation show moderate improvements or slightly pathological effects in hepatocyte and renal tissue sections which indicate their ability to ameliorate the irradiation toxic effects.

Fathy et al. (2018) agreed with these results when they found that the administration of extra virgin olive oil with fig and date palm extract to irradiated rats ameliorated the oxidative stress markers and serum liver function parameters revealing a synergistic effect of the combination between them.

Previous studies also showed that olive leaf extract has lung tissue radiotherapeutic effects against whole body gamma radiation in male albino rats (Abd El-Hady and AlJaloud, 2015).

Ultra-structural examinations of control group and groups treated with *Ficus carica* and/or olive oil show no cytological effect in the liver ultra-section which indicate their safety in the treated doses. On the other hand, in the case of irradiated rats the ultra-structural of the hepatic cells, showing severe damage of cell organelles.

Groups treated with *Ficus carica* and/or olive oil or the combined supplementation before and after radiation show moderate improvements or no cytological effect in the liver ultra-section which indicate their ability to ameliorate the toxic effects which induced by radiation.

Mansour et al. (2014) agreed with these results when they found that ultra-structure of hepatocytes of irradiated rats showed cytopathological changes referred to irregular outlines shaped nucleus with large center nucleolus, there was fragmented cisternae of rough endoplasmic reticulum. Mitochondria were swollen, lost their cristae.

In agreement with the present study, other investigation showed that irradiated mice liver shows highly damage in hepatocyte with lysis of cytoplasm, fragmented endoplasmic reticulum, dilated blood sinusoids with thickened membrane showing degeneration nuclear chromatin and electron dense mitochondria. Electron micrograph of mice liver cell treated with olive oil for 7 days showed normal liver appearance (Mansour et al., 2011).

The present results revealed that olive oil and *Ficus carica* have a protective effect against Ionizing radiation which induced hepatotoxicity and nephrotoxicity through its free radical scavenging activity and enhancement of the antioxidant defense mechanisms.

In conclusion, according to the results obtained the administration of the olive oil

and/or *Ficus carica* provides considerable protective and therapeutic roles against radiation toxicity as revealed by the cytological and histological techniques. A preferable ameliorative effect was noticed with the combined olive oil and *Ficus carica* treatments in the therapeutic groups that revealed a synergistic effect of the combination between them to produce a broad spectrum of antioxidative activities. In protective groups we found that *Ficus carica* made an improvement in histological structure of kidney tissues more than Olive oil groups.

## REFERENCE

- Abd El-Hady, A. M. and AlJaloud, N. A. (2015): Therapeutic Effects of Olive Leaf Extract or Bone Marrow Mesenchymal Stem Cells against Lung Damage Induced In Male Albino Rats Exposed To Gamma Radiation. *The Egyptian Journal of Hospital Medicine*, 61: 685- 699.
- Abdel Nasser B. Singab, Nahla A. Ayoub, Eman N. Ali and Nada M. Mostafa (2010): Antioxidant and hepatoprotective activities of Egyptian moraceous plants against carbon tetrachloride-induced oxidative stress and liver damage in rats, *Pharmaceutical Biology*, 48:11, 1255-1264.
- Abdelhafez H. M., Al-Tounsy, M. M. and Omran, D. A. (2017): The possible therapeutic effect of ethanolic olive leaves extract or bone marrow mesenchymal stem cells on the kidney of gamma-irradiated adult male rats. *Stem Cell*, 8(1): 60-81.
- Azab K. and Nada A. (2004): Restitution of energy metabolism in irradiated rats considering curcumin antioxidant capacity and metal biotransformation. *Arab J. Nucl. Sci. Appl.* 37(2): 169-176.
- Baatout S.; Jacquet P.; Derradji H.; Ooms D.; Michaux A. and Mergeay M. (2004): Study of the combined effect of x-irradiation and epigallocatechingallat (a tea component) on the growth inhibition and induction of apoptosis in human cancer cell lines. *Oncol. Rep.*, 12(1): 159-167.
- Cai L. and Cherian M. G. (2003): Zinc-metallothionein protects from DNA damage induced by radiation better than glutathione and copper- or cadmium-metallothionein. *Toxicol.Lett.*, 136(3): 193-198.
- Cheng, W., Xiao, L., Ainiwaer, A., WANG, Y., Wu, G., Mao, R., Yang, Y., and Bao, Y. (2014). Molecular responses of radiation-induced liver damage in rats. *Molecular Medicine Reports.*, 11: 2592-2600.
- Deiana M.; Aruoma O. I.; Bianchi M. L. P.; Spencer J. P.; Kaur H.; Halliwell B.; Aeschbach R.; Banni S.; Dessi M. A. and Corongiu F. P. (1999): Inhibition of peroxynitrite-dependent DNA base modification and tyrosine nitration by the extra virgin olive oil-derived antioxidant hydroxytyrosol. *Free Radical Biology and Medicine*, 26: 762-769.
- El Habit O. H. M.; Saada H. N.; Azab K. S.; Abdel Rahman M. and El Malah D. F. (2000): The modifying effect of  $\beta$ -carotene on gamma radiation-induced elevation of oxidative reactions and genotoxicity in male rats. *Mutation Research*, 466: 179-186.
- Fang H.-L.; Lai J.-T. and Lin W.-C. (2008): Inhibitory effect of olive oil on fibrosis induced by carbon tetrachloride in rat liver. *Clinical Nutrition*, 27: 900-907.
- Fang Y.; Yang S. and Wu G. (2002): Free radicals, antioxidants, and nutrition. *Nutrition*, 18: 879-887.
- Fathy, A. H. , Bashandy, M.A., Bashandy, S.A., Mansour, A.M. and Azab, K.S., (2018): The beneficial effect of natural antioxidants from olive oil with fig and date palm fruit extracts on biochemical and hematological parameters in rats treated with doxorubicin and  $\gamma$ -radiation. *FACETS*, 3: 722–735.
- Gilani A. H.; Malik H. M.; Khalid H. J.; Arifullah K. and Sheikh A. S. (2008): Ethnopharmacological studies on antispasmodic and antiplatelet activities of *Ficus carica*. *Journal of Ethnopharmacology*, 119: 1-5.
- Institute of Laboratory Animal Resources( 1996): Guide for the care and use of laboratory animals. 8<sup>th</sup> edition. Committee for the update of the guide and use of laboratory animals. National Research Council of the National Academies, National Academy Press, Washington, D.C.
- Jagetia G. C. (2007): the Radioprotective potential of plants and herbs against the effects of ionizing radiation. *J. Clin. Biochem.Nutr.*, 40: 74-81.
- Kamiloglu S.; Pasli A. A.; Ozcelik B. and Capanoglu E. (2014): Evaluating the in vitro bioaccessibility of phenolics and antioxidant activity during consumption of dried fruits with nuts. *Food Science and Technology*, 56: 284-289.
- Karbowink M. and Reiter R. J. (2000): Antioxidative effects of melatonin in protection against cellular damage caused by ionizing radiation. *Proc. Soc. Exp. Biol. Med.*, 225(1): 9-22.
- Lemos M. R. B.; Siqueira E. M. D. A.; Arruda S. F. and Zambiasi R. C. (2012): The effect of

- roasting on the phenolic compounds and antioxidant potential of Baru nuts. *Food Research International*, 48: 592-597.
- Maith A.; Mckenna W. G. and Muschel R. J. (1999): The molecular basis for cell cycle delays following ionizing radiation. *Radiother.Oncol.*, 31: 1-13.
- Mansour H. H.; Abd El Azeem M.G.A.; Ismael N.E. (2011): Role of lycopene against hepatorenal oxidative stress induced by sodium fluoride and gamma rays. *Journal of Radiation Research and Applied Sciences*, 4 :435-460
- Mansour H.H; El Azeem; M.G.A; Ismael N.E.(2014): Protective Effect of *Moringaoleifera* on  $\gamma$ -Radiation-Induced Hepatotoxicity and Nephrotoxicity in Rats. *American Journal of Phytomedicine and Clinical Therapeutics*, 2: 495-508.
- Nivitabishekam S. N.; Asad M. and Prasad V. S. (2009): Pharmacodynamic interaction of *Momordicacharantia* with rosiglitazone in rats. *Chem. Biol. Interact.*, 177: 247-253.
- Obied H. K.; Allen M. S.; Bedgood D. R.; Prenzler P. D.; Robards K.; Stockmann R. and Agric J. (2005): Bioactivity and analysis of biophenols recovered from olive mill waste. *Food Chem. Toxicol.*, 53: 823-837.
- Owen R.; Mier W. and Giacosa A. (2000): Phenolic compounds and squalene in olive oils: the concentration and antioxidant potential of total phenols, simple phenols, secoiridoids, lignans, and squalene. *Food Chem. Toxicol.*, 38: 647-659.
- Reagan-Shaw S.; Minakshi N. and Ahmad N. (2007): Dose translation from animal to human studies revisited. *The FASEB Journal*, 22: 659-661.
- Rubió L.; Macià A.; Castell-Auví A.; Pinent M.; Blay T.; Ardévol A.; Romero M.-P. and Motilva M.-J. (2014): Effect of the co-occurring olive oil and thyme extracts on the phenolic bioaccessibility and bioavailability assessed by in vitro digestion and cell models. *Food Chemistry*, 149: 277-284.
- Saada H. N. and Azab K. S. (2001): Role of lycopene in the recovery of radiation-induced injury to mammalian cellular organelles. *J. Pharmazie*, 56(3): 239.
- Sanchez-Mareno C.; Larrauri J. A. and Saura-Calixto F. (1998): A procedure to measure the antiradical efficiency of polyphenols. *J. Sci. Food. Agric.*, 76(2): 270-276.
- Singab A. B.; Ayoub N. A. and Ali E. N. and Mostafa N. M. (2010): Antioxidant and hepatoprotective activities of Egyptian moraceous plants against carbon tetrachloride-induced oxidative stress and liver damage in rats. *Pharmaceutical Biology*, 48: 1255-1264.
- Solomon A.; Golubowicz S.; Yablowicz Z.; Bergman M.; Grossman S.; Altman A.; Kerem Z. and Flaishman M. A. (2010): Protection of fibroblasts (NIH-3T3) against oxidative damage by cyanidin-3-rhamnoglucoside isolated from fig fruits (*Ficus carica* L.). *J. Agric. Food Chem.*, 58(11): 6660-6665.
- Solomon A.; Golubowicz S.; Yablowicz Z.; Grossman S.; Bergman M.; Gottlieb H. E.; Altman A.; Kerem Z. and Flaishman M. A. (2006): Antioxidant activities and anthocyanin content of fresh fruits of common fig (*Ficus carica* L.). *J. Agric. Food Chem.*, 54(20): 7717-7723.
- Srinivasan M.; Sudheer A. R.; Pillai K. R.; Kumar P. R.; Sudhakaran P. R. and Menon V. P. (2006): Influence of ferulic acid on gamma radiation-induced DNA damage, lipid peroxidation and antioxidant status in primary culture of isolated rat hepatocytes. *Toxicology*, 228(2-3): 249-258.
- Tuck K. L. and Hayball P. J. (2002): Major phenolic compounds in olive oil: metabolism and health effects. *Journal of Nutrition and Biochemistry*, 13: 636-644.
- Tuck K. L.; Hayball P. J. and Stupans I. (2002): Structural characterization of the metabolites of hydroxytyrosol, the principal phenolic component in olive oil, in rats. *Journal of Agricultural and Food Chemistry*, 50: 2402-2409.
- Turrens J. F. (2003): Mitochondrial formation of reactive oxygen species. *J. Physiol.*, 552: 335-344.
- Vinson J. A.; Zubik L.; Bose P.; Samman N. and Proch J. (2005): Dried fruits: excellent in vitro and in vivo antioxidants. *Journal of the American College of Nutrition*, 24: 44-50.
- Viola P. and Viola M. (2009): Virgin olive oil as a fundamental nutritional component and skin protector. *Clinics in Dermatology*, 27: 159-165.
- Visioli F.; Poli A. and Galli C. (2002): Antioxidant and other biological activities of phenols from olives and olive oil. *Medicinal Research Reviews*, 22: 65-75.
- Yanishlieva N. V. and Marinova E. M. (1998): Activity and mechanism of action and of natural antioxidant in lipids. *Recent. Res. Develop. In*

الآثار الوقائية والعلاجية لزيت الزيتون و مستخلص ثمار التين البرشومي على بعض القياسات  
الهستولوجيه والخلويه في كلى وكبد ذكور الجرذان البيضاء المشععة بأشعة جاما

احمد عبدالعزيز جعفر ، ، محمودامين خليفه، 'فتحي الشاعر

'قسم علم الحيوان- كلية العلوم (بنين) - جامعة الأزهر

### الملخص العربي

تهدف هذه الدراسة الي تقييم تأثير زيت الزيتون البكر و مستخلص ثمار التين البرشومي كل على حده أو كليهما معاً كمضادات للأكسدة للوقاية و العلاج و الحد من الآثار الضارة للأشعة المؤينة علي كبد وكلي ذكور الجرذان البيضاء بعد التشعيع الكلي بواسطة أشعة جاما (جرعة كلية ٦ جرای جرعة واحدة). ولقد تمت هذه الدراسة بإستخدام ١١٤ جرذاً ذكراً يتراوح وزن الجرذ من ١٢٠±٥ جرام حيث تم تقسيم الجرذان الي ثمانية مجموعات رئيسية وتسع عشرة مجموعة فرعية. تم تجريع زيت الزيتون البكر (٧,٦ مل/كيلو جرام من جسم الجرذان) و مستخلص ثمار التين البرشومي (جرام/كيلو جرام من جسم الجرذان) عن طريق الفم مره يوميا لمدة أسبوعين للمجموعات الوقائية (قبل الاشعاع) أو العلاجيه (بعدا لاشعاع) و لمدة ٤ أسابيع للمجموعات الوقائية والعلاجية معا.

أظهرت النتائج ما يلي: تعرض الجسم الكلي لذكور الجرذان البيضاء لأشعة جاما(٦ جرای) يؤدي إلى موت و تلف خلايا الكبد والكلى .

و قد أظهرت الدراسة ان معالجة الجرذان المشععة بزيت الزيتون البكر و مستخلص ثمار التين البرشومي منفردين او مجتمعين معأقبل الاشعاع وبعده يؤدي الي تحسن في جميع القياسات الهستولوجيه والخلويه بالمقارنة مع الجرذان المشععة غيرأن معالجة الجرذان المشععة بزيت الزيتون البكر و مستخلص ثمار التين البرشومي معاً قد أدي الي أفضل النتائج.

كماً أن معالجة الجرذان بمستخلص ثمار التين البرشومي قبل الاشعاع حقق تحسنا في التركيب النسيجي لأنسجة الكلى أكثر من معالجتها بزيت الزيتون.

توصي هذه الدراسة بإمكانية استخدام زيت الزيتون البكر و مستخلص ثمار التين البرشومي معاً كحماية و علاج للخلايا من التدمير الخلوي، و أيضاً كمواد واقية من بعض أضرار التعرض للإشعاع الجامي، لما لهم من قدرة علي إصطياد الشوارد الحرة الناتجة من تعرض الخلايا الي أشعة جاما مما يؤدي الي الحد من تأثيراتها الضارة المدمرة للجسم. ومع ذلك، هناك حاجة ملحة لإجراء المزيد من الدراسات لتوضيح آلية عمل هذه المواد في التأثير الوقائي و العلاجي من الإشعاع.