



Protective Efficiency of *Pterocarpus erinaceus* Leaves Extract in Carbon-tetrachloride-induced Hepatic and Hematological Injuries in Rats

Usman Mohammed^{a,b}, Abdulrashid Mohammed^a,
Daniel Hassan Mhya^{a*}, Simon Mafulul Gabriel^b
and Daniel Dahiru^c

^a Department of Medical Biochemistry, Faculty of Basic Medical Sciences, Abubakar Tafawa Balewa University, Bauchi, PMB 0248, Bauchi State, Nigeria.

^b Department of Biochemistry, Faculty of Basic Medical Sciences, University of Jos, PMB-2084, Plateau State, Nigeria.

^c Department of Biochemistry, Faculty of Sciences, Modibbo Adama University Yola, PMB-2076, Adamawa State, Nigeria.

Authors' contributions

This work was carried out in collaboration among all authors. Author UM got the concept, design the study and carried out the laboratory work, Authors SMG and DD critically reviewed and edited the draft study concept and design for important intellectual content. Author AM managed the literature search and participated in data validation, and subsequent revision of the final version of manuscript. Author DHM drafted the manuscript. All authors read and approved the final manuscript.

Article Information

DOI: 10.9734/JALSI/2023/v26i3606

Open Peer Review History:

This journal follows the Advanced Open Peer Review policy. Identity of the Reviewers, Editor(s) and additional Reviewers, peer review comments, different versions of the manuscript, comments of the editors, etc are available here: <https://www.sdiarticle5.com/review-history/101279>

Original Research Article

Received: 10/04/2023
Accepted: 12/06/2023
Published: 27/06/2023

ABSTRACT

Aims: Chemical toxicity is one of the major leading causes of tissues injuries, which impair the tissue's ability to maintain normal physiological functions. *Pterocarpus erinaceus* is a medicinal plant use as traditional remedy for the treatment of several disorders associated with tissues

*Corresponding author: E-mail: dmhassan@atbu.edu.ng, dmhyas@gmail.com;

injuries. This study therefore aimed at investigating tissues protective efficiency of *Pterocarpus erinaceus* leaves extract in carbon-tetrachloride-induced hepatic and hematological injuries in rats.

Materials and Methods: Leaves of *Pterocarpus erinaceus* after collection were air-dried and pulverized. It was extracted with methanol and the methanolic extracts were used. Acute toxicity and hepatoprotective studies against CCl₄ toxicity were conducted. Rats were grouped into; Group 1: Normal control (liquid paraffin, vehicle 1ml/kg), Group 2: Negative control (received 1ml/kg CCl₄), Group 3: Positive control (received 1ml/kg CCl₄ +100ml/kg Silymarin), Group 4-6: Extract treated rats (received 1ml/kg CCl₄ + varied doses of Extracts at 100, 200, and 400mg/kg body weight of rats). The treatment was done daily via oral means for 14 days.

Results: The results of the acute toxicity study showed *Pterocarpus erinaceus* extract safe with LD₅₀ greater than 5000mg/kg body weight. This study reveals *Pterocarpus erinaceus* able to ameliorate CCl₄ toxicity by minimizing damage to hepatic and hematological tissues. Histological study of the rats' hepatic cells further unveils the protective ability of the plant extract against severity of CCl₄-mediate hepatic architectural damage.

Conclusion: *Pterocarpus erinaceus* leaves possess components with tissue-protective properties hence the need to harness it for utilization.

Keywords: Animal-study; CCl₄-toxicity; tissues; protection; plant-extract.

1. INTRODUCTION

Jorum and Piero [1] stated that blood can act as a pathological and physiological indicator of animal health. Following absorption, substances (toxic chemical for instance) are carried by the blood to various organs, where they may exert harmful effects. High reactive metabolites produced by toxic chemicals can alter the hematological system of organisms and lower the ability of blood to maintain homeostasis. Change of hematological components from normal levels represents the presence of toxicity or disease [2]

The existence of healthy tissue is based on the protection versus injury induced as a result of chemical toxicity [3]. The liver is termed the most crucial organ that exhibits the vital role in safeguarding several physiological processes in the body. It is involved in several imperative functions, as metabolism, excretion, and storage. Liver provides a basic function in the detoxification of endogenous and exogenous intermediaries. Consequently, liver injuries are accompanied by crucial implications for the health of the affected person [4]. Liver injuries that are associated with toxic metabolites has been a major research focus by many scientific studies [5,6].

Liver injury due to chemical toxicity is responsible for about 5% of all hospital admissions and 50% of all acute liver failures [7]. Despite the growth in the production of agents with efficacies to reverse the damage induced on the liver, hepatic injuries still remain a global challenge with a

serious concern by the health system. In this regard, exploration of more alternative therapeutic medicine without severe side effects is vigorously required. In line to this, therefore, herbal medicines ought to be re-evaluated as new dynamic therapeutic agents with minimal side effects [8]

The use of plants as alternative medicine is dated back to centuries, even before long recorded history [9]. People valued, appreciated the great diversity and importance of plants that are accessible to them [10]. As times passed by, people group have added the medicinal power of herbs in their field to its knowledge base [11]. Thus, in the exploration of many more reliable and safer liver protective agents, medicinal plants play a significant role. Medicinal plants being an effective source of both traditional and modern medicines are gaining more ground for use in primary health care [12,13]. Many plants and plant products have been recommended for use in the treatment of liver diseases. Among the plants are, *Silybum marianum* [14], *Picrorrhizakurroa* [15], and *Teptrosiapurpurea* [16] *Khaya senegalensis* [17-19] among others.

The plant, '*Pterocarpus erinaceus* (Fabaceae)' is a tree found in the most tropical areas of Africa [20,21]. In West Africa, its leaves, stem bark, and roots have been reported as highly use for traditional remedies against inflammation, ulcer, pain in the joints, malaria-fever, and bacterial infections [22]. Various scientific studies had confirm *Pterocarpus erinaceus* ability to exhibit several biological activities as well as

identification of several components. For example, analysis of *Pterocarpus erinaceus* aqueous extract has revealed the presence of catechin and epicatechin compounds and had also reported the inhibitory ability of the extract against γ -secretase activity [23]. The bark extract of *Pterocarpus erinaceus* was found to contain friedelin, lupeol, and epicatechin compounds and was able to exert anti-inflammatory, analgesic, and antioxidant activities in a study conducted by Ouedraogo et al. [24].

In traditional medicine practice, *Pterocarpus erinaceus* has been claimed to be used in managing disorders related to tissue-injury, however, this has not been verified scientifically hence the aim of the present study to authenticate this claim. The present study therefore attempted to assess tissue-protective efficiency of *Pterocarpus Erinaceus* leaves extract in carbon-tetrachloride (CCl_4)-induce hepatic and hematological toxicity in rats. This was conducted using an animal model by exposing them to carbon-tetrachloride toxicity, a chemical known to induce both liver and hematologic injuries followed by the administration of *Pterocarpus erinaceus* extract at varied doses.

2. MATERIALS AND METHODS

2.1 Chemicals and Reagents

All chemicals and reagents used for this study were of analytical grade. Chemicals and solvent were purchased from Sigma Chemical Co. (USA) and Merck (Germany) respectively. Different parameters analyzed in the present study were estimated using commercial kits following manufacturer's instructions.

2.2 Experimental Animals

Thirty male Wistar Strain Albino rats weighing between (100-120g) was used for this study. The rats were purchased from the Animal House of University of Jos. The rats were allowed to acclimatize to the environment and were maintained on standard laboratory diet (Vita feed, Jos) and tap water for a period of two weeks. Animals were housed in clean cages under normal prevailing environmental condition. The Principles of laboratory animal care (NIH publication No. 8523, revised 1985) [25] were followed, as well as specific national laws where applicable.

2.3 Plant Collection, Identification and Processing

The leaves of *Pterocarpus erinaceus* was collected from Tulu Village of Toro Local Government in Bauchi State, it was then taken to the Plant Science Department of the University of Jos for identification. The leaves of *Pterocarpus erinaceus* was washed and air dried at room temperature. The sample was pulverized using laboratory mortar and pestle. The powdered sample was then place in bag and store in desiccator until required.

2.4 Extraction

The powder of leaves of *Pterocarpus erinaceus* (500g) was soaked in 2.5 liters of methanol for 24h, after which was filtered using a piece of clean, sterile, white Muslin cloth to remove debris and filter on a Whatman No.1 filter paper. The filtrate was concentrated using a rotatory evaporator and then evaporate to dryness using drying cabinet at 40°C as done by Saidu *et al.* [26]. The dry crude methanolic extract was stored in an air-tired plastic containers and store in a refrigerator at 4°C until required.

2.5 Acute Oral Toxicity Study

The acute oral toxicity studies were conducted according to the method of Organization for Economic and Co-operation and Development for testing of chemicals [27]. The LD_{50} was determined from the result of the study.

2.6 Tissue-Protective Study of Plant Extract

Induction of hepatic damage was done according to Guntupalli *et al.* [28] method. Experimental rats were divided in to 6 groups of five rats each as showed below.

Group 1: Normal control (liquid paraffin, vehicle 1ml/kg)

Group 2: Negative control (received 1ml/kg CCl_4)

Group 3: Positive control (received 1ml/kg CCl_4 +100ml/kg Silymarin)

Group 4-6: Extract treated rats (received 1ml/kg CCl_4 + varied doses of Extracts at 100, 200, and 400mg/kg body weight of rats).

The treatment was done daily via oral mean for 14 days period.

2.6.1 Effect of plant extract against CCl₄-induced hepatotoxicity

The method of Reitman and Frankel [28] modified by Schmidt and Schmidt [29] was used for evaluation Aspartate aminotransferase (AST) and Alanine aminotransferase (ALT) activities. Alkaline phosphatase (ALP) was determined by the method of Wright *et al.* [30]. Serum albumin was measured by the method of Corcoran and Durnan [31] while the method of Malloy and Evelyn, [32] was used to estimate total bilirubin.

2.6.2 Effect of plant extract against CCl₄-Induced hepatic architectural damage

Histopathological test was conducted on liver tissues. The collected livers were kept for at least 24h in the buffered formalin, then each one was dehydrated with alcohol, then embedded in paraffin wax, and cut into 4-5 cm thick sections, and stained with Haematoxylin-Eosin dye for photomicroscopic observations. The microscopic features of the organs from each rat were compared with that of the control group.

2.6.3 Effect of plant extract against CCl₄-disrupt lipid metabolism

Serum TG was estimated by Fossati and Prencipe [33] method and total cholesterol (TC) was estimated by enzymatic Cholesterol oxidase peroxidase (CHO-POD) end point method of Allain *et al* [34]. HDL-C was determined by enzymatic method of Burstein *et al* [35] while LDL-C was calculated using Friedewald formula [36].

$$\text{LDL - C (mg/dl)} = \text{TC} - (\text{HDL - C}) - \left(\frac{\text{TG}}{5}\right)$$

2.6.4 Effect of plant extract against CCl₄-induced hematotoxicity

Hematological parameters viz. Packed Cell Volume (PCV), Hemoglobin concentration, Red Blood Cells count (RBC), White Blood Cells count (WBC), Hematocrit (Hct), Platelets, Mean Cell Hemoglobin Concentration (MCHC) and Mean Cell Hemoglobin (MCH) were analysed using an automated hematological analyzer Sysmex XS800i (Sysmex corporation, USA).

3. STATISTICAL ANALYSIS

All data were expressed as mean \pm SEM. Differences among groups at various times of the experiment were subjected to a one-way analysis of variance (ANOVA) followed by Benferonimultiple comparison. Graph pad Instat were used for data analysis and P value of < 0.05 was considered as significant.

4. RESULTS

4.1 Acute Toxicity Oral Studies of *Pterocarpus erinaceus* Leaves Extract

Oral administration of 100-5000mg/kg of methanolic leaves extracts of *Pterocarpus erinaceus* to albino rats did not produce any visible sign or symptoms of toxicity or mortality in the treated animals. Behavioral changes such as grooming, loss of appetite, salivation, fatigue, diarrhea and refusal to eat and drink were not observed over the test period. Therefore, the result indicated that the LD₅₀ of Methanol leaves extracts of *Pterocarpus erinaceus* is greater than 5000mg/Kg.

4.2 Tissue-Protective Efficiency of *Pterocarpus erinaceus* Leaves Extract

4.2.1 Effects of plant extract against CCl₄-toxicity on liver function

The results of liver function markers for rats administered carbon tetrachloride and methanolic leaves extract of *Pterocarpus erinaceus* is presented in Table 1. The result shows a significant increase in ALT, AST and ALP in carbon tetrachloride treated group (negative control) as compared with the normal control group as well as the various treated rat groups. A decrease in ALT, AST and ALP was recorded in rats administered Silymarin (standard drug) when compared with the negative group. In a similar manner, rats groups that received varied doses of the methanolic leaves extracts of *Pterocarpus erinaceus* also showed a significant decreases in ALT, AST and ALP activities but in a dose dependent manner.

Serum bilirubin and albumin levels determined were also presented for the experimental animals. The negative control rats group (that is, rats administered carbon tetrachloride only) had

Table 1. Assessment of hepatoprotective efficiency of *Pterocarpus erinaceus* leaves extract against carbon-tetrachloride induced hepatic injury

Groups/Parameters	AST (U/l)	ALT (U/l)	ALP (U/l)	BLB (mg/dl)	ALB (mg/dl)
Group 1	66.6±1.29 ^a	28.8±1.71 ^a	167.0±1.41 ^a	0.25±0.01 ^a	4.5±0.15 ^a
Group 2	134.2±1.46 ^b	116.0±1.82 ^b	253.6±2.02 ^b	0.74±0.01 ^b	3.7±0.07 ^b
Group 3	74.4±1.66 ^{ab}	42.4±1.50 ^c	195.2±2.84 ^c	0.41±0.02 ^{ab}	4.3±0.09 ^a
Group 4	119.6±1.66 ^c	107.2±1.43 ^{ab}	225.4±2.94 ^{ab}	0.51±0.01 ^c	3.9±0.09 ^b
Group 5	97.6±1.54 ^d	84.8±1.07 ^d	203.4±1.44 ^d	0.58±0.01 ^c	4.8±0.14 ^{ab}
Group 6	83.0±1.14 ^e	82.0±2.55 ^d	183.6±2.14 ^c	0.69±0.01 ^b	5.0±0.17 ^{ab}

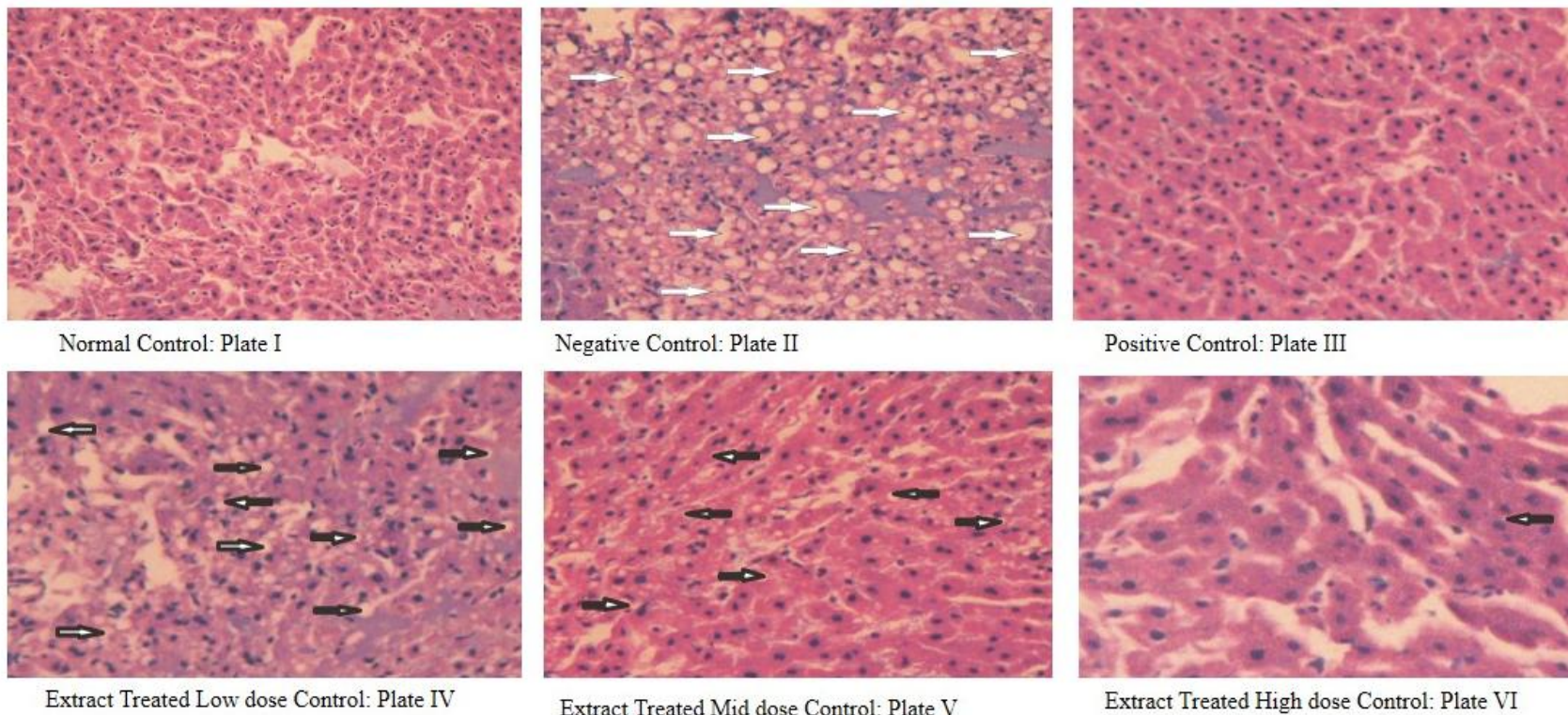
Values are expressed as mean ± SEM of five replicates. Mean values with different superscript letters(s) in a column are significantly different at $P < 0.05$. The treatment was done daily via oral means for 14 days period.

Group 1: Normal control (liquid paraffin, vehicle 1ml/kg)

Group 2: Negative control (received 1ml/kg CCl₄)

Group 3: Positive control (received 1ml/kg CCl₄ +100ml/kg Silymarin)

Group 4-6: Extract treated rats (received 1ml/kg CCl₄ + varied doses of Extracts at 100, 200, and 400mg/kg body weight of rats)



**Plates I-VI. Photomicrograph of the Liver Sections of Experimental Rats Subjected to Different Treated. Hematoxylin and Eosin (H&E)
x 400**

Plate I: normal hepatocytes with no histopathological lesion; Plate II: severe micro and macro vesicular steatosis (fatty liver); Plate III: mild fatty liver with normal hepatocytes at the background; Plate IV: macro vesicular steatosis (fatty liver) and peripheral hepatocellular necrosis. Plate V: moderate steatosis (fatty liver), and Plate VI: showing mild steatosis (fatty liver) at portal areas but no lesion.

The treatment was done daily via oral means for 14 days period

their bilirubin level increase and albumin levels decrease when compared with normal control rats. Administration of silymarin (standard drug) causes a reverse in the changes of both the bilirubin and albumin levels. Also in the same vein, rats that were treated with methanolic leaves extracts of *Pterocarpus erinaceus* had their albumin levels increase in a dose dependent manner.

4.2.2 Effects of plant extract against CCl₄-toxicity on hepatic architecture

Photomicrograph of the liver sections of the experimental rats subjected to different treated is presented in Plates I-VI. Photomicrograph of the liver sections of normal control (Group 1), showing normal hepatocytes with no histopathological lesion (Plate I) while that of CCl₄-intoxicated rats (Group 2) shows severe micro and macro vesicular steatosis (fatty change), (Plate II).The histopathological architecture of liver sections of rats treated with the standard drug (Silymarin) in Group 3, shows very mild steatosis with normal hepatocytes at the background (Plate III). In the rat's groups treated with varied doses of methanolic leaves extract, their liver photomicrograph showed a more or less normal lobular pattern with a mild degree of fatty changes in doses increase manner (Plates IV-VI).

4.2.3 Effects of Plant Extract against CCl₄ on Lipid profile

The serum lipid levels of rats administered carbon tetrachloride and methanolic leaves

extract of *Pterocarpus erinaceu* is presented in Table 2. The result show a significant increase in TG, T.CHO and LDL-C levels of rats treated with carbon tetrachloride (negative control). Increase in the TG, T.CHO and LDL-C were minimized in rat's group received Silymarin (standard drug) in a significant manner when compared with the values from the negative control rats. In rat's groups treated with the methanolic leaves extracts of *Pterocarpus erinaceus*, a decrease in TG, T.CHO and LDL-C was recorded also. Assessment of HDL-C level in the negative control rats showed a decrease while in the treated rats groups with either the standard drug or the methanolic leaves extracts of *Pterocarpus erinaceus* there was a significant increase.

4.2.4 Effects of plant extract against CCl₄ on hematological components

The result of hematological parameters of rats administered carbon tetrachloride and methanolic leaves extract of *Pterocarpus erinaceus* is presented in Table 3. The results showed a significant change in Hb, WBC, RBC, PLT and Hematocrit in rats received carbon tetrachloride only as compared with those rat's groups that received silymarin or methanolic leaves extracts of *Pterocarpus erinaceus*. In the treated rats groups, a reverse in the alteration of the parameters: Hb, WBC, RBC, PLT and Hemotocrit were recorded in a manner close to the normal control rats. The study also observed significant change in MCHC and MCH in the negative control rats compared the silymarin and plant extract treated rats.

Table 2. Effects of *Pterocarpus erinaceus* leaves extract against carbon tetrachloride toxicity on lipid profile of rats

Groups/Parameters	TG (mg/dl)	T.CHO (mg/dl)	HDL-C (mg/dl)	LDL-C (mg/dl)
Group 1	71.2±0.86 ^a	79.0±1.41 ^a	46.2±1.16 ^{ab}	44.6±0.93 ^a
Group 2	133.8±1.07 ^b	123.8±1.36 ^b	31.6±1.21 ^b	140.8±0.58 ^b
Group 3	73.4±1.81 ^a	84.4±1.89 ^c	41.8±0.58 ^{ab}	48.8±1.39 ^a
Group 4	104.0±1.70 ^{ab}	97.0±1.30 ^{ab}	43.4±0.93 ^{ab}	116.0±2.07 ^{ab}
Group 5	80.0±1.58 ^c	87.4±1.72 ^c	44.6±1.69 ^{ab}	92.8±1.66 ^c
Group 6	69.0±1.23 ^a	74.8±2.63 ^a	48.0±1.82 ^{ab}	104.2±1.69 ^d

Values are expressed as mean ± SEM of five replicates. Mean values with different superscript letters(s) in a column are significantly different at P < 0.05.

Group 1: Normal control (liquid paraffin, vehicle 1ml/kg)

Group 2: Negative control (received 1ml/kg CCl₄)

Group 3: Positive control (received 1ml/kg CCl₄ +100ml/kg Silymarin) Group 4-6: Extract treated rats (received 1ml/kg CCl₄ + varied doses of Extracts at 100, 200, and 400mg/kg body weight of rats)

Table 3. Effects of *Pterocarpus erinaceus* leaves extract against carbon tetrachloride-induced hematotoxicity in rats

Parameters	Group 1	Group 2	Group 3	Group 4	Group 5	Group 6
PCV (%)	54.2±0.73 ^a	45.2±1.50 ^b	55.2±1.66 ^b	47.8±1.56 ^b	54.2±1.39 ^a	56.4±2.16 ^a
HB (g/dl)	14.2±0.86 ^a	7.1±0.25 ^b	14.8±0.58 ^a	10.0±0.70 ^{ab}	12.4±0.51 ^a	14.4±0.50 ^a
MCHC(g/dl)	44.2±1.43 ^a	56.6±1.36 ^b	47.4±2.02 ^a	41.6±1.63 ^a	35.8±1.42 ^{ab}	42.8±2.49 ^a
MCH (pg)	19.6±0.93 ^a	25.8±1.16 ^b	18.6±0.93 ^a	14.8±0.66 ^{ab}	18.8±1.16 ^a	17.0±0.84 ^a
WBC(×10 ³) cells/μL	7216±4.52 ^a	2503.6±1.75 ^b	5530.0±8.52 ^c	5113.4±3.95 ^{ab}	6510.4±3.2 ^d	7080.0±21.2 ^e
RBC(×10 ⁶) cells/μL	6.9±0.17 ^a	3.7±0.18 ^b	6.7±0.16 ^c	5.6±0.12 ^{ab}	6.3±0.10 ^c	7.1±0.16 ^a
PLT (×10 ³) cells/μL	425.2±1.77 ^a	80.2±1.56 ^b	380.0±1.70 ^{ab}	145.0±3.23 ^d	240.2±1.77 ^c	311.8±3.23 ^e
Hematocrit (%)	35.4±1.21 ^b	16.8±1.28 ^a	37.6±1.03 ^b	25.8±0.86 ^{ab}	36.4±0.87 ^b	37.6±1.08 ^b

Values are expressed as mean ± SEM of five replicates. Mean values with different superscript letters(s) in a column are significantly different at $P < 0.05$. The treatment was done daily via oral means for 14 days period.

Group 1: Normal control (liquid paraffin, vehicle 1ml/kg) Group 2: Negative control (received 1ml/kg CCl₄)

Group 3: Positive control (received 1ml/kg CCl₄ +100ml/kg Silymarin)

Group 4-6: Extract treated rats (received 1ml/kg CCl₄ + varied doses of Extracts at 100, 200, and 400mg/kg body weight of rats).

5. DISCUSSION

Medicinal plants are known to possess components with curative potentials of certain biological activity [37]. These components are referred to as active principles or phytochemical substances [38]. In an attempt to assess tissue-protective effect of the leaves of *Pterocarpus erinaceus*, acute toxicity study was conducted where the study found the leaves extract to be safe with LD₅₀ greater than 5000mg/kg body weight. This was followed by an *in vivo* study where rats were administered carbon tetrachloride alongside plant extract and various parameters in relation to hepatic and hematological toxicity were assayed.

Acute Toxicity can be described as the adverse effects following oral administration of a substance that results either from a single or multiple exposures in a short space of time usually within 24h [39]. Determination of LD₅₀ (Lethal dose that would kill 50 % of the tested population) is usually the first step in the evaluation of toxic characteristic of a substance [40]. According to Ukwuani *et al.* [41], acute toxicity study is an initial appraisal of toxic manifestations and is one of the initial screening experiments performed with all compounds. The result of the acute oral toxicity of methanol leaves extract of *Pterocarpus erinaceus* suggested to be greater than 5000 mg/kg body weight is an indication of its safety.

The participation of liver in a variety of metabolic activities including biotransformation and excretion of chemical agents makes it more vulnerable and susceptible to toxicity from those agents. To assay *in vivo* tissue-protective potential of *Pterocarpus erinaceus* leaves extract, rats were exposed to carbon-tetrachloride toxicity.

The study found treating rats with *Pterocarpus erinaceus* leaves extract was able to ameliorate the effect of carbon tetrachloride toxicity on hepatocytes. This is also supported by improve changes in lipid proportion toward normalcy of rats received extract and standard drug. The reduction in erythrocytes count, haematocrit ratio, HB level and microcytic-hypochromic recorded in the present study could be attributed to altered hematopoiesis, depletion of erythrocytes, and distraction in the erythropoiesis rate and their facilitated removal from circulation as a result of the toxicity of CCl₄. Reduced rate of

pancytopenia or erythrocyte depletions in rats received plant extract or standard drug alongside CCl₄ suggests possible protective effect of the *Pterocarpus erinaceus* leaves extract against CCl₄-toxicity.

High significant decrease of WBCs count and increases in MCHC and MCH in rats intoxicated with CCl₄ may indicate lymphopenia. The abnormal hematologic parameter changes in total and differential leukocytes count caused by CCl₄ may be attributed to the inflammatory response by the tissues. As a defensive mechanism of immune system, studies has found that, treatment of rats with CCl₄ cause a release of neutrophil pool into circulation [42,43]. Reversal of these changes by concomitant administration of *Pterocarpus erinaceus* leaves extract may be an indication that the leaves possess components with anti-inflammatory properties.

In vivo studies of CCl₄ have shown that it causes steatosis [44,45]. Steatosis was observed from the liver tissues of rats in the CCl₄ control group as well as extract treated rats but in a different degrees. Moderate to mild formation of steatosis in the extract-treated rats suggest the ability of *Pterocarpus erinaceus* leaves extract in protecting the liver against the toxicity of CCl₄.

6. CONCLUSION

The study have affirmed that CCl₄ induced tissues damage in albino rats, and that, methanol leaves extract of *Pterocarpus erinaceus* able to minimize the severity of CCl₄ toxicity. Findings from this study have aid in validating the traditional use of *Pterocarpus erinaceus* leaves in the treatment of cellular damage due to chemical toxicants. The study has discover *Pterocarpus erinaceus* leaves possess components with tissue-protective properties hence the need to harness it for utilization.

ETHICAL APPROVAL

All experiments have been examined and approved by the appropriate ethics committee of the University of Jos, Nigeria.

ACKNOWLEDGEMENT

The study acknowledge the efforts of Ja'afaru Sa'adu from the Department of Medical

Biochemistry, ATBU Bauchi, Nigeria for his technical assistance during the experiment.

COMPETING INTERESTS

The authors have declared that no conflict of interest exist in regard to this manuscript.

REFERENCES

- Jorum OH, Piero NM. Haematological effects of dichloromethane-methanolic leaf extracts of *Carissa edulis* (Forssk.) Vahl in normal rat models. J Hematol Thromboembolic Dis 2016;04. DOI: 10.4172/2329-8790.1000232.
- Owoade AO, Adetutu A, Olorunnisola OS. Hematological and biochemical changes in blood, liver and kidney tissues under the effect of tramadol treatment. J Alcohol Drug Depend. 2019;07:1-7. DOI: 10.35248/2329-6488.19.7.326.
- Mugoni V, Postel R, Catanzaro V, De Luca E, Turco E, Digilio G, Silengo L, Murphy MP, Medana C, Stainier DY, Bakkens J, Santoro MM. Ubiad1 is an antioxidant enzyme that regulates eNOS activity by CoQ10 synthesis. Cell. 2013;152(3):504-18. DOI: 10.1016/j.cell.2013.01.013.
- Ilyas U, Katare DP, Aeri V, Naseef PP. A review on hepatoprotective and immunomodulatory herbal plants. Pharmacogn Rev. 2016;10(19):66-70. DOI: 10.4103/0973-7847.176544.
- Beretta G, Facino RM. Recent advances in the assessment of the antioxidant capacity of pharmaceutical drugs: From *in vitro* to *in vivo* evidence. Anal Bioanal Chem. 2010; 398(1):67-75. DOI: 10.1007/s00216-010-3829-y.
- Niki E. Assessment of antioxidant capacity *in vitro* and *in vivo*. Free Radic Biol Med. 2010;49(4):503-15. Doi: 10.1016/j.freeradbiomed.2010.04.016.
- Ostapowicz G, Fontana RJ, Schiødt FV, Larson A, Davern TJ, Han SH, et al. Results of a prospective study of acute liver failure at 17 tertiary care centers in the United States. Ann Intern Med. 2002;137(12):947-54. Doi:10.7326/0003-4819-137-12-200212170-00007.
- Tong J, Yao X, Zeng H, Zhou G, Chen Y, Ma B, Wang Y. Hepatoprotective activity of flavonoids from cichorium glandulosum seeds *in vitro* and *in vivo* carbon tetrachloride-induced hepatotoxicity. J Ethnopharmacol. 2015;174:355-63. Doi: 10.1016/j.jep.2015.08.045.
- Jamshidi-Kia FZ, Lorigooini et al. Medicinal plants: Past history and future perspective. Journal of Herbmed Pharmacology. 2018; 7:1-7. DOI: 10.15171/jhp.2018.01.
- Li G, Lou HX. Strategies to diversify natural products for drug discovery. Med Res Rev. 2018;38(4):1255-1294. DOI: 10.1002/med.21474.
- Dereli FTG, Ilhan M, Akkol EK. New drug discovery from medicinal plants and phytoconstituents for depressive disorders. CNS Neurol Disord Drug Targets. 2019;18(2):92-102. DOI:10.2174/1871527317666181114141129
- Santos PRV, Oliviera ACX, Tomassini TCB. Control microbiologic products fitorapicos. Rev. fam. Bioquim. 1995;31: 35-38.
- Oteng Mintah S, Asafo-Agyei T, Archer MA, Atta-Adjei Junior P, Boamah D, Kumadoh D, Agyare C. Medicinal plants for treatment of prevalent diseases. Intech Open; 2019. DOI: 10.5772/intechopen.82049.
- Wallace K, Burt AD, Wright MC. Liver fibrosis. Biochem J. 2008;411(1):1-18. Doi: 10.1042/BJ20071570.
- Liu CT, Chuang PT, Wu CY, Weng YM, Chen W, Tseng CY. Antioxidative and *in vitro* hepatoprotective activity of bupleurum kanoi leaf infusion. Phytother Res. 2006;20(11):1003-8. DOI: 10.1002/ptr.1946.
- Opoku AR, Ndlovu IM, Terblanche SE, and Hutchings AH. *In vivo* hepatoprotective effects of *Rhoicissustridentata* subsp. *cuneifolia*, a traditional zulu medicinal plant against carbon tetrachloride-induced acute liver injury in rats. South African J of Botany. 2007;73(3):372-377. Available:https://doi.org/10.1016/j.sajb.2007.02.193.
- Baytop T. Therapy with medicinal plants in turkey, nobel tip basimevi, Istanbul, Turkey; 1999.
- Mhya DH, Umar IA, Onyike E. Anti-peroxidative and biochemical protective activity of *khaya senegalensis* stem bark

- extract on rats fed pesticide-infused feed. International Journal of Pharma Sciences and Research. 2014;5(07):385-390. Available:<https://www.ijpsr.info/docs/IJPSR14-05-07-024.pdf>.
19. Mhya DH, Umar IA, Onyike E. Cytoprotection by khaya senegalensis extract on rats fed pesticide-infused feed. International Journal of Toxicological and Pharmacol-ogical Research. 2014,6(4): 6(4):75-79. Available: <https://ijtpr.com/volume6issue4/>.
 20. Tittikpina NK, NanaF, Fontanay S, Philippot S, Batawila K, Akpagana K, et al. Antibacterial activity and cytotoxicity of pterocarpus erinaceuspoir extracts, fractions and isolated compounds. J. Ethnopharmacol. 2018; 212:200–207. Available:<https://doi.org/10.1016/j.jep.2017.10.020>.
 21. Tittikpina NK, Atakpama W, Pereki H, Nasim M, Ali W, Fontanay S, et at. Capiture Plants with interesting biological activities: A case to go. Open Chem. 2017;15:208–218. Available:<https://doi.org/10.1515/chem-2017-0024>.
 22. Noufou O, Anne-E H, Claude WOJ, Richard SW, André T, Marius LJ. Biological and phytochemical investigations of extracts from pterocarpus erinaceuspoir (Fabaceae) root barks. Afr. J. Tradit. Complement. Altern. Med. 2017; 14:187195. Available:<https://doi.org/10.21010/ajtcam.v14i1.21>.
 23. Hage S, Stanga S, Marinangeli C, Octave JN, Dewachter I, Quetin-Leclercq J, et al. Characterization of pterocarpus erinaceuspoir extract and its gamma-secretase inhibitory properties. J. Ethnopharmacol. 2015;163:192–202 Available:<https://doi.org/10.1016/j.jep.2015.01.028>.
 24. Ouédraogo N, Sawadogo RW, Tibiri A, Bayet C, Lompo M, Hay AE et al. Pharmacolo-gical properties and related constituents of stem bark of Pterocarpus erinaceuspoir. (Fabaceae). Asian Pac. J. Trop. Med. 2012;5: 46–51. Available: [https://doi.org/10.1016/S1995-7645\(11\)60244-7](https://doi.org/10.1016/S1995-7645(11)60244-7).
 25. National Institute of Health (NIH). Principles of Laboratory Animal Care. NIH Publication. 1985;85-23.
 26. Saidu Y, Bilbis LS, Lawal M, Isezuo SA, Hassan SW, Abbas AY. Acute and sub-chronic toxicity studies of crude aqueous extract of Albizziachevalieri harms. Asian Journal of Biochemistry. 2007;2(4):224-236. DOI: 10.3923/ajb.2007.224.236
 27. OECD. Organization for economic co-operation and development. OECD guidelines for testing chemicals, acute up and down procedure no. 200;425:1-2.
 28. Rao GM, Rao CV, Pushpangadan P, Shirwaikar A. Hepatoprotective effects of rubiadin, a major constituent of *Rubia cordifolia* Linn. J Ethnopharmacol. 2006;103(3):484-90. DOI: 10.1016/j.jep.2005.08.073.
 29. Reitman S. Frankel SA. Colorimetric method for the determination of serum glutamic oxalacetic and glutamic pyruvic transaminases. Am J Clin Pathol. 1957; 28(1):56-63. Doi: 10.1093/ajcp/28.1.56.
 30. Schmidt E. Schmidt FW. Enzymes and Biological Chemistry. 1963;3:1.
 31. Wright PJ, Leathwood PD, Plummer DT. Enzymes in rat urine: Alkaline phosphatase. Enzymologia. 1972;42(4): 317-27.
 32. Corcoran RM, Durnan SM. Albumin determination by a modified bromcresol green method. Clin Chem. 1977;23(4): 765-6.
 33. Malloy HT, Evelyn KA. Estimation of serum bilirubin level. Journal of Biological Chemistry: 1937;191:481.
 34. Fossati P, Prencipe L. Serum triglycerides determined colorimetrically with an enzyme that produces hydrogen peroxide. Clin. Chem., 1982;28:2077-2080. Available:<https://doi.org/10.1093/clinchem/28.10.2077>
 35. Allain CC, Poon LS, Chan CS, Richmond W, Fu PC. Enzymatic determination of total serum cholesterol. Clin Chem. 1974; 20(4):470-5.
 36. Burstein M, Scholnick HR, Morfin R. Rapid method for the isolation of lipoproteins from human serum by precipitation with polyanions. J Lipid Res. 1970;11(6):583-95.
 37. Friedewald WT, Levy RI, Fredrickson DS. Estimation of the concentration of low density lipoprotein cholesterol in plasma, without use of the preparative

- ultracentrifug. Clin. Chem., 1972; 18:499502.
Available:<https://doi.org/10.1093/clinchem/18.6.499>.
38. Oladeji O. The characteristics and roles of medicinal plants: Some important medicinal plants in Nigeria. Nat Prod Ind J. 2016;12(3):102.
39. Mhya DH, Mankilik M. Phytochemical screening of aqueous extract of *Luffa aegypt-iaca* (Sponge gourd) leave sample from Northern Nigeria: A short communication. International Journal of Pharma Sciences and Research. 2014;5 (07):344-345.
Available:<http://www.ijpsr.info/abstract.php?file=14-05-07-018>
40. IUPAC. Compendium of chemical terminology, 1997, 2nd edition (the golden book).
41. Ogbuehi IH, Ebong OO. Obianime AW. Oral acute toxicity (LD₅₀) study of different solvent extracts of *Abrus precatorius* Linn leaves in Wistar rats. European Journal of Experimental Biology. 2015;5(1):18-25.
42. Ukwuani AN, Abubakar MG, Hassan SW, Agaie BM. Toxicological studies of hydromethanolic leaves extract of *Grewiacrenata*. International Journal of Pharmaceutical Sciences and Drug Research. 2012;4(4): 245-249.
43. Patrick-Iwuanyanwu KC, Wegwu MO, Ayalogu EO. Prevention of CCl₄-induced liver damage by ginger, garlic and vitamin E. Pak J Biol Sci. 2007;10(4): 617-21.
Doi: 10.3923/pjbs.2007.617.621.
44. Saba AB, Oyagbemi AA and Azeez OI. Amelioration of carbon tetrachloride-induced hepatotoxicity and haemotoxicity by aqueous leaf extract of *Cnidioscolus aconitifolius* in rats. Nig. J. Physiol. Sci. 2010;25:139 –147.
45. Poli G, Gravela E, Albano E, Dianzani MU. Studies on fatty liver with isolated hepatocytes. II. The action of carbon tetrachloride on lipid peroxidation, protein, and triglyceride synthesis and secretion. Exp Mol Pathol. 1979;30(1):116-27.
DOI: 10.1016/0014-4800(79)90086-8

© 2023 Mohammed et al.; This is an Open Access article distributed under the terms of the Creative Commons Attribution License (<http://creativecommons.org/licenses/by/4.0>), which permits unrestricted use, distribution, and reproduction in any medium, provided the original work is properly cited.

Peer-review history:

The peer review history for this paper can be accessed here:
<https://www.sdiarticle5.com/review-history/101279>