



## **Interference with Laboratory Test Results Due to Multiple Myeloma Related Hypergammaglobulinemia: An Illustrative Case Report**

**Nishit Gupta<sup>1</sup>, Rasika Setia<sup>2</sup>, Aditi Mittal<sup>1</sup>, Dharma Choudhary<sup>3</sup>,  
Raj Kumar Kapoor<sup>4</sup>, Tina Dadu<sup>1</sup> and Anil Handoo<sup>1\*</sup>**

<sup>1</sup>Department of Hematology, BLK Super Speciality Hospital, Rajendra Place, Delhi, 110005, India.

<sup>2</sup>Department of Transfusion Medicine, BLK Super Speciality Hospital, Rajendra Place, Delhi, 110005, India.

<sup>3</sup>Department of Hemato-oncology and Bone Marrow Transplant, BLK Super Speciality Hospital, Rajendra Place, Delhi, 110005, India.

<sup>4</sup>Department of Biochemistry, BLK Super Speciality Hospital, Rajendra Place, Delhi, 110005, India.

### **Authors' contributions**

*This work was carried out in collaboration among all authors. Author NG compiled the hematology and clinical chemistry data, prepared the figures and wrote the manuscript. Author RS analysed and compiled the blood grouping and cross matching data. Author AM analysed the patient demographic data and laboratory investigation. Author DC provided clinical information and treatment profile. Author RKK analyzed the biochemistry data. Author TD analysed the patient demographic data, hematology and clinical chemistry data. Author AH compiled the data and wrote the manuscript. All authors read and approved the final manuscript.*

### **Article Information**

(1) Dr. Noha Mohamed Kamel, Assistant Professor, Department of Clinical Pathology, Suez Canal University, Egypt.

*Editor(s):*

(1) Ekaterini Simões Goudouris, Universidade Federal do Rio de Janeiro, Brazil.

*Reviewers:*

(2) Veeravan Lekskulchai, Srinakharinwirot University, Thailand.

Complete Peer review History: <http://www.sdiarticle4.com/review-history/53317>

**Case Study**

**Received 08 October 2019  
Accepted 14 December 2019  
Published 20 December 2019**

### **ABSTRACT**

**Introduction:** Excessive production of plasma proteins in concentrations exceeding physiologic limits in multiple myeloma can be an important source of laboratory test interference and can potentially affect test methodologies on various instrument platforms.

**Case Study:** A 56 year old male, presented with generalized weakness and breathlessness on exertion of one month's duration. Complete blood counts revealed severe anemia with thrombocytopenia and marked increase in rouleaux formation. There was reversal of Albumin: Globulin ratio with increased urea and creatinine, hyponatraemia and hyperphosphataemia. Although there was no bleeding or thrombotic manifestation, coagulogram showed prolongation of both prothrombin time and activated partial thromboplastin time and mixing studies confirmed common coagulation pathway factor deficiency. In view of severe anemia, two units of packed red cells were requested. Antibody screening showed panreactivity in Coombs phase which was equivocal on enzyme phase and all the units put up for crossmatch were compatible in saline phase but 2+ to 4+ incompatible in Coombs phase. Eleven cell antibody identification panel showed panreactivity. Polyspecific direct antiglobulin test was positive and monospecific antihuman globulin direct antiglobulin test confirmed isolated IgG positivity. Antibody screen and identification became negative after warm saline wash and auto-adsorption. X-ray skull and chest revealed multiple punched-out lytic lesions. Bone marrow examination revealed 62% plasma cells. Together with the clinical profile, blood chemistry and radiological parameters, a diagnosis of IgG Lambda multiple myeloma was considered.

**Conclusions:** Hypergammaglobulinemia secondary to multiple myeloma can potentially produce a plethora of alterations in laboratory tests across different platforms. Clinicians must be cognizant with actionable lab test results and the laboratory must take appropriate timely actions to prevent erroneous results in such patients.

*Keywords: Hypergammaglobulinemia; multiple myeloma; direct antiglobulin test.*

## 1. INTRODUCTION

Multiple myeloma (MM) results from the expansion of immunoglobulin secreting terminally differentiated B-cells that typically secrete a single homogeneous monoclonal immunoglobulin called as M-protein. It accounts for 1% of all malignant tumours and 10-15% of all haematological malignancies. It is more common in men than women (male: female ratio 1.1:1) and twice more frequent in black population than white [1]. The global age standardized rate (ASR) for incidence of MM is 1.4/100,000 population accounting to 100,000 new cases every year. In the United States of America, the ASR for incidence is higher at 5.8/100,000 population accounting for 21,000 new cases each year while the ASR for MM incidence in India is 0.7/100,000 population amounting for 6,800 new cases a year [2].

Excessive production of plasma proteins in concentrations exceeding physiologic limits can be an important source of laboratory test interference which can potentially affect test methodologies on various instruments [3,4,5]. Here we report a case of multiple myeloma related hypergammaglobulinemia causing factitious hematological and clinical chemistry results, along with interferences in pre-transfusion compatibility testing.

## 2. CASE STUDY

A 56 year old male, presented to our hospital's emergency department with generalized weakness and breathlessness on exertion of one month's duration. Baseline investigations (Table 1) revealed a total leukocyte count (TLC) of  $4.8 \times 10^3/\mu\text{L}$  (with 92% Neutrophils, 08% lymphocytes), severe anemia with a hemoglobin (Hb) 4.6 g/dL and mild thrombocytopenia (platelet count  $112 \times 10^3/\mu\text{L}$ ).

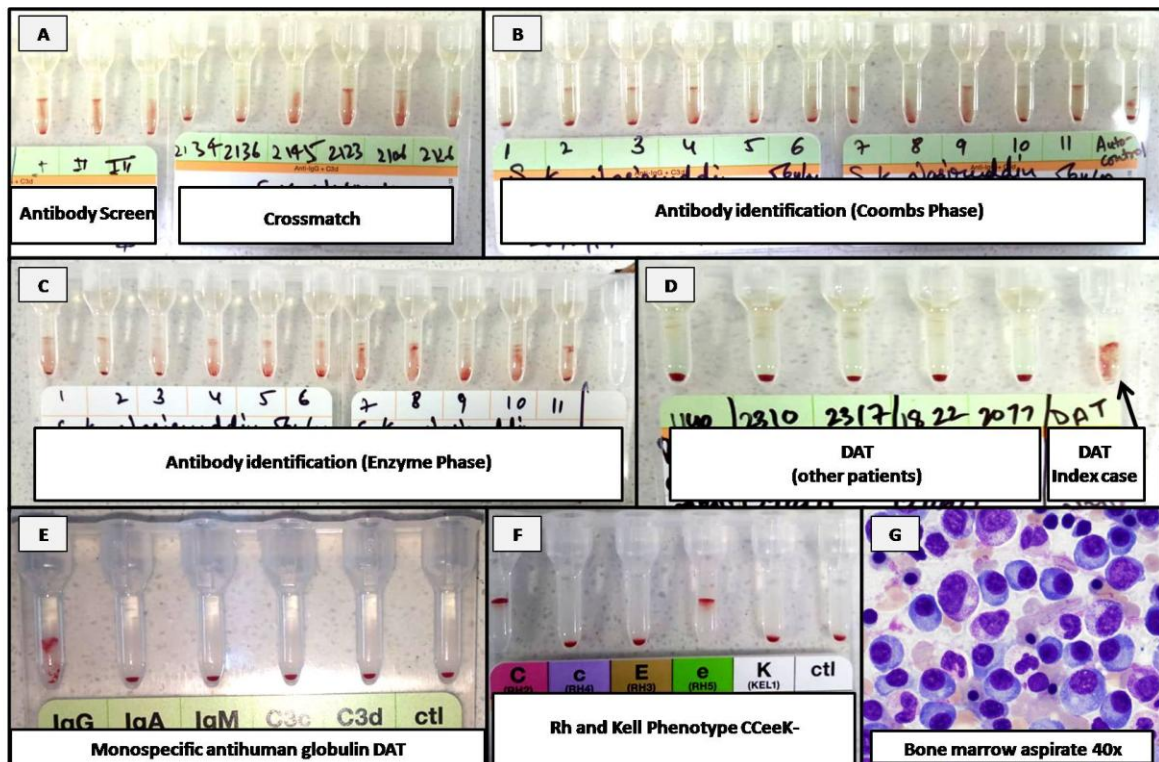
Peripheral smear revealed marked rouleaux formation. Coagulogram showed prolongation of prothrombin time (PT) as well as activated partial thromboplastin time (aPTT). Both PT and aPTT got completely corrected on addition of pooled normal plasma (at 0 hours and 2 hours) indicating a common pathway factor deficiency. Further PT and aPTT also got corrected by addition of aged serum, however no correction was seen on addition of adsorbed plasma suggestive of a common pathway factor deficiency; likely Factor X. Liver function tests revealed mild unconjugated hyperbilirubinemia with reversal of Albumin: Globulin ratio and renal function tests showed renal impairment with increased urea and creatinine, hyponatraemia and hyperphosphataemia.

In view of severe anemia request for two units packed red cells was sent to the department of

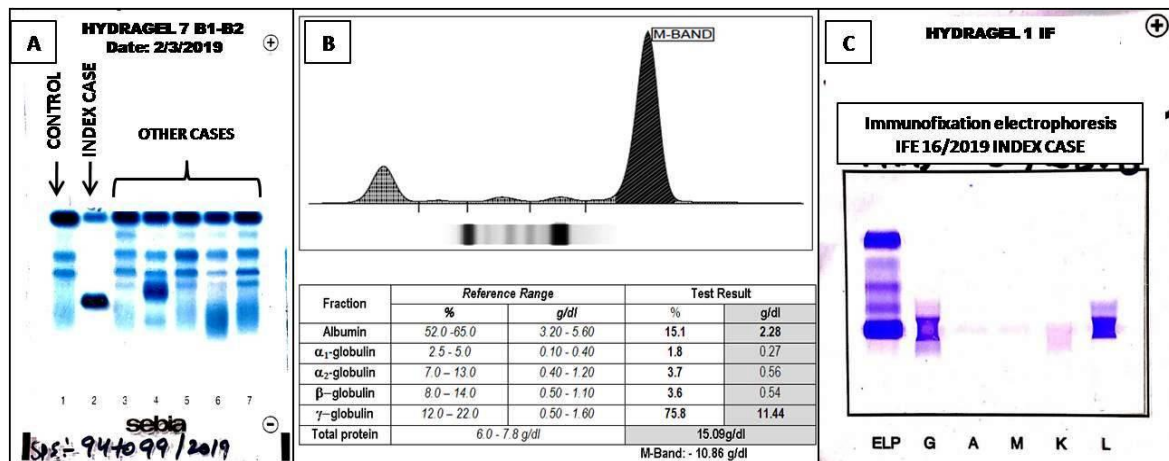
**Table 1. Hematology and chemistry results**

Laboratory test*	Result	Reference range	Methodology
Total leukocyte count	4.68 x 10 <sup>3</sup> /μL	4.0 – 10.0 x 10 <sup>3</sup> /μL	Fluorescence Flowcytometry
Haemoglobin	7.3 g/dL	13.0 – 17.0 g/dL	Sodium Lauryl Sulphate
MCV	86.7 fL	82.0 – 97.0 fL	RBC pulse height
Platelet count	112 x 10 <sup>3</sup> /μL	150 – 450 x 10 <sup>3</sup> / μL	Electrical Impedance/optical
Reticulocyte count	2.33%	1 – 3 %	Fluorescence Flowcytometry
Bilirubin Total	2.44 mg/dL	0.0 – 1.2 mg/dL	Diazo method
Bilirubin Direct	0.36 mg/dL	0.0 – 0.3 mg/dL	Diazo method
Bilirubin Indirect	2.08 mg/dL	0.0 – 0.9 mg/dL	Calculated
Total Protein	15.63 g/dL	6.0 – 8.3 g/dL	Biuret Method
Albumin	1.77 g/dL	3.9 – 4.9 g/dL	Bromocresol Green method
Globulin	13.86 g/dL	3.0 – 4. g/dL	Calculated
Urea	136.3 mg/dL	10.0 – 48.5 mg/dL	Urease, Kinetic
Creatinine	8.01 mg/dL	0.7 – 1.3 mg/dL	Jaffe, Kinetic
Uric Acid	12.60 mg/dL	3.4 – 7.0 mg/dL	Uricase
Calcium (serum)	9.9 mg/dL	8.6 – 10.0 mg/dL	BAPTA
Phosphorous (serum)	7.06 mg/dL	2.4 – 4.5 mg/dL	Phosphomolybdate
Sodium (serum)	128.0 mmol/L	136 – 145 mmol/L	Ion selective electrode (ISE) Indirect
Potassium (serum)	4.04 mmol/L	3.5 – 5.1 mmol/L	Ion selective electrode (ISE) Indirect

\* Hematology and chemistry tests were performed on Mindray CAL 8000 BC 6800 Plus (Shenzhen, China) and Roche COBAS c501 (Basel, Switzerland) analysers respectively



**Fig. 1. A) Antibody screen showing panreactivity with incompatible crossmatch results. B) Antibody identification 11 cell panel showing panreactivity in Coombs phase which remained un-effected during enzyme phase C. D) Direct antiglobulin test positive 2+ in patient which was found to be due to IgG on monospot direct antiglobulin test E. F) Rh and Kell Phenotype of the patient CCeek- G) Bone marrow aspirate showing 62% plasma cells**



**Fig. 2. A) and B) Serum Protein electrophoresis (Sebia Hydragel, France), C) Immunofixation Electrophoresis (Sebia Hydragel, France)**

transfusion medicine. Blood grouping was done by column agglutination technology (CAT) using DiaClon ABO/D + Reverse Grouping Cards (BIO-RAD, Switzerland) and was found to be B-POSITIVE. Antibody screening was done using three cell panels (ID-DiaCell I-II-III Asia panel by BIO-RAD, Switzerland) which showed panreactivity in Coombs phase which was equivocal on enzyme phase and the units put up for crossmatch were compatible in saline phase but 2+ to 4+ incompatible in Coombs phase (Fig. 1A). A direct antiglobulin test and antibody identification was then put up using 11 cell panels (ID-DiaPanel-P by BIO-RAD, Switzerland) on CAT with LISS/Coombs Cards (ID-Cards by BIO-RAD, Switzerland) which also showed panreactivity (Fig. 1B, Fig. 1C). Polyspecific direct antiglobulin test was positive (Fig. 1D). Therefore a monospecific antihuman globulin direct antiglobulin test was done which showed isolated IgG positivity, suggestive of a warm type of autoantibody (Fig. 1E).

As the patient had received blood transfusion in the past, adsorption elution tests were done to rule out any underlying red cell alloantibody. Antibody screen and identification became negative after warm saline wash and auto-adsorption, suggestive of a weakly reactive autoantibody or non-specific coating of red cells with IgG immunoglobulins. Serum IgG immunoglobulin was performed and found to be 10,739 mg/dL with normal IgA and IgM. Serum protein electrophoresis (SPE) revealed a large monoclonal band of 10.86 g/dL in the  $\gamma$ -globulin region (Fig. 2A and 2B) which was confirmed to be IgG- $\lambda$  on serum immunofixation

electrophoresis (IFE) (Fig. 2C). X-ray skull and chest revealed multiple punched-out lytic lesions. Bone marrow examination revealed 62% plasma cells (Fig. 1G). Together with the clinical profile, blood chemistry and radiological parameters, a diagnosis of IgG Lambda multiple myeloma was considered.

### 3. DISCUSSION

Multiple myeloma is characterized by proliferation of neoplastic clonal plasma cells in the bone marrow associated with repression of normal hematopoiesis, leading to anemia and thrombocytopenia manifesting clinically as fatigue and bleeding. Overproduction of immunoglobulins by these plasma cells leads to renal impairment due to renal tubular damage induced by the filtered monoclonal free light chains, manifesting with increased urea, creatinine and uric acid [6,7] as seen in our patient also.

Hypergammaglobulinemia can be a potential cause of erroneous results across different laboratory testing platforms. The increased blood viscosity may lead to difficult aspiration of blood sample causing tests to be performed on lower than the usual volume giving falsely low results [6].

Diverse acquired haemostatic abnormalities are commonly seen in patients with myeloma and can manifest as either thrombosis or bleeding. The excessive monoclonal immunoglobulin increases blood viscosity and interacts with platelets and coagulation factors leading to coagulopathy. Abnormal screening coagulation

tests have been commonly reported in patients with myeloma, majority are however asymptomatic [8-12]. Acquired factor X deficiency, in particular, is common in cases of multiple myeloma and amyloidosis and only rarely leads to clinically relevant bleeding. In our case, both PT and aPTT were prolonged and mixing studies (including aged serum and adsorbed plasma) confirmed a deficiency of common coagulation pathway factor deficiency; likely factor X. The patient however did not have any bleeding/ thrombotic manifestations.

Excessive immunoglobulins can impose a challenge during pre-transfusion compatibility testing and a delay in blood product availability by precluding the correct and timely identification of irregular blood group antibodies. In our patient, the reaction pattern of antibody screening and identification panels and monospecific direct antiglobulin test, indicated interference due to IgG immunoglobulins and the antibody screen and identification became negative after warm saline wash and auto-adsorption.

Immunoglobulin excess may lead to pseudohyponatraemia due to “*volume displacement phenomenon*”. Marked increase in plasma proteins can cause displacement of blood’s aqueous component and its dissolved solutes. In the Roche COBAS c501 analyzer (Basel, Switzerland) used at our laboratory, ion-selective electrodes (ISE) are employed that utilize indirect potentiometry, in which patient samples are pre-diluted before the actual measurement process. Sample pre-dilution is based on the assumption that the relative proportion of all plasma constituents is normal which becomes invalid when analyzing samples containing excessive proteins consequently giving falsely low measurements of solutes, most commonly sodium. On instruments that use ISE with direct potentiometry, volume displacement effect can be avoided as electrolyte measurements are performed on undiluted plasma samples [13]. Our patient had low serum sodium, without any clinical symptoms of hyponatraemia and was possibly pseudo-hyponatraemia due to test methodology employed.

Spectrophotometric inorganic phosphate measurement is based on reaction of phosphate ions with ammonium molybdate to form a phosphomolybdate complex in acidic environment, the absorbance of which is measured to determine the final concentration.

The low pH environment of the reaction mixture may cause precipitation of excessive immunoglobulins and increased turbidity, altering light scattering [14-17]. In our patient, serum inorganic phosphate was increased, but serum calcium was within the reference interval (Table 1). Under homeostasis, both these are within a tight physiologic range. Factitious hyperphosphataemia was suspected due to an interfering substance ( $\gamma$ -globulins) in a relatively asymptomatic patient. Resolution of the interference can be obtained by diluting the sample or removing the plasma proteins via various de-proteinization methods [14-17].

Hence hypergammaglobulinemia secondary to multiple myeloma can potentially produce a plethora of alterations in laboratory tests across different instrument platforms.

#### 4. CONCLUSION

Multiple myeloma frequently causes increased production of monoclonal immunoglobulins, which can be a potential source of interference and lead to erroneous lab results, as seen in our patient. The clinician must be cognizant with actionable lab test results in such patients and the laboratory personnel must be aware of such discordant results so that appropriate actions can be taken in a timely manner to prevent such erroneous results.

#### CONSENT

As per international standard or university standard, patient’s consent has been collected and preserved by the authors.

#### ETHICAL APPROVAL

As per international standard, written ethical approval has been collected and preserved by the author(s).

#### ACKNOWLEDGEMENT

We would like to thank the hematology team, hemato-oncology, bone marrow transplant team and biochemistry team and transfusion medicine team.

#### COMPETING INTERESTS

Authors have declared that no competing interests exist.

## REFERENCES

1. Swerdlow SH, Campo E, Harris NL, Jaffe ES, Pileri SA, Stein H, Thiele J (Eds): WHO classification of tumours of haematopoietic and lymphoid tissues (Revised 4<sup>th</sup> edition). IARC: Lyon; 2017.
2. Bora K. Distribution of multiple myeloma in India: Heterogeneity in incidence across age, sex and geography. *Cancer epidemiology*. 2019;59:215-20.
3. Jelinek AG, Bachmann LM. Unexpected test results in a patient with multiple myeloma. *Clinical chemistry*. 2014;60(11): 1375-8.
4. Gogia A, Sikka M, Sharma S, Rusia U. Hemostatic abnormalities in multiple myeloma patients. *Asian Pacific Journal of Cancer Prevention: APJCP*. 2018;19(1): 127.
5. Coppola A, Tufano A, Di Capua M, Franchini M. Bleeding and thrombosis in multiple myeloma and related plasma cell disorders. In *Seminars in Thrombosis and Hemostasis*. 2011;37(8):929-945. © Thieme Medical Publishers.
6. McPherson RA, Pincus MR. Henry's clinical diagnosis and management by laboratory methods E-book. Elsevier Health Sciences; 2017.
7. Rajkumar SV, Dimopoulos MA, Palumbo A, Blade J, Merlini G, Mateos MV, Kumar S, Hillengass J, Kastritis E, Richardson P, Landgren O. International myeloma working group updated criteria for the diagnosis of multiple myeloma. *The lancet oncology*. 2014;15(12):e538-48.
8. Pandey S, Post SR, Alapat DV, Smock KJ, Post GR. Prolonged prothrombin time correlates with serum monoclonal protein concentration in patients with plasma cell dyscrasia. *International Journal of Laboratory Hematology*. 2013;35(4):421-7.
9. Eby C. Pathogenesis and management of bleeding and thrombosis in plasma cell dyscrasias. *British Journal of Haematology*. 2009;145(2):151-63.
10. Huang H, Li H, Li D. Effect of serum monoclonal protein concentration on haemostasis in patients with multiple myeloma. *Blood Coagulation & Fibrinolysis*. 2015;26(5):555-9.
11. Hu H, Wang L, Xu H, Peng J, Jia Y. Clinical analysis of six cases of multiple myeloma first presenting with coagulopathy. *Blood Coagulation & Fibrinolysis*. 2014;25(6):553-6.
12. Reynolds SB, Maghavani DP, Hashmi H. Acquired factor X deficiency in a patient with multiple myeloma: a rare case highlighting the significance of comprehensive evaluation and the need for antimyeloma therapy for bleeding diathesis. *BMJ Case Reports CP*. 2019; 12(9):e230249.
13. D'Orazio P, Miller WG, Myers GL, Dumas BT, Eckfeldt JH, Evans SA, Graham GA, Parsons PJ, Stanton NV. Standardization of sodium and potassium ion-selective electrode systems to the flame photometric reference method; Approved Standard — 2<sup>nd</sup> Edition, C29-A2 [electronic document]. CLSI. 2000;20:1-22.
14. Berth M, Delanghe J. Protein precipitation as a possible important pitfall in the clinical chemistry analysis of blood samples containing monoclonal immunoglobulins: 2 case reports and a review of the literature; 2004.
15. Lee Y, Koo T, Yi JH, Choi JH, Han SW, Park IK, Kim HJ. Pseudohyperphosphatemia in a patient with multiple myeloma. *Electrolyte & Blood Pressure*. 2007;5(2):131-5.
16. Chakraborty S, Sen S, Gupta D, Ghosh SS, Sawant P, Das M. Spurious hyperphosphatemia in a case of multiple myeloma. *Indian Journal of Clinical Biochemistry*. 2014;29(2):250-2.
17. Burtis CA, Ashwood ER, Bruns DE. Tietz textbook of clinical chemistry and molecular diagnostics-e-book. Elsevier Health Sciences; 2012.

© 2019 Gupta et al.; This is an Open Access article distributed under the terms of the Creative Commons Attribution License (<http://creativecommons.org/licenses/by/4.0>), which permits unrestricted use, distribution, and reproduction in any medium, provided the original work is properly cited.

*Peer-review history:*

*The peer review history for this paper can be accessed here:*  
<http://www.sdiarticle4.com/review-history/53317>