



Trimetazidine Prevents Renal Fibrosis Induced by Cyclosporine A in Wister Rats

De la Cruz Rodríguez Lilia Cristina^{1*}, Rey María del Rosario¹
and Ana Verónica Oldano¹

¹Faculty of Biochemistry, Chemistry and Pharmacy, National University of Tucuman, Argentina.

Authors' contributions

This work was carried out in collaboration between all authors. Author DCRLC designed the study, wrote the protocol, and wrote the first draft of the manuscript. Author RMR managed the literature searches, analyses of the study histopatológico and author AVO managed the experimental process. All authors read and approved the final manuscript.

Article Information

DOI: 10.9734/BJPR/2015/17390

Editor(s):

(1) Ali Nokhodchi, Professor of Pharmaceutics and Drug Delivery, School of Life Sciences, University of Sussex, UK.

Reviewers:

(1) Sahar Mohamed Kamal, Pharmacology Department, Ain Shams University, Egypt.

(2) Anonymous, Poland.

Complete Peer review History: <http://www.sciencedomain.org/review-history.php?id=1177&id=14&aid=9466>

Original Research Article

Received 12th March 2015
Accepted 6th April 2015
Published 28th May 2015

ABSTRACT

Cyclosporine A (CyA), an immunosuppressant administered to transplant patients, causes adverse effects such as nephrotoxicity and hepatotoxicity. In kidney slices of rats treated with 25 mg/kg/day of CyA we observed interstitial fibrosis. Ultrastructure revealed edematized mitochondria with loss of internal structure. In previous work with Trimetazidina (TMZ), cytoprotective drug used in cardiac patients, we found that TMZ prevents CyA toxicity. The pretreatment in wister rats with 20 mg/kg/day of TMZ during 20 days and them simultaneously TMZ with cyclosporine A for 120 days, counteracts the interstitial fibrosis.

The aim of this work is to elucidate the effect of TMZ on interstitial fibrosis and interpret its mechanism.

Four groups of eight male Wister rats were prepared. A, control; B, 25 mg/Kg/day CyA; C, 20 mg/Kg/day TMZ +25 mg/Kg/day CyA and D, 20 mg/Kg/day TMZ for 20 days and then TMZ 20 mg/Kg/day + CyA 25 mg/Kg/day. The experiment lasted 140 days. Slices of rats treated with CyA revealed fibrosis, which was quantified using Image Pro-Plus software (NIH). Immunohistochemical techniques evidenced Collagen type I, Transforming Growth Factor β 1 (TGF- β 1) and Monocyte Chemoattractant Protein-1 (MCP-1). However, pretreatment with TMZ for

*Corresponding author: Email: crisdelacruzrodriguez@hotmail.com;

20 days and then with CyA + TMZ prevented fibrosis and immunohistochemistry was negative for the markers studied. We concluded that TMZ protects the cells against the changes produced by the CyA-induced oxygen deficit. TMZ could offset ATP synthesis caused by the chronic administration of CyA. TMZ optimizes the energetic metabolism of the ischemic cell through a metabolic exchange ("switch") between the fatty acid and glucose oxidation. In theory TMZ would reduce strongly the fatty acid oxidation towards glucose, without affecting the mitochondrial respiratory chain efficiency. Furthermore, TMZ increases the production of phospholipids in the mitochondrial membranes, which confers stability to these structures. In previous work check the effect of CyA on the complex I and II of the mitochondrial respiratory chain located in mitochondrial membranes which are the target of the toxic action of CyA.

Keywords: Trimetazidine-cyclosporine; A-renal fibrosis.

1. INTRODUCTION

The last few decades, with the advent of molecular biomarkers, the role of the extracellular matrix in pathological processes has become increasingly relevant. At present, it is known that cell-cell and cell-extracellular matrix interaction play a central role in pathophysiological mechanisms [1,2].

The fibrosis is characterized by an increase in extracellular matrix. Some years ago, the extracellular matrix was considered an inert support whose only role was to keep cells in contact. However, it has recently been found that specifically regulates cell behavior, limiting or promoting the progress of tissue damage. Our *in vivo* works have demonstrated that acute treatment with high doses of Cyclosporine A (CyA) and chronic treatment with different doses of CyA progressively induces interstitial fibrosis, which was observed at the kidney interstitial level [3].

Tubule interstitial fibrosis, generated in experimental obstruction models, is caused by the accumulation of extracellular matrix proteins, especially Collagens type I, III and IV, with mostly Collagen type IV deposition on the basement membrane of tubular cells [4].

Tubule interstitial fibrosis generated in our CyA cytotoxicity model induces tubular atrophy under experimental conditions [5].

In the kidney, the extracellular matrix has multiple components. Their production is regulated by renal cells and their composition in the glomerulus is different from that in the tubular interstice. In renal fibrosis, which is characteristic of chronic kidney disease, the accumulation of extracellular matrix and the plasma proteins such as fibronectin, fibrin, laminin and collagen IV was demonstrated [6].

However, there are few reports concerning the mechanisms of renal fibrosis *in vivo*.

The liver responds in a special way, it is known that fibrogenesis is a dynamic mechanism characterized by excess synthesis of extracellular matrix that may lead to disorganization in the liver architecture by the formation of fibrotic scars [7,8].

As in most tissues, in the liver the main fibrogenic cytokine is Transforming Growth Factor- β 1 (TGF- β 1) and myofibroblast activation processes was clearly demonstrated *in vitro*. TGF- β 1 plays a central role in the fibrogenic process since it induces collagen formation by starry cell [9-11].

Another important molecule released by starry cell after their activation is Monocyte Chemoattractant Protein-1 (MCP-1). This molecule, which induces the migration of monocytes and granulocytes into the liver tissue, participating in the inflammatory reaction [12]. In this context, astrocytes also secrete interleukine 6 (IL-6), a key cytokine in the acute phase liver response [13,14].

Classic studies of chronic tissue injury using rat-mouse animal models demonstrated that cytokines and growth factors are critical in liver and kidney fibrogenesis [15,16].

In order to prevent the fibrosis described in treatment with CyA, in our previous works different drugs were tested: vasodilators as enalapril and L-arginine; antioxidants like Vitamin E, N-Acetylcystein and protectors against dysmetabolism such as Trimetazidine (TMZ) [17].

Among the above drugs, only TMZ showed the ability to prevent and preserve kidney functionality and histoarchitecture. This was demonstrated *in vivo* on chronic experiments in Wistar rats. Structural and ultrastructural studies

and biochemical markers supported our findings [18].

The aim of this work is to determine the mechanism by TMZ prevents Cyclosporine A-induced cytotoxicity and so preserves kidney histoarchitecture and functionality, improving and prolonging the survival of transplant patients.

2. MATERIALS AND METHODS

2.1 Animals and Drugs

The experiments were performed on adult male Wister rats of 180 to 200 g body weight housed in standard cages with a 12 h light-dark cycle (light on at 7:00 a.m.) at 20°C and 60% humidity. The animals were given a standard diet for rodents and tap water.

All experimental procedures complied with the regulations of the European Union (86/60/EEC) and with the recommendations of the Federación de Sociedades Sudamericanas de la Ciencia de Animales de Laboratorio -FESSCAL (Federation of South American Societies of Laboratory Animal Science).

In the treatment of the animals the following drugs were used:

- CyA: Sandimun - Sandoz Laboratories – Germany.
- Trimetazidine: Vastarel - Servier Laboratories-France.

2.2 Experimental Design

The animals were fed a standard rat-mouse chow and divided into four groups (n= 8). The groups were treated according to the following schedule:

Group A: control.

Group B: with 25 mg/Kg/day CyA, the drug being orally administered.

Group C: with 20 mg/Kg/day TMZ + 25 mg/Kg/day CyA .

Group D: pretreated with 20 mg/Kg/day TMZ during 20 days and then treated with 20 mg/Kg/day TMZ + 25 mg/Kg/day CyA for 120 subsequent days.

The duration of the experiment was 140 days for different treated- groups. During the chronic experiment, the animals were studied with daily evaluations of behavior, appetite and activity.

The body weight of the animals was determined at three points in time: at the beginning of the experiment, 60 days after the beginning, and 120 days after the beginning. At the end of the experiment, the kidneys were excised and weighed.

2.3 Biochemical Study

At the beginning and the end of the experiment, blood samples were collected by tail vein puncture and intracardiac puncture, respectively, for biochemical study: markers of renal function as urea and serum creatinine.

2.4 Histological Study

At the end of the experimental design, the animals were decapitated without previous sedation. Then they were bled and kidneys were removed and prepared for structural, histochemistry and immunohistochemistry studies.

Small portions of the kidney previously separated, were washed with physiological solution, fixed in a 10% formaldehyde solution and embedded in paraffin. They were sliced into 4-5 µm-thick sections and stained with hematoxylin-eosin [19]. The histological slices were observed under an Axiostar plus Zeiss optical microscope.

For observation under the electron microscope, the kidney portions were processed as follows: they were fixed in a 3.5% glutaraldehyde solution in 0.1M phosphate buffer at pH 7.40 for 3 h and then placed in 1% osmium tetroxide. Then, the samples were treated with an aqueous solution of 2% uranyl acetate for 40 min. After fixation, the tissues were gradually dehydrated by a successive passage through a series of increasing alcohol concentrations. Finally, they were passed through ketone and embedded in resin. Ultrathin sections were treated with uranyl acetate, placed in citrate and examined at 50 kV with a Zeiss EM 109 transmission electron microscope belonging to LAMENOA-Electron Microscopy Laboratory of Northwestern Argentina (not show).

2.4.1 Histochemistry studies

Mallory's technique:

Slicing into 4- μ m thick sections was performed with a sliding microtome (Zymed Laboratories Inc., USA) and placed on HISTOGRIP slides (Leitz 1401, Germany).

The deparaffinized and hydrated slices were placed in an acid fucsin solution at 0.05% in distilled water for 1 min. Then they were washed and treated with a 1% phosphotungstic acid solution used as a mordant and differentiator. After 30 min, microscope observation revealed that collagen fibers were stained pink. Then they were washed with distilled water and stained with Mallory's technique for 15 min [20].

The stained slices were dehydrated in 96 and 100% alcohol baths for 2 min each, cleared twice in xylol and mounted in Canada balsam.

With Mallory's technique collagen fibers stained blue, epithelial cells orange and muscle cells red.

2.4.2 Immunohistochemistry studies

2.4.2.1 Antigen exposure by immunofluorescence

The samples selected for immunohistochemical studies were deparaffinized three times with xylol for 5 min. Two baths of 1 min each with absolute ethanol and with decreasing alcohol solutions of 96%, 90%, 85% and 70% and finally with distilled water were used to remove the solvent. In order to break protein bonds and expose epitopes, samples were treated with a sodium citrate solution. They were pretreated in a microwave oven at 100°C in a Coplin jar containing sodium citrate buffer solution 0.01 M, pH 6.0 (Merck, Darmstadt, Germany). Then, the samples were incubated for 10 to 20 min and finally washed with PBS pH 7.4 to continue with the immunodetection protocol.

2.4.2.2 Immunofluorescence marking

Once the antigen was exposed, the slices were covered with blocking medium, comprising 2% Blocking Reagent (Roche) and maleic acid buffer (MAB), pH 7.4, for 1 hour. Then they were incubated overnight at 4°C with the corresponding antibodies shown in Table 1. Five washings for 3 min each were performed in MAB. Then the blocking solution was applied for 15 min. Next, incubation with the corresponding secondary antibody was performed for 2h at ambient temperature. The slices were washed with MAB and mounted in an aqueous mounting medium with anti-fading agents (Biomedica, Foster, CA, USA).

The negative control was obtained by omitting the primary antibody.

The secondary antibodies proved to be species-specific for their respective primary antibody.

3. RESULTS

Evaluation of the renal function was carried out in all groups of control and treated animals, an increase in urea and serum creatinine being observed both in animals treated with CyA and in animals simultaneously treated with TMZ and CyA for 140 days (data not shown).

The group pretreated for 20 days with TMZ and then with TMZ and CyA for 120 days showed a protective effect on the renal function with values similar to those in the untreated control (data not shown).

Fig. 1 shows histological slices of rat kidney from control animals and animals treated with 25 mg/kg/day CyA.

Table 1 A. Primary antibodies

Antibody	Species	Supplier	Catalog	Dilution
Collagentype I	Rat-mouse	Santa Cruz Biotech	sc-25974	1:50
MCP-1	Rat-mouse	Santa Cruz Biotech	sc-1785	1:50
TGF- β 1 (V)	Rabbit	Santa Cruz Biotech	sc-146	1:50

Table 1 B. Secondary antibodies

Antibody	Species	Supplier	Catalog	Dilution
Anti-rabbit IgG conjugated to Alexa 488	Goat	Invitrogen	A11070	1:1500
Anti-rabbit IgG conjugated to Alexa 594	Rabbit	Invitrogen	A21223	1:1500

Fig.1B shows an increase in interstitial tissue in animals treated with 25 mg/kg/day CyA for 140 days compared with the control group, Fig. 1A.

Mallory's trichrome staining was used to reveal the presence of fibrosis in the interstitial tissue. Collagen, the main fibrosis marker, was stained blue, as shown in Fig. 2.

Several clinical studies have confirmed that histomorphometric changes in the tubule interstitial compartment contain the best correlating parameters to predict the development of progressive renal insufficiency. The process of interstitial fibrosis is accompanied by an influx of inflammatory cells, up-regulation of fibrogenic cytokines such as transforming growth factor-beta and basic fibroblast growth factor, transient down-modulation of their

antagonists, generation and proliferation of myofibroblasts, and, finally, by accumulation of interstitial collagens and proteoglycans.

We addressed these issues by morphometric analysis of experimental models in rats. Morphometric analysis was performed using a Zeiss microscope equipped with a full color 3CCD camera and KS-400 image analysis software from Zeiss-Kontron, as shown in Fig. 3.

Fig. 3B shows a marked area corresponding to renal interstitial fibrotic tissue. The degree of fibrosis results from the summation of the highlighted areas expressed as % of the total area.

Table 2 summarizes the quantitative criteria used to classify interstitial fibrosis.

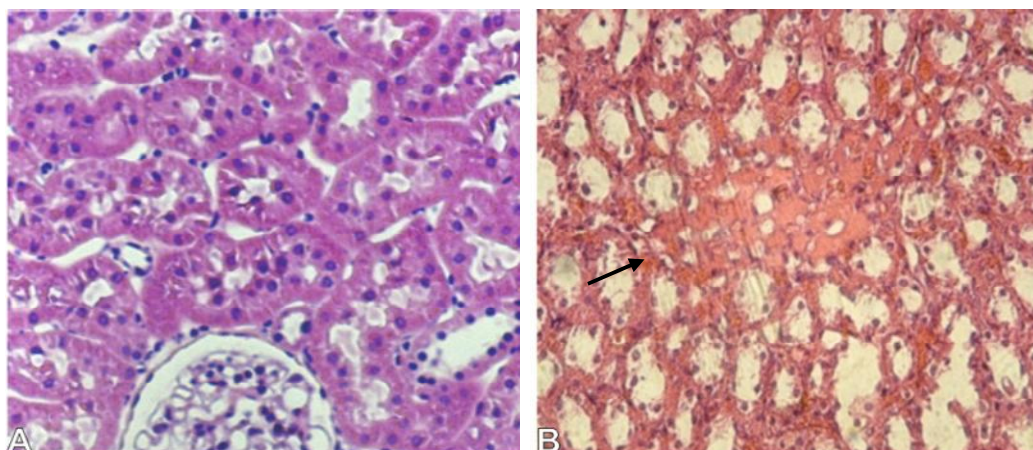


Fig. 1A. Kidney of control rat. B: Kidney treated with CyA for 140 days. Hematoxylin-eosin staining (20 X)

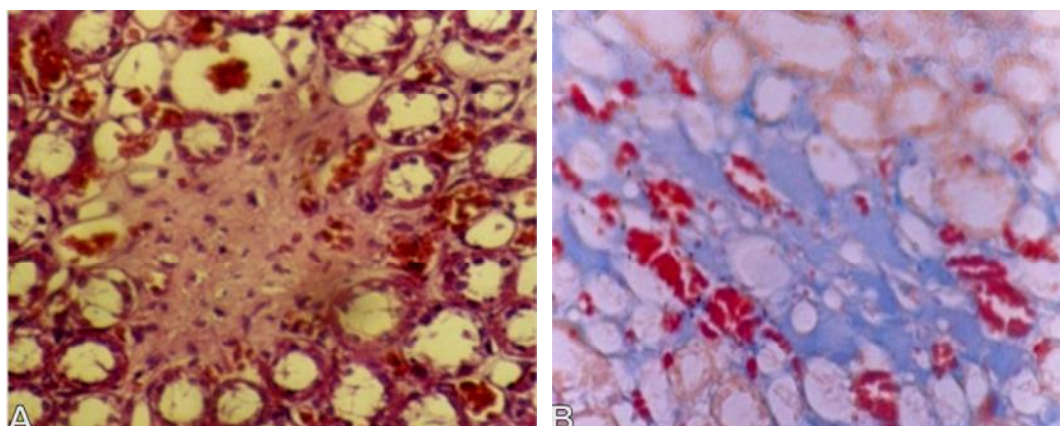


Fig. 2. Kidney slices from rat treated with 25mg/Kg/day CyA. A: Hematoxylin-eosin staining. B: Mallory's trichrome staining (20X)

Table 2. Quantitative criteria

Fibrosis degree 0	fibrosis up to 5%
Fibrosis degree 1	6-25%
Fibrosis degree 2	26-50%
Fibrosis degree 3	above 50%

In order to prevent the fibrosis described above as well as CyA induced nephrotoxicity, different drugs were assayed. Only TMZ used in pretreatment for 20 days followed by combined treatment with TMZ and CyA for 120 days showed protective effect on CyA induced fibrosis.

Fig. 4 shows the results obtained from the quantitative study of the highlighted fibrotic areas in control and treated groups.

The histomorphometric study of the kidney slices from rats treated with 25 mg/kg/day CyA for 140 days revealed a fibrosis percentage of $18 \pm 2\%$, corresponding to degree 1. These results are similar to the ones obtained with simultaneous treatment with TMZ and CyA. Pretreatment for 20 days with 20 mg/kg/day TMZ and after below treatment with TMZ and CyA shows $3 \pm 1\%$ fibrosis, corresponding to degree 0, which is similar to the results obtained with control.

The histogram in Fig. 4 shows that pretreatment with TMZ prevents CyA-induced fibrosis.

Fig. 5 shows rat kidney slices corresponding to the experimental model for the study of fibrosis.

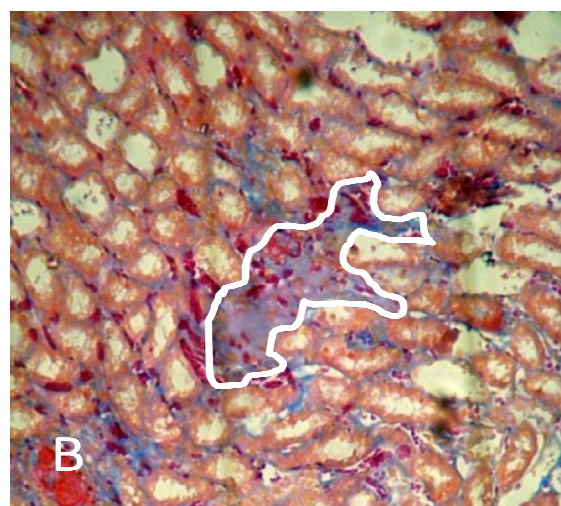
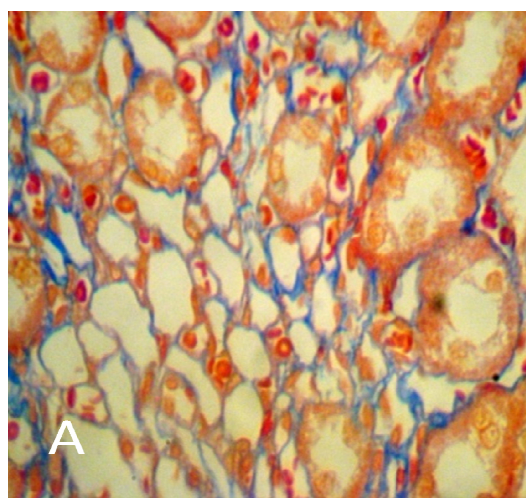


Fig. 3A. Control rat kidney. B Kidney treated with CyA, marked area to study the degree of fibrosis. Mallory's trichrome staining (20X)

Fig. 5A corresponds to control rat kidney. The renal interstitium can be seen as a blue thin delicate structure. Figs. 5B and 5C show kidneys of rats treated with 25 mg/kg/day CyA and with simultaneous chronic treatment with TMZ and CyA for 140 days. Increase in the interstitial space due to increased collagen can be observed in both. Fig. 5D shows kidneys of rats pretreated for 20 days with 20 mg/kg/day TMZ and then simultaneously with 20 mg/kg/day TMZ and 25 mg/kg/day CyA for 120 days. The conserved structure of the renal parenchyma is similar to that in control animals (Fig. 5A).

Detection of Collagen I, a protein that constitutes the extracellular matrix, was conducted using a high specificity monoclonal antibody.

Figs. 6B and 6C show intense staining for Collagen I.

Fig. 6D is similar to Fig. 6A. We concluded that pretreatment with TMZ for 20 days followed by simultaneous treatment with TMZ and CyA for 120 days prevents CyA-induced fibrosis.

Fig. 7 shows the presence of TGF- β 1, an inducer of the activation and accumulation of extracellular matrix, in kidneys of control and treated rats.

Figs. 7B and 7C reveals the presence of TGF- β 1 in treatment with CyA and in simultaneous treatment with CyA and TMZ.

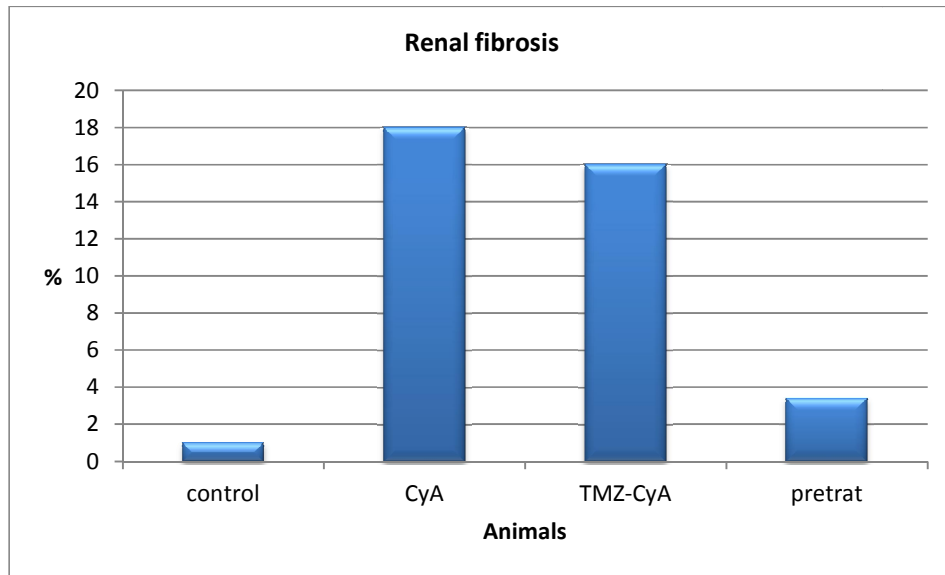


Fig 4. Histogram of control and treated animals

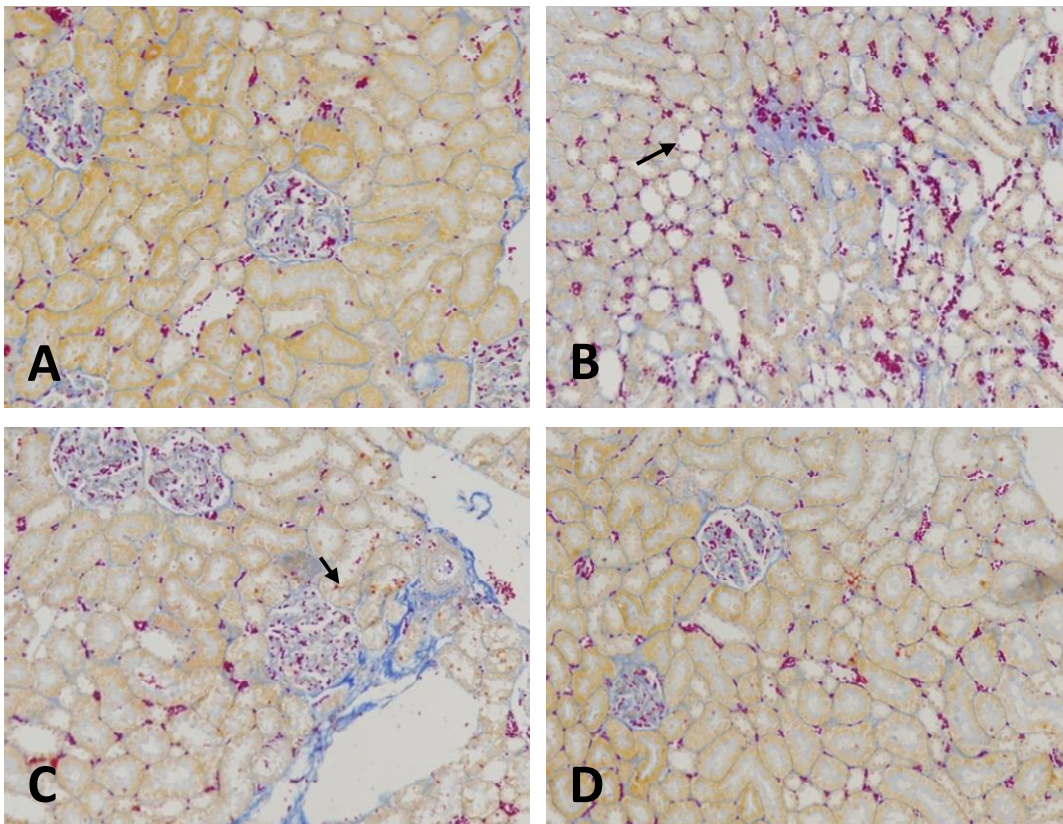


Fig. 5. Kidney sections of control and treated rats. A: Kidney sections of control animals. B: Animals treated with CyA for 140 days. C: Animals simultaneously treated with TMZ and CyA. D: Animals pretreated for 20 days with TMZ and then simultaneously with TMZ and CyA for 120 days. Mallory's trichrome staining 10x

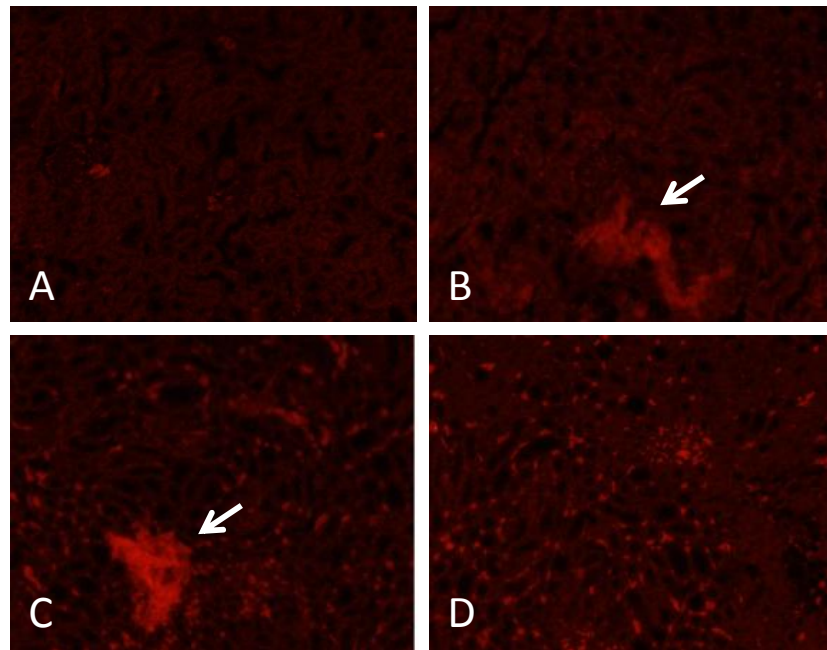


Fig. 6. Immunodetection of Collagen I in kidney of control and treated rats. **A:** control kidney. **B:** kidney of rats treated with CyA for 140 days. **C:** kidney of animals simultaneously treated with CyA and TMZ for 140 days. **D:** kidney of animals pretreated with TMZ for 20 days and then with CyA and TMZ for 120 days

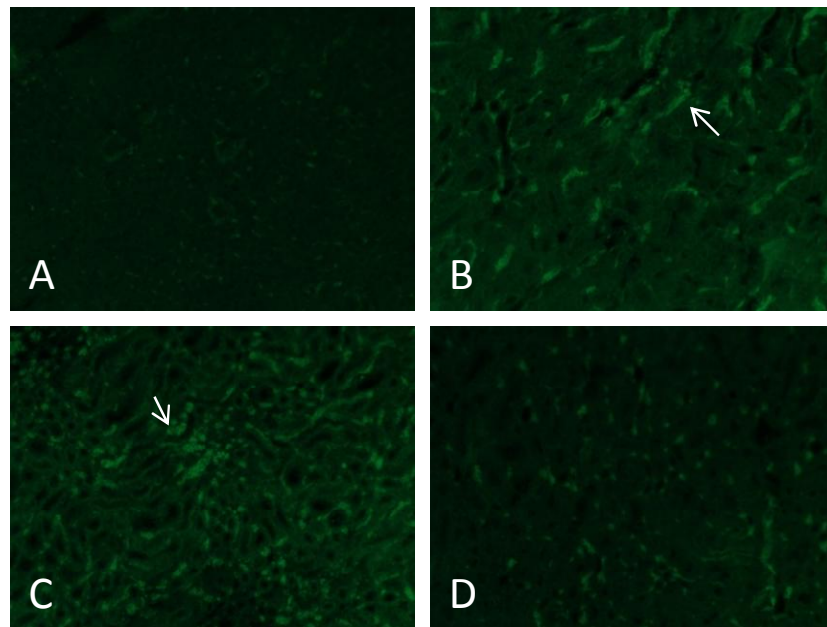


Fig. 7. Immunodetection of TGF- β 1 in kidney of control and treated rats. **A:** Control kidney. **B:** Kidney of animals treated with 25mg/kg/day CyA for 140 days. **C:** Kidney simultaneously treated with 25mg/kg/day CyA and 20mg/kg/day TMZ. **D:** Kidney pretreated for 20 days with TMZ and then simultaneously with CyA and TMZ for 120 days

Fig. 7D is similar to Fig. 7A, control.

We conclude that pretreatment with TMZ for 20 days followed by treatment with TMZ and CyA for 120 days prevents the increase in TGF- β 1.

The participation of MCP-1 in the kidney of control and treated rats was studied and is shown in Fig. 8.

Figs. 8B and 8C reveal the presence of the MCP-1 molecule in the kidney of rats treated with CyA, and in simultaneous treatment with TMZ and CyA respectively. Only kidneys from rats pretreated with 20 mg/kg/day TMZ for 20 days followed by simultaneous treatment with CyA and TMZ failed to reveal the presence of MCP-1, as shown in Fig. 8D. This image is similar to Fig. 8A.

From these results we concluded that pretreatment for 20 days with 20 mg/kg/day TMZ and its daily administration together with CyA is essential for protection against the toxicity of the immunosuppressant.

4. DISCUSSION

Immunosuppressants are drugs capable of causing side effects. Our previous works have

experimentally demonstrated nephrotoxicity and hepatotoxicity in treatment with Cyclosporin A using different doses and time periods [21,22].

Among the results of chronic treatment with CyA, interstitial fibrosis stands out, as shown in the images of histological slices of kidney of rats treated with CyA stained with hematoxylin-eosin (Fig. 1B) and later confirmed with Mallory's trichrome staining (Fig. 2B).

Chronic renal insufficiency progresses towards a final stage of renal fibrosis characterized by the accumulation of extracellular matrix in the glomerulus, glomerulosclerosis and in the tubule interstitial space, interstitial fibrosis. Several studies suggest that the severity of tubule interstitial fibrosis is correlated with the degree of renal damage caused and with the risk of progression [23].

The increase in Collagens type I, III and IV is related to the increase in cellularity by the proliferation and migration of fibroblasts and mononucleated cells.

Fig. 6B shows intense staining for Collagen I. We concluded that treatment with CyA for 140 days causes an increase in Collagen I evidenced by increased fluorescence.

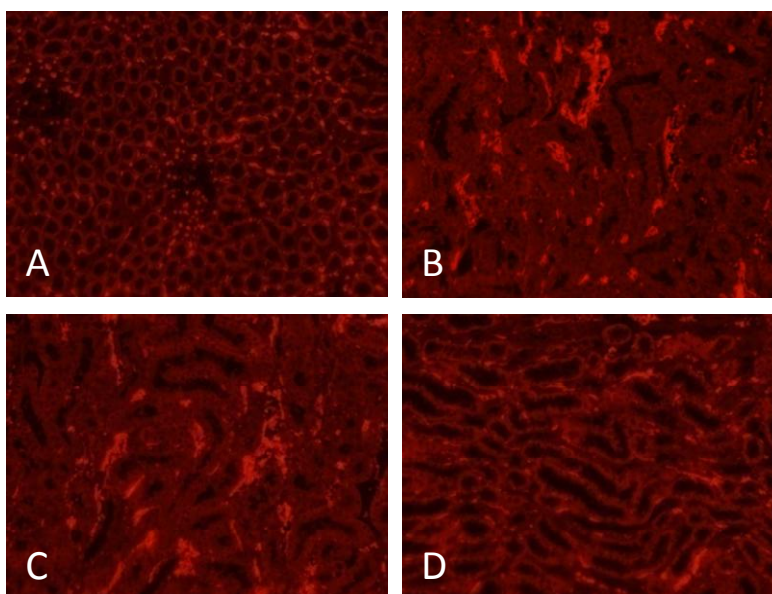


Fig. 8. Immunodetection of MCP-1 in kidney of control and treated rats. A: Control kidney. B: Kidney of animals treated with 25mg/kg/day CyA for 140 days. C: Kidney simultaneously treated with 25 mg/kg/day CyA and 20 mg/kg/day TMZ. D: Kidney pretreated with 20 mg/kg/day TMZ followed by 25 mg/kg/day CyA and 20 mg/kg/day TMZ for 120 days

Renal tubular cells are responsible for collagen production and accumulation in the basal membrane and in the interstitial the extracellular matrix. Besides, infiltrating macrophages and T-lymphocytes promote the production of fibroblasts, which are capable of producing collagen. This is a process regulated by molecules that stimulate their formation such as growth factors and others that regulate catabolism and regeneration. Normal and pathological physiological processes depend on this dynamic balance [24].

We observed that tubule interstitial fibrosis is a frequent complication in patients treated with Cyclosporine A. This increase in interstitial tissue is associated with an increase in Collagen I and TGF β 1.

The present work demonstrates that CyA causes epithelial cells to undergo transformation into fibroblast-type cells that are responsible for interstitial fibrosis at later stages.

Quantification of the accumulation of Collagen I was conducted by histomorphometric studies and verified by immunomarking with a specific antibody (Figs. 3B and 6B).

The morphometric study of fibrosis in treatment with doses of 25 mg/kg/day CyA for 140 days revealed 20% fibrosis in rat kidneys (Fig. 4).

The deterioration and loss of the renal function reported in transplant patients with a chronic treatment with CyA could be explained by our results.

In previous works we experimentally demonstrated the cytoprotective effect of TMZ against CyA-induced toxicity in rat kidneys [17,25].

We demonstrated that pretreatment for 20 days with 20 mg/Kg/day TMZ followed by simultaneous treatment with 20 mg/Kg/day TMZ and 25 mg/Kg/day CyA for 120 days preserves the histoarchitecture and the functionality of renal tubular cells (Fig. 4D).

Immunostaining assays with specific antibodies for Collagen I revealed that animals pretreated with TMZ and then with TMZ plus CyA did not show Collagen I expression (Fig. 6D)

Other authors have described the expression of molecules in the tubular interstitial such as

transforming growth factor- β (TGF- β) or signaling pathway TGF- β 1 [26].

Figs. 7B and 7C show the presence of TGF- β 1 in the chronic treatment with CyA and in the simultaneous treatment with CyA and TMZ. Fig. 7D, which corresponds to the group of animals pretreated for 20 days with TMZ and then with TMZ and CyA for 120 days, does not show expression of TGF- β 1, the image being identical to the one corresponding to the control group (Fig. 7A).

These results led us to investigate the initiation of the fibrotic process through the monocyte chemoattractant protein-1 (MCP-1) using the immunolabeling technique with specific antibodies.

Figs. 8B and 8C show the presence of MCP-1 in animals treated with CyA for 120 days and in those simultaneously treated with TMZ and CyA, respectively. No MCP-1 expression was observed in control animals or in those previously treated with TMZ for 20 days and then with CyA and TMZ (Figs. 8A and 8D).

These data suggest that CyA is a direct stimulus for the activation of the MCP-1 molecule located in the membranes of the proximal renal tubular cells.

Trimetazidine is a cytoprotective drug that counteracts metabolic disorders independently of hemodynamic effects. It is often used in cardiology. Inhibits fatty acid oxidation and indirectly favoring glucose oxidation to make oxygen utilization more efficient and so counteract hypoxia. In this way, it favors the formation of phospholipids and finally decreases oxidative stress. This results in a better functioning of different organs such as heart, kidney, liver, lung and brain [27].

In this work pretreatment with TMZ followed by incorporation into the immunosuppression scheme with CyA prevents the functional and structural changes caused by CyA demonstrated in our previous works [3].

The extracellular matrix plays a central role in toxicity caused by CyA. It acts on the membranes of the renal tubular cells, stimulating the production of MPC-1, profibrotic molecule.

On the basis of the experimental results obtained we can infer the mechanism through which TMZ prevents CyA-induced fibrosis.

TMZ inhibits 3-ketoacyl CoA thiolase and thus prevents the oxidation of fatty acids, favoring the oxidation pathway of glucose as an energy source.

TMZ is capable of redirecting fatty acid metabolism toward the formation of phospholipids, preserving the integrity of cell and mitochondrial membranes. So TMZ prevents the action of CyA on Complexes I and II of the Mitochondrial Respiratory Chain, which is the target of the toxic action of CyA as demonstrated by us [28].

5. CONCLUSION

In conclusion, TMZ prevents CyA-induced cytotoxicity, thus contributing to improve the quality of life of patients undergoing treatment with the immunosuppressant.

CONSENT

It is not applicable.

ETHICAL APPROVAL

Animal experiments were performed under the rules approved in the bioethics committee of the Faculty of Medicine of the National University of Tucuman.

ACKNOWLEDGMENTS

The authors acknowledge financial support from Secretaria de Ciencia y Técnica (Science and Technique Department) of the Universidad Nacional de Tucuman under Grant no. PIUNT 26/D 422.

COMPETING INTERESTS

Authors have declared that no competing interests exist.

REFERENCES

1. Kanwar YS, Wadw J, Sun L, Xie P, Wallner EL, Chen S, Chugh S, Danesh FR. Diabetic nephropathy: Mechanisms of renal disease progression. *Exp Biol Med.* 2008;233:4-11.
2. Ismail MH, Pinzani M. Reversal of liver fibrosis. *Saudi J Gastroenterol.* 2009;15(1): 72-79.
3. De la Cruz Rodríguez LC, Posleman SE, Araujo CR, Rey M del R. Alteraciones morfofuncionales en riñón e hígado de ratas. Un tratamiento crónico con ciclosporina A. *B y PC.* 2012;74(3):10-18.
4. Myllyharju J, Kivirikko KI. Collagens and collagen-related diseases. *Ann Med.* 2001; 33:7-21.
5. De la Cruz Rodríguez de Dantur, Rey MR, Posleman SE, Araujo CR. El Oxido Nitrico en la Nefrotoxicidad Experimental por Ciclosporina A. *Acta Bioquin Clin Latinoam.* 2005;39(1):5-10.
6. Shui HA, Ka SM, Lin JC, Jin JS, Feng Y, Sheu LF, Chen A. Fibronectin in blood involves the development of focal segmental glomerulosclerosis in mouse model. *Nephrol Dial Trasplant.* 2006;21: 1794-1802.
7. Guo J, Friedman SL. Hepatic fibrogenesis. *Semin Liver Dis.* 2007;27:413-426.
8. Kisseleva T, Brenner DA. Mechanisms of fibrogenesis. *Exp Biol Med (Maywood).* 2008;233:109-122.
9. Gressner AM, Weiskirchen R, Breikopf K, Dooley S. Roles of TGFβ in hepatic fibrosis. *Front Biosci.* 2002;7:d793-d807.
10. Gressner AM, Weiskirchen R. Modern pathogenetic concepts of liver fibrosis suggest stellate cells and TGFβ as major players and therapeutic targets. *J Cell Mol Med.* 2006;10:76-99.
11. Gressner AM. Hepatic fibrogenesis: the puzzle of interacting cells, fibrogenic cytokines, regulatory loops and extracellular matrix molecules. *Z Gastroenterol.* 1992;30(1):5-16.
12. Marra F, Valente AJ, Pinzani M, Abboud HE. Cultured human liver fat-storing cells produce monocyte chemotactic protein-1. Regulation by proinflammatory cytokines. *J Clin Invest.* 1993;92(4):1674-1680.
13. Rubtsov YP, Rudensky AY. TGF beta signaling in control of T cell-mediated self-reactivity. *Nat Rev Immunol.* 2007;7:443-453.
14. Wineau F, Quack C, Darmaise A, Stefan HE Kaufmann. Starring stellate cells in liver immunology. *Current Opinion in Immunology.* 2008;20:68-74.
15. Friedman SL. Liver fibrosis-from bench to bedside. *J Hepatol.* 2003;38:s38-53.
16. Batailler R, Brenner DA. Liver fibrosis. *J Clin Invest.* 2005;115(2):209-218.
17. De la Cruz Rodríguez LC, Araujo CR, Posleman SE, Rey MR. Attenuation of gentamicina-induced nephrotoxicity:

- Trimetazidine versus N-acetyl cysteine. J Appl Toxicol. 2010;30:343-353. ISSN 1099-1263.
18. De la Cruz Rodríguez LC, Rey María del R. Araujo CR, Oldano Ana V. On the Performance of Trimetazidine and vitamin e as pharmacoprotection agents in cyclosporin a induced toxicity. ISRN Pharmacology Vol; 2013.
 19. Martoja R, Martoja-Pierson M. Tecnicas de histología Animal. Toray-Masson S. A. Barcelona. 1954;350-365.
 20. Lynch J, Raphahael S, Mellor D, Spare P, Inwood M. Métodos de Laboratorio. Nueva Editorial Interamericana: México. Cap. 1977;46:1300-1309.
 21. De la Cruz Rodríguez de Dantur LC, Del Sanzio EE, Posleman SE y cols. Nefrotoxicidad por Ciclosporina A evaluada mediante la gama glutamil transpeptidasa urinaria. Nefrol Latinoam. 1996;3(4):300-305.
 22. De la Cruz Rodríguez LC, Posleman SE, Araujo CR, Rey M del R. Hepatotoxic effect of cyclosporine A in the mitochondrial respiratory Chain. J. Appl. Toxicol. 2007;26:310-317.
 23. Bohle A, Müller GA, Wermann M, Mackensen-Haen S, XiaoJ C. Phatogenesis of chronic renal failure in the primary glomerulopathies, renal vasculopathies and chronic interstitial nephritides. Kidney Int. 1996;54:52-59.
 24. Mc Morrow T, Gaffney MM, Slattery C, Campbell E, Ryan MP. La ciclosporina A transición epitelio-mesénquima inducida en células epiteliales tubulares proximales renales humanas. Nephrol Dial Transplant. 2005;20:2215-25.
 25. De la Cruz Rodríguez LC, Araujo CR, Posleman SE, Rey M del R. Efecto de Trimetazidina en la nefrotoxicidad por Gentamicina. Acta Bioquim Clin Latinoam. 2009;43:601-610.
 26. Lopez-Novoa JM, Quiros Y, Vicente L, Morales AI, Lopez-Hernandez FJ. New insights into the mechanism of aminoglycoside nephrotoxicity: An integrative point of view. Kidney Int. 2011; 79(1):33-45.
 27. Belardinelli R, Solenghi M, Volpe L. Trimetazidine improves endothelial dysfunction in chronic heart failure: An antioxidant effect. European Heart Journal. 2007;28(9):1102-8.
 28. Araujo CR, de la Cruz Rodríguez de Dantur C, Posleman Sara E. Rey María del R. Efecto del tratamiento crónico con Ciclosporina A sobre la respiración mitocondrial en hepatocitos. Bioquímica y Patología Clínica. 2005;69:5-13. ISSN 1515-6761.

© 2015 Cristina et al.; This is an Open Access article distributed under the terms of the Creative Commons Attribution License (<http://creativecommons.org/licenses/by/4.0>), which permits unrestricted use, distribution, and reproduction in any medium, provided the original work is properly cited.

Peer-review history:

The peer review history for this paper can be accessed here:

<http://www.sciencedomain.org/review-history.php?iid=1177&id=14&aid=9466>