



# **Morphometric Analysis and Variation of Pterion, Asterion and Lambda in Dry Human Skulls and Its Sexual Dimorphism**

**Sadhana Karunakaran<sup>a</sup> and Karthik Ganesh Mohanraj<sup>b\*#</sup>**

<sup>a</sup> Saveetha Dental College and Hospitals, Saveetha Institute of Medical and Technical Sciences (SIMATS), Saveetha University, Chennai-600077, Tamil Nadu, India.

<sup>b</sup> Department of Anatomy, Saveetha Dental College and Hospitals, Saveetha Institute of Medical and Technical sciences (SIMATS), Saveetha University, Chennai-600077, Tamil Nadu, India.

## **Authors' contributions**

*This work was carried out in collaboration between both authors. Both authors read and approved the final manuscript.*

## **Article Information**

DOI: 10.9734/JPRI/2021/v33i60B34735

## **Open Peer Review History:**

This journal follows the Advanced Open Peer Review policy. Identity of the Reviewers, Editor(s) and additional Reviewers, peer review comments, different versions of the manuscript, comments of the editors, etc are available here: <https://www.sdiarticle5.com/review-history/78876>

**Original Research Article**

**Received 25 October 2021**

**Accepted 20 December 2021**

**Published 23 December 2021**

## **ABSTRACT**

**Introduction:** Pterion is a H- shaped sutural junction of the frontal, parietal, squamous part of the temporal and greater wing of sphenoid bone. Asterion is a sutural junction of lambdoid, parietomastoid and occipitomastoid sutures. Lambda is the junction where lambdoid sutures and sagittal sutures meet. These sutures play an important role in infants' brain development. Flexibility of these allows the bones to overlap and hence it can pass through the brain canal easily without any damage to the brain.

**Aim:** To analyse pterion asterion and lambda of dry human skulls morphologically and morphometrically and determine its sexual dimorphism.

**Materials and Methods:** 40 dry human skulls were collected from the department of Anatomy of Saveetha dental college and hospitals. By excluding abnormal and damaged skulls, 20 skulls were studied. Out of 20 skulls, 11 were male skulls and 9 were female skulls. On investigation, Pterion was classified into four types: Sphenoparietal, stellate, Epipteric and Frontotemporal. Asterion was classified into types: Type-1 and Type-2 based on the presence and absence of wormian bones respectively. Lambda was classified into two types: Normal and Abnormal. Statistical analysis was done by SPSS software. Paired Sample T test was used to analyse the data.

<sup>#</sup>Assistant Professor;

<sup>\*</sup>Corresponding author: E-mail: karthikm.sdc@saveetha.com;

**Results:** Percentage of occurrence of different types of pterion in males and females: Sphenoparietal (59.09 % of males and 59.09 % of females), Stellate (27.7% of males and 22.2% of females), Epipteris (99% of males and 16.6% of females) and Frontotemporal (45.5% of males and 5.5% of females). Different types of Asterion: Type-1 (13.63% of males and 16.66 % of females and Type -2 (86.63% of males and 83.33% of females). Different types of Lambda: Normal (90.9% of males and 94.4% of females), Abnormal (9% of males and 5.55% of females).

**Conclusion:** In the present study, there was no correlation between the male and female skulls in the presence of Pterion, Asterion and Lambda. Therefore these cannot be used as reliable parameters for determining sexual dimorphism.

*Keywords: Pterion; asterion; lambda; sutures; sexual dimorphism.*

## 1. INTRODUCTION

Pterion is a H- shaped sutural junction of the frontal, parietal, squamous part of the temporal and greater wing of sphenoid bone. Pterion is also referred to as “Anterolateral fontanelle” in infants. It closes 2-3 months after birth. Sutural bone present in the pterion region is called “Pterion ossicle” or “Epipteris bones”. Pterion is a fragile point that could be fractured easily because the calvarias wall is thin. Pterion overlies the anterior branch of the middle meningeal artery and lateral fissure of the cerebral hemisphere. Hence, damage to this point might lead to extradural hematoma [1]. The anatomical position of the pterion is important for surgical management of extradural hemorrhage, brain tumors, aneurysms located in the anterior and middle cranial fossae [2-5].

Asterion is the junction of the mastoid part of temporal, parietal and occipital bones. It serves as an important surgical landmark for the posterior cranial fossa, corresponding to the location of the transverse sinus and is also a surface landmark for anthropological and radiological measurements of the skull [6-8]. Asterion is referred to as “Posterolateral fontanelle” in infants. It closes at 12 months after birth.

Lambda is the meeting point of sagittal and lambdoid sutures. It is known as “posterior fontanelle” in infants. It closes at 2-3 months after birth. The wormian bones present in this suture are called “Inca bone” [9]. Lambda is a landmark or craniometric point for radiological and anthropological measurements. Our team has extensive knowledge and research experience that has translated into high quality publications [10–29]. The aim of this study is to determine sexual dimorphism of dry human skulls using pterion, asterion and lambda as a reliable criteria.

## 2. MATERIALS AND METHODS

40 dry human skulls were collected from the Department of Anatomy of Saveetha dental college and hospitals, Chennai. By excluding abnormal and broken skulls, 20 skulls were selected for this study. 20 skulls were classified as skulls, 11 male skulls and 9 female skulls using various parameters. On investigation, Pterion was classified into four types: Sphenoparietal, stellate, Epipteris and Frontotemporal [30]. Asterion was classified into types: Type-1 and Type-2 based on the presence and absence of wormian bones respectively [31]. Lambda was classified into two types: Normal and Abnormal. Statistical analysis was done using SPSS software version 23.0. Paired Sample T test was used to analyse the data.

## 3. RESULTS AND DISCUSSION

Male skulls were 11 and female skulls were 9, out of 20 skulls analyzed. From the obtained data the percentage was calculated for comparison between male and female. Percentage of occurrence of different types of pterion in males and females: Sphenoparietal (59.09 % of males and 59.09 % of females), Stellate (27.7% of males and 22.2% of females), Epipteris (99% of males and 16.6% of females) and Frontotemporal (45.5% of males and 5.5% of females). Different types of Asterion: Type-1 (13.63% of males and 16.66 % of females and Type -2 (86.63% of males and 83.33% of females). Different types of Lambda: Normal (90.9% of males and 94.4% of females), Abnormal (9% of males and 5.55% of females).

### 3.1 Discussion

In the study done by Natis K et al., [32], 90 skulls were selected and on investigation, pterion were classified into four types and the percentages of occurrence of each type of pterion was obtained:

Sphenoparietal (58%), Stellate (25%), Epipteric (15.5%) and Frontotemporal (1.1 %) and no sexual dimorphism was determined. In the present study, the occurrence percentage obtained for Sphenoparietal was 59.09% of males and 55.55% of females, Stellate was 27.27% of males and 22.2% of females, Epipteric was 9% of males and 16.6% of females and Frontotemporal was 4.5% of males and 5.5% of females. The percentage of types of pterion between male and female is shown in Table 1.

**Table 1. Shows the percentage (%) of types of pterion between male and female**

Types of pterion	Male	Female
Sphenoparietal	59.09%	55.5%
Stellate	27.75 %	22.2%
Epipteric	09.0%	16.6%
Frontotemporal	45.5%	5.5%

In the study done by [33] 20 skulls were selected and on investigation asterion was classified into 2 types and percentage of occurrence of each type of asterion was obtained: Type-1 (Presence of wormian bones) 18.25% of males and 20.59% of females and Type -2 (Absence of wormian bones) 81.75% of males and 79.41% of females. The percentage of types of asterion between

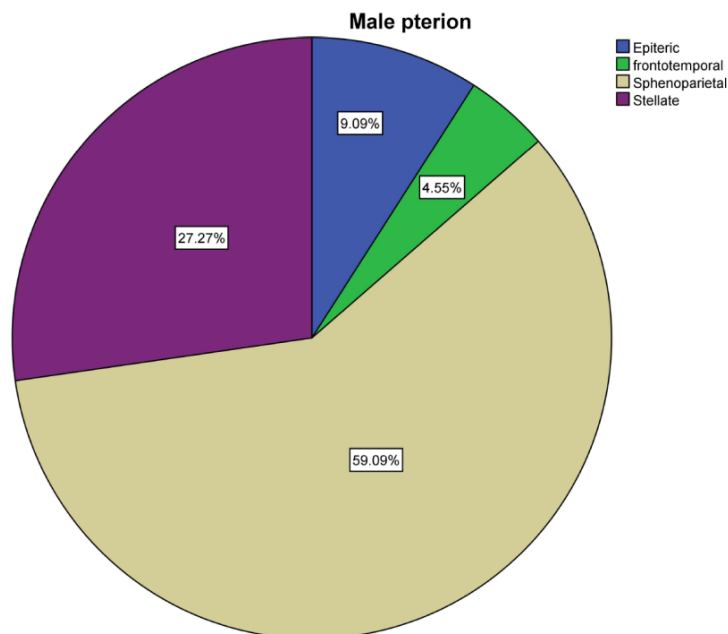
male and female is shown in Table 2. In the present study, the occurrence percentages obtained for Type-1 was 13.63% of males and 16.6% of females, Type -2 was 86.6% of males and 83.33% of females. In the study done by [34,35], 302 skulls were selected and on investigation lambda was classified into two types percentage of occurrence of each type of lambda was obtained: normal lambda (92.7% of males and 96.1% of females ) and abnormal lambda (7.3% of males and 3.9% of females). The percentage of types of lambda between male and female is shown in Table 3.

**Table 2. Shows the percentage (%) of types of asterion between male and female**

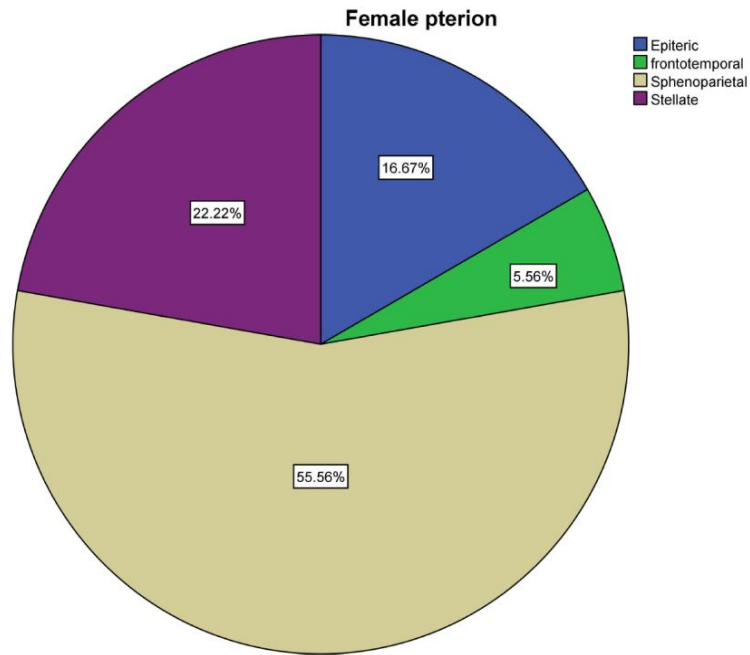
Types of asterion	Male	Female
Type -1	13.63 %	16.66%
Type-2	86.36%	83.33%

**Table 3. Shows the percentage (%) of types of lambda between male and female**

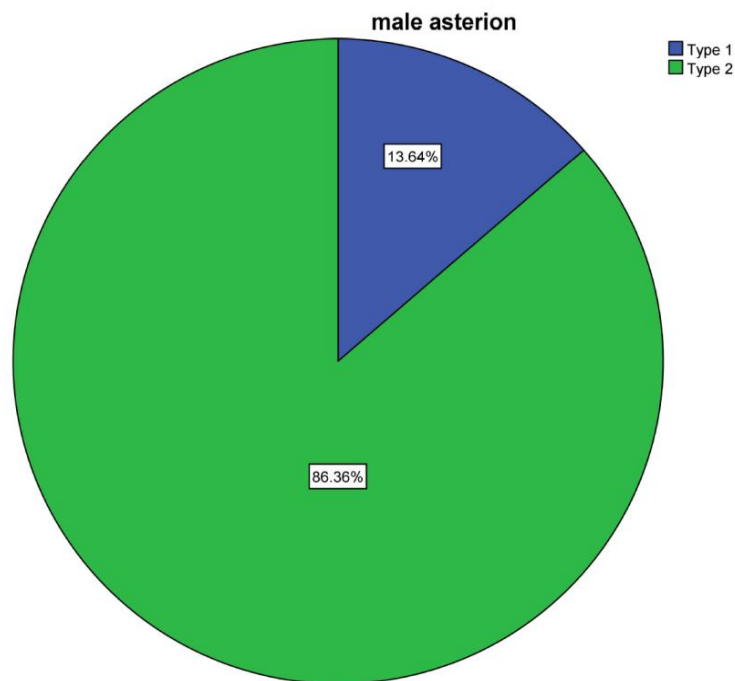
Types of lambda	Male	female
Normal	90.9%	94.4%
Abnormal	09.0%	5.55%



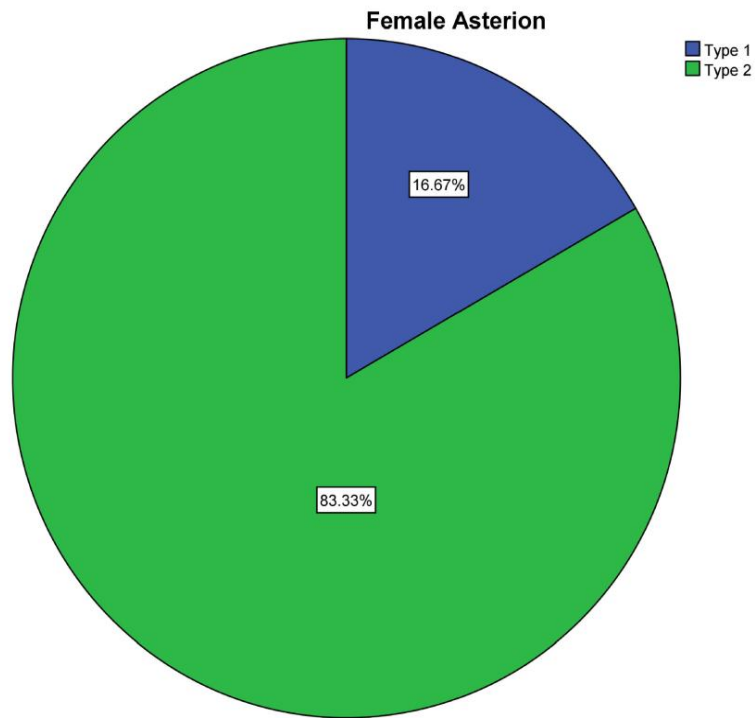
**Fig. 1. Pie chart represents the percentages of different types of pterion present in male skulls: 59% of the skulls is found to possess sphenoparietal pterion (grey color), 27.27% of the skulls is found to possess stellate pterion (purple color), 9.09% of the skulls is found to possess epipteric pterion (Blue color) and 4.55% of the skulls is found to possess frontotemporal pterion (Green color)**



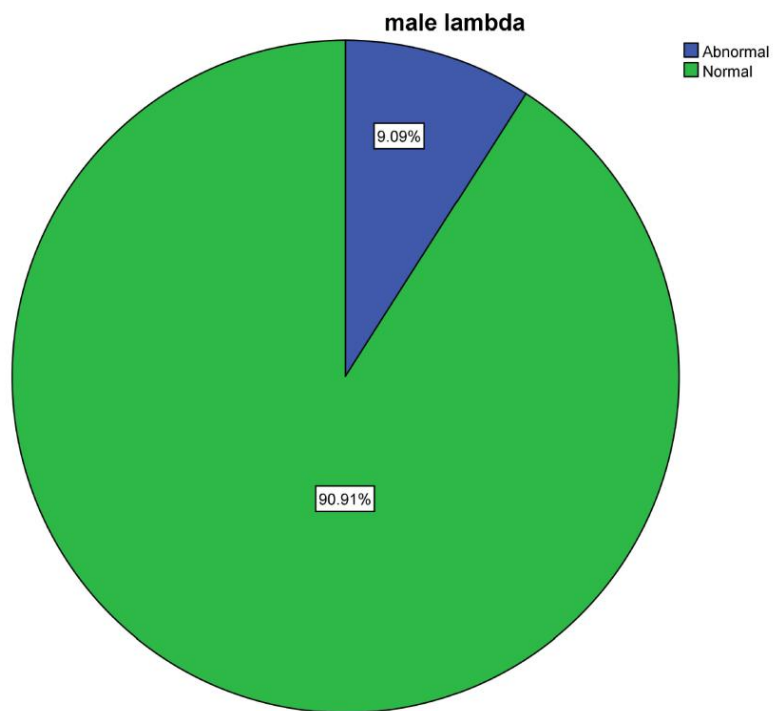
**Fig. 2.** Pie chart represents the percentages of different types of pterion present in female skulls: 55.56% of the skulls is found to possess sphenoparietal pterion (grey color), 22.22% of the skulls is found to possess stellate pterion (purple color), 16.67% of the skulls is found to possess epipteric pterion (blue color) and 5.56% of the skulls is found to possess frontotemporal pterion (green color)



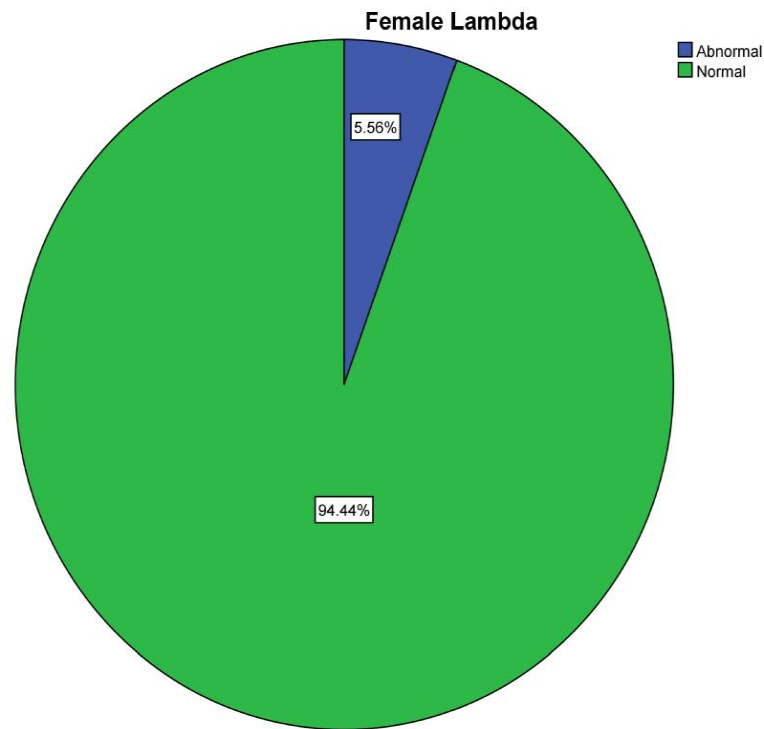
**Fig. 3.** Represents the percentages of different types of asterion present in male skulls: 86.36% of the skulls are found to possess type 2 asterion (green color) and 13.64% of the skulls is found to possess type 1 asterion (blue color)



**Fig. 4. Represents the percentages of different types of asterion present in female skulls: 83.33% of the skulls are found to possess type 2 asterion (Green color) and 16.67% of the skulls is found to possess type 1 asterion (Blue color)**



**Fig. 5. Represents the percentages of different types of lambda present in male skulls: 90.91% of skulls are found to possess normal lambda (Green color) and 9.09% of the skulls are found to possess abnormal lambda (Blue color)**



**Fig. 6. Represents the percentages of different types of lambda present in female skulls: 94.44% of skulls are found to possess normal lambda (Green color) and 5.56% of the skulls are found to possess abnormal lambda (Blue color)**

In the present study, the occurrence percentage obtained for normal lambda was 90.9% of males and 94.4% of females and for abnormal lambda 9.09% of males and 5.55% of females.

The anatomical location of the presence of pterion, asterion and lambda are necessary for the surgical management of the region concerned and the brain areas involved. The variations in the presence or morphological alterations can provide a clue for the neurosurgeons to take precautions on the changes that occurred and can implement their altered surgical approach if needed. The variations between the male and female skulls with asterion, pterion and lambda shape and presence can also be very much useful in the neurosurgical approaches between the genders creating anatomical knowledge on these structures concerned.

#### 4. CONCLUSION

In the present study, there was no correlation between male and female skulls with asterion, pterion and lambda. Therefore these are not

reliable parameters for determining sexual dimorphism.

#### 5. LIMITATIONS

The present study is inconsistent due to less number of skulls available. The study was conducted and completed in a short span of time.

#### FUTURE SCOPE

Further studies can be done with more number of skulls in order to obtain significant results and to get a clear idea about the subject.

#### CONSENT

It is not applicable.

#### ETHICAL APPROVAL

As per international standard or university standard written ethical approval has been collected and preserved by the author(s).

#### ACKNOWLEDGEMENT

I thank Saveetha Dental College for providing all research facilities in carrying out this study.

## COMPETING INTERESTS

Authors have declared that no competing interests exist.

## REFERENCES

1. Sindel A, Dt., Professor A, Department of Oral and Maxillofacial Surgery, Faculty of Dentistry, Akdeniz University, et al. Morphometric Study of Pterion [Internet]. International Journal of Anatomy and Research. 2016;04:1954–7. Available:<http://dx.doi.org/10.16965/ijar.2016.119>
2. Nayak G, Mohanty BB, Das SR. Morphometric study of pterion and its clinical significance [Internet]. Asian Journal of Pharmaceutical and Clinical Research. 2017;10:142. Available:<http://dx.doi.org/10.22159/ajpcr.2017.v10i10.19138>
3. Kumar D, Head AP&., Department of Physical Medicine and Rehabilitation, ANIIMS, Blair P, Islands AAN, et al. Study of Anatomical Types of Pterion for Pterional Surgical Approach [Internet]. Recent Advances in Pathology & Laboratory Medicine. 2019;05:14–6. Available:<http://dx.doi.org/10.24321/2454.8642.201916>
4. Aydin ME, Kopuz C, Demir MT, Çorumlu U, Kaya AH. Localization of pterion in neonatal cadavers: A morphometric study [Internet]. Vol. 32, Surgical and Radiologic Anatomy. 2010. p. 545–50. Available:<http://dx.doi.org/10.1007/s00276-009-0615-7>
5. A Morphometric Study of Pterion for Neurosurgical Procedures [Internet]. International Journal of Pharmaceutical Research. 2020;12. Available:<http://dx.doi.org/10.31838/ijpr/2020.12.01.352>
6. Dutt V, MBBS, Ramaiah Medical College, Bangalore, Karnataka, India., et al. Morphometric study of pterion and asterion in adult human skulls of indian origin [Internet]. International Journal of Anatomy and Research. 2017;05:3837–42. Available:<http://dx.doi.org/10.16965/ijar.2017.198>
7. Day JD, Diaz Day J, Tschabitscher M. Anatomic Position of the Asterion [Internet]. Neurosurgery. 1998;42:198–9. Available:<http://dx.doi.org/10.1097/00006123-199801000-00045>
8. Deepak S, Dakshayani KR. Morphometric features of asterion in adult human skulls [Internet]. International Journal of Research in Medical Sciences. 2015;1325–8. Available: <http://dx.doi.org/10.18203/2320-6012.ijrms20150140>
9. T.m VK, M VKT, Tutor in the Department of Anatomy, Chirayu Medical College, Bairagarh, Bhopal, et al. The occurrence of wormian bones within the cranial sutures and their clinical significance [Internet]. International Journal of Anatomy and Research. 2016;4:3082–6. Available:<http://dx.doi.org/10.16965/ijar.2016.408>
10. Sekar D, Lakshmanan G, Mani P, Biruntha M. Methylation-dependent circulating microRNA 510 in preeclampsia patients. Hypertens Res. 2019;42(10):1647–8.
11. Princeton B, Santhakumar P, Prathap L. Awareness on Preventive Measures taken by Health Care Professionals Attending COVID-19 Patients among Dental Students. Eur J Dent. 2020;14(S 01):S105–9.
12. Logeshwari R, Rama Parvathy L. Generating logistic chaotic sequence using geometric pattern to decompose and recombine the pixel values. Multimed Tools Appl. 2020;79(31-32):22375–88.
13. Johnson J, Lakshmanan G, M B, R M V, Kalimuthu K, Sekar D. Computational identification of MiRNA-7110 from pulmonary arterial hypertension (PAH) ESTs: a new microRNA that links diabetes and PAH. Hypertens Res. 2020;43(4):360–2.
14. Paramasivam A, Priyadharsini JV, Raghunandhakumar S, Elumalai P. A novel COVID-19 and its effects on cardiovascular disease. Hypertens Res. 2020;43(7):729–30.
15. Pujari GRS, Subramanian V, Rao SR. Effects of Celastrus paniculatus Willd. and Sida cordifolia Linn. in Kainic Acid Induced Hippocampus Damage in Rats. Ind J Pharm Educ. 2019;53(3):537–44.
16. Rajkumar KV, Lakshmanan G, Sekar D. Identification of miR-802-5p and its involvement in type 2 diabetes mellitus. World J Diabetes. 2020;11(12):567–71.
17. Ravisankar R, Jayaprakash P, Eswaran P, Mohanraj K, Vinitha G, Pichumani M. Synthesis, growth, optical and third-order nonlinear optical properties of glycine sodium nitrate single crystal for photonic

- device applications. *J Mater Sci: Mater Electron*. 2020;31(20):17320–31.
18. Wu S, Rajeshkumar S, Madasamy M, Mahendran V. Green synthesis of copper nanoparticles using *Cissus vitiginea* and its antioxidant and antibacterial activity against urinary tract infection pathogens. *Artif Cells Nanomed Biotechnol*. 2020;48(1):1153–8.
  19. Vikneshan M, Saravanakumar R, Mangaiyarkarasi R, Rajeshkumar S, Samuel SR, Suganya M, et al. Algal biomass as a source for novel oral nano-antimicrobial agent. *Saudi J Biol Sci*. 2020;27(12):3753–8.
  20. Alharbi KS, Fuloria NK, Fuloria S, Rahman SB, Al-Malki WH, Javed Shaikh MA, et al. Nuclear factor-kappa B and its role in inflammatory lung disease. *Chem Biol Interact*. 2021;345:109568.
  21. Rao SK, Kalai Priya A, Manjunath Kamath S, Karthick P, Renganathan B, Anuraj S, et al. Unequivocal evidence of enhanced room temperature sensing properties of clad modified Nd doped mullite Bi<sub>2</sub>Fe<sub>4</sub>O<sub>9</sub> in fiber optic gas sensor [Internet]. *Journal of Alloys and Compounds*. 2020; 838:155603. Available:<http://dx.doi.org/10.1016/j.jallcom.2020.155603>
  22. Bhavikatti SK, Karobari MI, Zainuddin SLA, Marya A, Nadaf SJ, Sawant VJ, et al. Investigating the Antioxidant and Cytocompatibility of *Mimusops elengi* Linn Extract over Human Gingival Fibroblast Cells. *Int J Environ Res Public Health* [Internet]. 2021;18(13). Available:<http://dx.doi.org/10.3390/ijerph18137162>
  23. Marya A, Karobari MI, Selvaraj S, Adil AH, Assiry AA, Rabaan AA, et al. Risk Perception of SARS-CoV-2 Infection and implementation of various protective measures by dentists across various countries. *Int J Environ Res Public Health* [Internet]. 2021;18(11). Available:<http://dx.doi.org/10.3390/ijerph18115848>
  24. Barma MD, Muthupandiyani I, Samuel SR, Amaechi BT. Inhibition of *Streptococcus mutans*, antioxidant property and cytotoxicity of novel nano-zinc oxide varnish. *Arch Oral Biol*. 2021;126:105132.
  25. Vijayashree Priyadharsini J. In silico validation of the non-antibiotic drugs acetaminophen and ibuprofen as antibacterial agents against red complex pathogens. *J Periodontol*. 2019;90(12):1441–8.
  26. Priyadharsini JV, Vijayashree Priyadharsini J, Smiline Girija AS, Paramasivam A. In silico analysis of virulence genes in an emerging dental pathogen *A. baumannii* and related species [Internet]. *Archives of Oral Biology*. 2018;94: 93–8. Available:<http://dx.doi.org/10.1016/j.archoralbio.2018.07.001>
  27. Uma Maheswari TN, Nivedhitha MS, Ramani P. Expression profile of salivary micro RNA-21 and 31 in oral potentially malignant disorders. *Braz Oral Res*. 2020;34:e002.
  28. Gudipaneni RK, Alam MK, Patil SR, Karobari MI. Measurement of the Maximum Occlusal Bite Force and its Relation to the Caries Spectrum of First Permanent Molars in Early Permanent Dentition. *J Clin Pediatr Dent*. 2020;44(6):423–8.
  29. Chaturvedula BB, Muthukrishnan A, Bhuvaraghan A, Sandler J, Thiruvengkatachari B. *Dens invaginatus*: a review and orthodontic implications. *Br Dent J*. 2021;230(6):345–50.
  30. Adejuwon SA, Olopade FE, Bolaji M. Study of the location and morphology of the pterion in adult nigerian skulls. *ISRN Anat*. 2013;2013:403937.
  31. Singh R. Incidence of Sutural Bones at Asterion in Adults Indians Skulls [Internet]. *International Journal of Morphology*. 2012;30:1182–6. Available: <http://dx.doi.org/10.4067/s0717-95022012000300066>
  32. Natsis K, Antonopoulos I, Politis C, Nikolopoulou E, Lazaridis N, Skandalakis GP, et al. Pterional variable topography and morphology. An anatomical study and its clinical significance [Internet]. *Folia Morphologica*; 2020. Available:<http://dx.doi.org/10.5603/fm.a2020.0113>
  33. Akkaşoğlu S, Farimaz M, Aktaş HA, Ocak H, Erdal ÖD, Sargon MF, et al. Evaluation of Asterion Morphometry in Terms of Clinical Anatomy [Internet]. *Eastern Journal of Medicine*. 2019;24:520–3. Available:<http://dx.doi.org/10.5505/ejm.2019.50480>
  34. Çalışkan S, Oğuz KK, Tunalı S, Aldur MM, Erçakmak B, Sargon MF. Morphology of cranial sutures and radiologic evaluation of the variations of intersutural bones [Internet]. *Folia Morphologica*; 2015.



- Available:<http://dx.doi.org/10.5603/fm.a2018.0030>
35. Mary DJ, Saveetha Dental College and Hospitals, Chennai, Karthik GM, Saveetha Dental College and Hospitals, Chennai. Incidence, number and laterality of epipteric bones in the pterion in dry human skulls of south india [Internet]. International Journal of Current Advanced Research. 2017;6:3198–200. Available:<http://dx.doi.org/10.24327/ijcar.2017.3200.0223>

© 2021 Karunakaran and Mohanraj; This is an Open Access article distributed under the terms of the Creative Commons Attribution License (<http://creativecommons.org/licenses/by/4.0>), which permits unrestricted use, distribution, and reproduction in any medium, provided the original work is properly cited.

*Peer-review history:*  
*The peer review history for this paper can be accessed here:*  
<https://www.sdiarticle5.com/review-history/78876>