



Sclerodermatomyositis Overlap Syndrome with Bullous Lesion: A Rare Presentation

**Meryem Elomari Alaoui ^{a*}, Amani Fliti ^a, Narjess Er-Rachdy ^a,
Mariame Meziane ^a, Nadia Ismaili ^a, Laila Benzekri ^a
and Karima Senouci ^a**

^a *Department of Dermatology and Venerology, University Hospital Center Ibn SINA, University Mohamed V, Rabat, Morocco.*

Authors' contributions

This work was carried out in collaboration among all authors. All authors read and approved the final manuscript.

Article Information

Open Peer Review History:

This journal follows the Advanced Open Peer Review policy. Identity of the Reviewers, Editor(s) and additional Reviewers, peer review comments, different versions of the manuscript, comments of the editors, etc are available here: <https://www.sdiarticle5.com/review-history/115214>

Case Study

Received: 07/02/2024

Accepted: 10/04/2024

Published: 16/04/2024

ABSTRACT

Overlap syndrome is diagnosed when at least two classical connective tissue diseases are observed in one patient, which develops simultaneously or sequentially. Sclerodermatomyositis (SDM) is one of the overlapping syndromes, defined by the association of dermatomyositis and scleroderma, which may be localized or systemic. The American College of Rheumatology European League against Rheumatism (ACR-EULAR) classification criteria are used to establish the diagnosis of systemic sclerosis and dermatomyositis. Clinically, this syndrome is characterized by the association of myalgia or myositis, arthralgia, with the skin changes of scleroderma, as well as Raynaud's phenomenon, interstitial lung disease, calcinosis, masked facies, dysphagia or esophageal dysmotility⁴, and immunologically, the presence of specific Pm/Scl antibodies in over 50% of cases. Rare cases in the literature have described this association, but not in its bullous form, which is why we report here on a patient with bullous sclerodermatomyositis.

*Corresponding author: E-mail: elomarim077@gmail.com;

Keywords: Sclerodermatomyositis; bullous; overlap syndrome; autoimmune condition.

1. INTRODUCTION

Sclerodermatomyositis overlap syndrome refers to a rare autoimmune condition characterized by features of both scleroderma (systemic sclerosis) and dermatomyositis [1].

Scleroderma and dermatomyositis are autoimmune diseases characterized by systemic involvement and significant morbidity. They are associated with a higher mortality rate than other connective tissue diseases, and can lead to a significant reduction in quality of life [2,3].

These overlapping syndromes can pose problems of diagnosis and treatment [4].

Scleroderma involves thickening and hardening of the skin and connective tissues, while dermatomyositis affects the skin and muscles, causing muscle weakness and skin rash [5].

Biological drugs, such as anti-TNF α or anti-CD20 monoclonal antibodies, have been used as alternative treatments in refractory cases. Furthermore, the use of anti-TNF agents in patients with systemic autoimmune diseases raises concerns due to the risk of triggering disease exacerbations [6,7].

Sclerodermatomyositis has rarely been reported in the literature, and cases of bullous presentation have not been described. We therefore present a case detailing this uncommon manifestation of sclerodermatomyositis.

2. CASE REPORT

The patient aged 48, with a 4-year history of Raynaud phenomenon, was admitted to the dermatology department because of the appearance of pruritic bullous skin lesions. These lesions are characterized by phases of flare-up and remission. In addition, the patient presented with significant weight loss and asthenia.

Clinical examination revealed a lilac-colored erythema on the eyelids, sparing the periphery of the lips and the nasolabial fold, and extensive, symmetrical, erythematous and purplish macules on the décolleté (V-shaped erythema), the posterior surface of the neck, the upper part of

the shoulders and the roots of the MS (shawl sign), as well as erythematous +/- scaly macules arranged in bands along the extensor tendon sheaths and strengthening opposite the MCP and IPP joints (Gottron sign). Extensive poikilodermal plaques were also noted on the upper trunk, with two sclerotic plaques on the thighs. In addition, several post-bullous erosions were found on the back, upper and lower limbs (Fig. 2).

Neuromuscular examination revealed global and segmental muscle weakness, as well as muscle deficits in the shoulder girdle, with difficulty in combing hair and reaching elevated objects, and in the pelvic girdle, with difficulty getting out of bed and a positive stool sign.

And the rest of the clinical examination was normal. Capillaroscopic examination showed mega capillaries with filiform hemorrhage as well as capillary rarefaction and presence of deserted beach (Fig. 2).

Laboratory examination revealed increased creatine kinase, aspartate aminotransferase, alanine aminotransferase, lactic dehydrogenase and aldolase, and immunological tests revealed positive anti-nuclear antibodies and PM-Scl antigen.

An electromyogram showed a scattered and multifocal myogenic abnormality of proximal muscularis with absence of motor and sensory nerve conduction abnormalities.

A skin biopsy showed hyperkeratosis, vacuolization of the basal keratinocytes, perivascular lymphocytic infiltrate, dermal fibrosis and subepidermal vesiculation.

Finally, the diagnosis of sclerodermatomyositis in its bullous form was retained.

The patient was treated with oral corticosteroids (1mg/kg/j) and methotrexate 15mg/week.

3. DISCUSSION

Sclerodermatomyositis, a rare autoimmune disorder, presents a complex clinical picture due to the combination of symptoms of scleroderma (systemic sclerosis) and dermatomyositis. This is what we call overlap syndrome, its prevalence among autoimmune diseases is 25% [8].

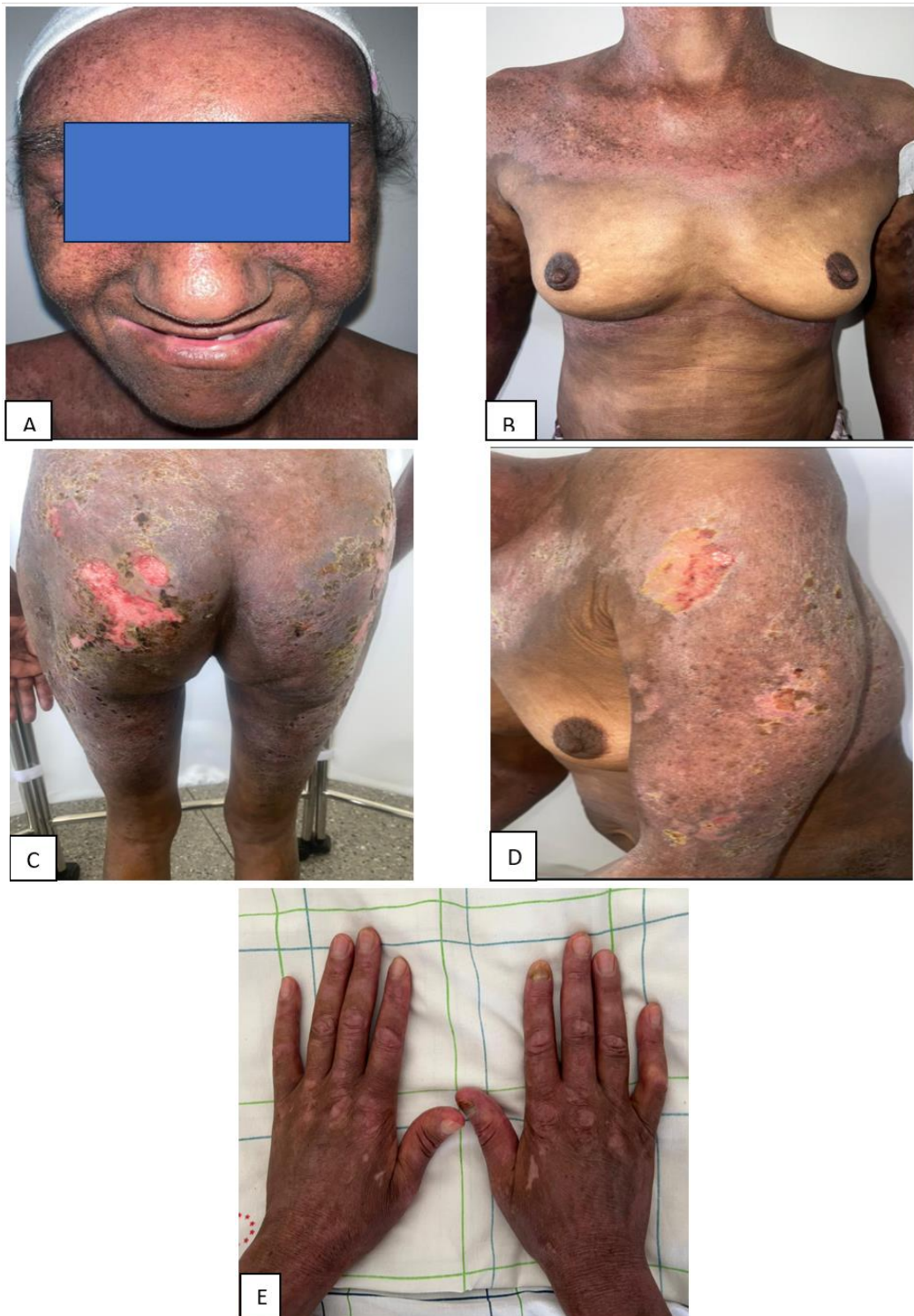

Fig. 1. A: A lilac-colored erythema on the eyelids. B: Extensive, symmetrical, erythematous and purplish macules on the décolleté (V-shaped erythema), and poikiloderma C,D: Several post-bullous erosions on the upper and lower limbs. E: Erythematous macules arranged in bands along the extensor tendon sheaths and strengthening opposite the MCP and IPP joints (Gottron sign)

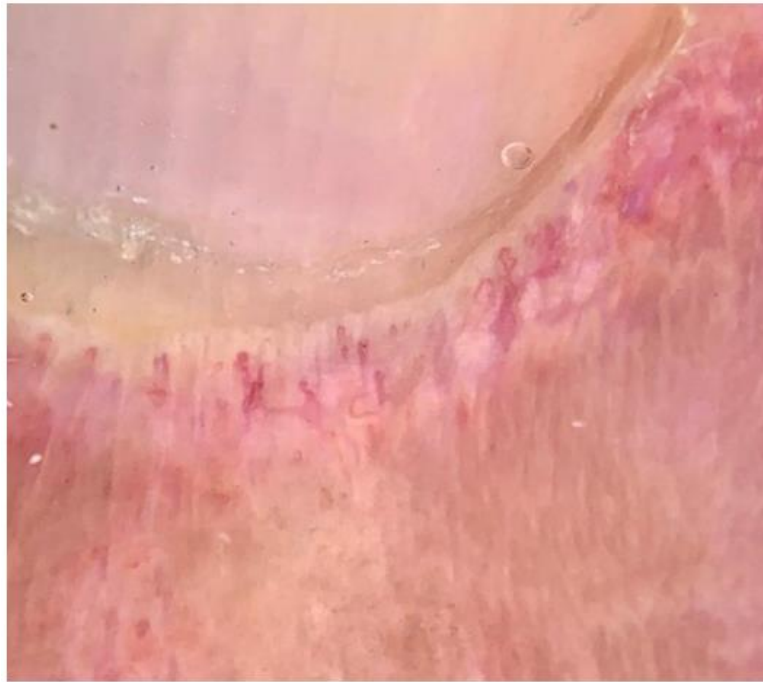


Fig. 2. Capillaroscopic showed mega capillaries, branched capillary with filiform hemorrhage as well as capillary rarefaction

This condition poses diagnostic and therapeutic challenges, as it combines features of skin thickening and hardening characteristic of scleroderma with muscle weakness and skin rash typical of dermatomyositis. It is usually affects adults, and it is rarely found in children [9].

The pathogenesis of sclerodermatomyositis remains elusive, but it is believed to involve dysregulation of the immune system, leading to inflammation and tissue damage in both the skin and muscles. Genetic predisposition, environmental factors, and potential viral triggers have been implicated in the development of this condition, although further research is needed to elucidate the precise mechanisms [10].

It clinically manifests with scleroderma-like skin changes, myalgia/myositis, Raynaud's phenomenon, dysphagia/esophageal hypomotility, interstitial lung disease [10-11]. Skin lesions are often associated with itching or burning sensations, following exposure to sunlight or ultraviolet light. Other dermatomyositis-type skin lesions have been described but are rarely observed, such as bullae and post-bullous erosions, as described in our patient's case [12]. The presence of bullae or blisters, as seen in bullous

sclerodermatomyositis, further complicates the clinical presentation and warrants careful evaluation.

The bullous form of sclerodermatomyositis is often associated with a high incidence of malignant tumours [13]. In our patient, however, the extension work-up revealed no associated tumours, but clinicians need to be aware of and vigilant for bullous forms of MDS.

The association of the clinical signs of dermatomyositis with the signs of scleroderma suggests this diagnosis and the immunological and biological work-up should be completed with a skin and muscle biopsy to confirm the diagnosis.

In terms of biological diagnosis, an antibody directed against the PM-Scl antigen is often found. It is a principal biological marker of sclerodermatomyositis, found in over 50% of patients with this syndrome, but the positivity and persistence of this marker is independent of disease activity and progression [1]. The Positive ANA may be found in 50-80% of dermatomyositis cases, particularly in patients with overlap syndrome such as sclerodermatomyositis [14,15]. Electromyography (EMG) may still be useful for confirming myogenic changes [16].

Possible differential diagnoses of sclerodermatomyositis include mixed connective tissue disease (MCTD) and Anti-Synthetase Syndrome (ASS). MCTD presents with combined features of Systemic Lupus Erythematosus (SLE), systemic sclerosis, Rheumatoid Arthritis (RA), dermatomyositis/ polymyositis, and a positive anti-U1-RNP antibody [17].

Therapeutic management of MDS relies primarily on non-steroidal anti-inflammatory drugs or oral corticosteroids. However, in cases of severe disease, i.e. associated pulmonary or arthritic involvement, aggressive treatment (immunosuppressive therapy, intravenous immunoglobulins) and rigorous follow-up may be proposed [10].

4. CONCLUSION

This case report highlights the rare presentation of overlap syndrome in the form of bullous sclerodermatomyositis, which is characterized by the association of dermatomyositis and scleroderma with bullous skin changes. While rare, it is important to recognize this association as it may present with specific clinical features such as myalgia, arthralgia, skin changes of scleroderma.

CONSENT

As per international standards or university standards, patient(s) written consent has been collected and preserved by the author(s).

ETHICAL APPROVAL

As per international standards or university standards written ethical approval has been collected and preserved by the author(s).

ACKNOWLEDGEMENTS

The authors thank all hospital staff and specialists for participation in this manuscript.

COMPETING INTERESTS

Authors have declared that no competing interests exist.

REFERENCES

1. Jablonska E, Chorzelski T, Blaszczyk M, Jarzabek-Chorzelska M, Kumar V, Beutner

- EH. Scleroderma/polymyositis overlap syndromes and their immunologic markers. *Clin Dermatol.* 1992;10(4):457-72. Review; PubMed.
2. Varga J. Disorders of immune-mediated injury: Systemic sclerosis (scleroderma) and related disorders. In: Jameson JL, Fauci AS, Kasper DL, et al. 20th edn. *Harrison's principle of internal medicine.* New York: McGraw-Hill, USA, 2546–2560; 2018.
3. Varga J. Clinical manifestations and diagnosis of systemic sclerosis (scleroderma) in adults. *Uptodate*; 2021.
4. Reddy H, Kashiv P, Kumar S, et al. Overlap of Scleroderma and Class V Lupus Nephritis: A Rare Autoimmune Confluence. *Cureus.* 2024;16(3):e56990. DOI: 10.7759/cureus.56990
5. Iorizzo LJ, Jorizzo JL. The treatment and prognosis of dermatomyositis: An updated review. *J Am Acad Dermatol.* 2008;59:99-112.
6. Laccarino L, Gatto M, Bettio S. et al. Overlap connective tissue disease syndromes. *Autoimmunity Reviews.* 2013; 12:363-373.
7. Balbir-Gurman A, Braun-Moscovici Y. Scleroderma Overlap Syndrome. *IMAJ* 2011;13:14-20
8. Jury EC, D'Cruz D, Morrow WJ. Autoantibodies and overlap syndromes in autoimmune rheumatic disease. *J Clin Pathol.* 2001;54:340-7.
9. Marcus M, Ilyas M, Tolaymat A. Childhood scleromyositis with a negative PM/Scl antibody. *Joint Bone Spine.* 2010;77: 73-5.
10. Febyani M, Purbo HD, Hamijoyo L et al. Sclerodermatomyositis. *Indon. J. Rheum.* 2011;3:32–36.
11. Ambade GR, Dhurat RS, Lade N, et al. Childhood sclerodermatomyositis with generalized morphea. *Indian. J. Dermatol. Venereol. Leprol.* 2008;74(2): 148–150.
12. Febyani M, Purbo DH, Hamijoyo L, Sutedja E, Suwarsa O, Sclerodermatomyositis, *Indonesian Journal of Rheumatology*; 2011.
13. Kubo M, Sato S, Kitahara H, Tsuchida T, Tamaki K. Vesicle formation in dermatomyositis associated with gynecologic malignancies. *Journal of the American Academy of Dermatology.* 1996;34(2):391–394. DOI: 10.1016/s0190-9622(07)80015-6

14. James WD, Berger TG, Elston DM, editors. Andrews' diseases of the skin clinical dermatology. 10th ed. Canada: Elsevier; 2006;166-77.
15. Nagaraju K, Lundberg IE. Inflammatory diseases of muscle and other myopathies. In: Firestein GS, Budd RC, Harris ED, Mcinnes IB, Ruddy S, Sergent JS, editors. Kelley's textbook of rheumatology. 8th ed. Philadelphia: Elsevier. 2009;1353-78.
16. Greenberg SA, Amato AA. Disorders of immune-mediated injury: Inflammatory myopathies. In: Jameson JL, Fauci AS, Kasper DL et al. 20th edⁿ. Harrison's principle of internal medicine. New York: McGraw-Hill, USA. 2018;2590– 2596.
17. Zenahbezu Abay, Nebiyu Bekele, et al Diagnosis of sclerodermatomyositis in Ethiopian woman, International Journal of Clinical Rheumatology. 2021;16(7).

© Copyright (2024): Author(s). The licensee is the journal publisher. This is an Open Access article distributed under the terms of the Creative Commons Attribution License (<http://creativecommons.org/licenses/by/4.0>), which permits unrestricted use, distribution, and reproduction in any medium, provided the original work is properly cited.

Peer-review history:

*The peer review history for this paper can be accessed here:
<https://www.sdiarticle5.com/review-history/115214>*