



Sequential Approach to Differential Diagnosis of TMJ Disorder from Other Oro Facial Muscles Pain – A Systematic Review

**Rajwinder Singh Brar¹, Anshu Singh², Nivedita Gautam³, Natasha Bathla⁴,
Jenny Lalmalsawmi Sailo⁴, Surbhi Abrol⁵ and Farhat Jabeen^{6*}**

¹*Department of Orthodontics, Rayat Bahara Dental College, SAS Nagar, Punjab, India.*

²*Awadh Dental College and Hospital, Jamsheedpur, India.*

³*Claremont Graduate University, USA.*

⁴*Department of Prosthodontics, Himachal Dental College, Sundernagar, India.*

⁵*Boston University, USA.*

⁶*Institute of Dental Sciences, Seorah, Jammu, India.*

Authors' contributions

This work was carried out in collaboration among all authors. Author RSB designed the study, performed the statistical analysis, wrote the protocol and wrote the first draft of the manuscript. Authors AS and NG managed the analyses of the study. Authors NB, JLS, SA and FJ managed the literature searches. All authors read and approved the final manuscript.

Article Information

DOI: 10.9734/JAMMR/2020/v32i1530604

Editor(s):

(1) Dr. Ashish Anand, GV Montgomery Veteran Affairs Medical Center & University of Mississippi Medical Center, USA.

Reviewers:

(1) Munir Khan, Khyber Medical University, Pakistan.

(2) Beldiman Maria-Antonela, Grigore T. Popa University of Medicine and Pharmacy, Romania.

Complete Peer review History: <http://www.sdiarticle4.com/review-history/61082>

Systematic Review Article

Received 27 June 2020

Accepted 01 September 2020

Published 05 September 2020

ABSTRACT

This systematic review (SR) synthesises recent evidence and assesses the methodological quality of published SRs in the Differential diagnosis of temporomandibular disorders (TMD). A systematic literature search was conducted in the PubMed, Cochrane Library, and Bandolier databases for 1987 to September 2019. Three investigators evaluated the methodological quality of each identified SR using two measurement tools: The assessment of multiple systematic reviews (AMSTAR) and level of research design scoring. Thirty-one SRs met inclusion criteria and 28 were analysed: 20 qualitative SRs and eight meta-analysis. The main aim of this article is to Differential diagnose the pain which is not related to any dental disease. Most of dental clinician have problem

*Corresponding author: E-mail: Farhatraza27@gmail.com;

to diagnose TMD (Temporomandibular Disorders) and Orofacial Muscle pain. The approach of this article is to simplify the differential diagnosis for better and fast treatment of the respective disease by classifying various TMJ related and muscle related problems.

Keywords: Temporomandibular disorder; orofacial pain; differential diagnosis; intra articular; extra articular disorder; headache; parafunctional habits; patient history.

1. INTRODUCTION

TMD is usually used as a 'general term' for Temporomandibular pain, Masticatory muscle pain and Orofacial pain [1]. In most of the cases TMJ is not responsible for pain usually it originate from the muscles of mastication rather than TMJ. The nomenclature for pain was uncertain for this pain hence for this reason American Dental Association has adopted the term 'Temporomandibular Disorders [2]. Temporomandibular Disorder as a collective term consist of many entities, including myogenous and arthrogeous components [3]. Myogenous temporomandibular disorders are characterized by pain and dysfunction that arises from pathological and functional processes in the masticatory muscles [4]. According to glossary of Prosthodontics: TMD is a conditions producing abnormal, incomplete, or impaired function of the temporomandibular joint(s) and/or the muscles of mastication [5]. Temporomandibular disorder is the second most common chronic musculoskeletal condition after chronic low back pain. As pain-related TMD can affect an individual's daily activities, psychosocial functioning, and quality of life, it is important to accurately diagnose these complex musculoskeletal disorders to provide the best clinical care. Both clinical history and examination, augmented as indicated with imaging, are needed to render proper TMJ intra-articular diagnoses. As several imaging

modalities recommen- ded in this article use ionizing radiation, careful clinical assessment with due consideration of the benefit to the patient must be carried out before ordering any imaging [6].

2. ETIOLOGY

To understand the disease and to proceed towards differential diagnosis we must know the cause behind it. The etiology of TMD covers various factors like biologic, environmental, social, emotional, and cognitive triggers. Factors consistently associated with TMD include other pain conditions (e.g., chronic head- aches), fibromyalgia, autoimmune disor ders, sleep apnea, and psychiatric illness. A prospective cohort study with more than 6,000 participants showed a twofold increase in TMD in persons with depression [7]. Also few are congenital disorders like condylar hyperplasia, second and third branchial arch defects [8,9].

An overloads, blunt force to the face or flexion-extension (whiplash) neck injuries (may cause or aggravate ID/OA [10]. The repetitive loading of clenching and bruxism possibly are etiologic factors, but a clear relationship has not been established. Genetic and metabolic factors may contribute by lowering the threshold for tissue damage from overloads (relative) or trauma and therefore may also be an important factor in the development of TMD pain [9,11].

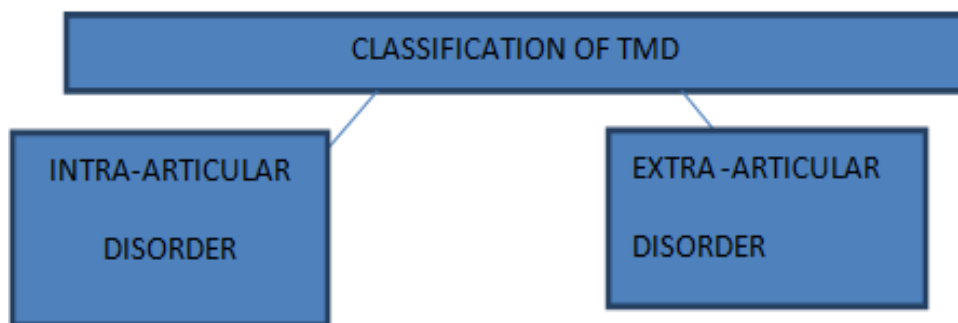


Fig. 1. Flow chart showing classification of TMD

The classification which we have developed in this is inspired by Robert Gauret and Axel Bumann and Ulrich Lotzmann In Collaboration with James Mah. This classification simplifies and increases the understanding of differential diagnosis.

2.1 Articular Disorders (Intra Articular)

1. Congenital or Development Disorder [7]
2. First and Second Branchial Arch disorder [8]
3. Condylar hyperplasia [7]
4. Idiopathic resorption [10]
5. Degenerative Joint disorders
 - Inflammatory includes Capsulitis, Synovitis, Retrodiskitis, Polyarthritits , Osteoarthritis (Predilected in women is also unilateral)
 - Non Inflammatory
6. Disc Derangement Disorders (For details Table 1) [11]
 - With Reduction
 - Without Reduction
 - Perforation
7. Trauma [12,13]
 - Tendonitis
 - Myositis
 - Traumatic Arthritis
 - Fracture
 - Internal Derangement
8. Infection
9. Neoplasm
10. TMJ hypermobility
11. Post Surgical Problems

2.2 Muscle Disorders [14]

2.2.1 Myofacial pain

It is a Localised pain in the direction of injured muscle fibres. It is usually a dull pain with no swelling. Usually pain is observed in Isometric contraction and provocation of the same pain by palpation [15].

2.2.2 Myostasis

Acute Generalised pain with inflammation and swelling. Usually Non specific in nature. It is an acute pain with reduced mandibular mobility [16].

2.2.3 Tendonitis

Inflammatory changes in the area of muscles tendon or the attachment of tendon to bone without triggering. In direction of affected muscles. Pain duroing specific isometric contraction and the pain provokes by palpation.

2.2.4 Myalgia

Pain plus feelings of "pulling", fatigue, and bracing in the musculature, but with no pain at rest, no trigger areas or referred pains. It could be specific or non specific in nature.

2.2.5 Functional Muscle shortening

Sudden involuntary tonic contraction of a muscle followed by overextension or overloading, accompanied by pain *and reduced* mandibular mobility.

2.2.6 Muscle Spasm

Painless shortening (fibrosing) of the noncontactile elements of a muscle as a secondary adaptation to hypofunction.

2.3 Brief Understanding of Headache [17]

Headache happens all the more as often as possible in patients with TMD manifestations (27.4% versus 15.2%) [18] and can be partitioned into two principle types: essential migraine and optional cerebral pain.

As per the new indicative models for TMD (DC/TMD), masticatory myofascial torment and cerebral pain are correlated [19]. As characterized in DC/TMD, the affirmation of a myo fascial trigger point (MTrP), the palpation of which overstates the torment, recommends that cerebral pain begins from MTrP, and that myofascial torment doesn't start from intracranial structures. Moreover, the International Classification of Headache Disorders-3 (ICHD-3 beta) suggests that the fleeting connection among cerebral pain and TMD ought to be surveyed as to beginning, advancement, and improve-ment [20]. Involuntary tooth contact is one of the most average parafunctions that is watched more every now and again in patients with TMD than in sound people.

2.4 Sequential Differential Diagnosis Steps

2.4.1 Patient history taking and positioning

A detailed history, head and neck evaluation and general physical examination when indicated, are

essential [11]. The diagnosis of TMD is attributed on history and physical examination findings. The symptoms of TMD are often associated with jaw movement (e.g., opening and closing the mouth, chewing) and pain in the pre-auricular, masseter, or temple region. Another source of orofacial pain should be suspected if pain is not affected by jaw movement. Adventitious sounds of the jaw (e.g., clicking, popping, grating, crepitus) may occur with TMD, but also occur in up to 50% of asymptomatic patients [20]. Most common presenting signs and symptoms were facial pain (96%), ear discomfort (82%), headache (79%), and jaw discomfort or dysfunction (75%) [21]. An important aspect in TMJ history taking and diagnosis is to know the anatomy. If only we know the anatomy we can diagnose and treat further. Anatomy of the temporomandibular joint and the structures responsible for movement of the joint. The most common musculoskeletal conditions associated with temporomandibular disorders (TMD) are noted below: 1. Teeth and mandible. Dental occlusion – normal position is a 1- to 2-mm overbite. Bruxism – look for dental damage and enamel erosion. Mandibular function – opening less than 30 to 35 mm is considered abnormal. 2. Muscles of mastication. TMD findings may include spasm and/or tenderness to palpation of the masseter, temporalis and/or pterygoid muscles. The evaluation is best performed with clenched teeth. 3. Temporomandibular joint (TMJ). The TMJ is a gliding joint formed by the mandibular condyle and temporal bone fossa. The ligamentous capsule, articular disk, and retrodiskal tissue allow for smooth joint movement. Examine the joint by palpating anterior to the tragus bilaterally. Clicking and popping may occur when the articular disk has moved anterior to the condylar head (click) but then is recaptured in proper position (pop) [20]. Imaging of the temporomandibular joints and associated structures is necessary to establish the presence or absence of pathology and stage of disease in order to select the appropriate treatment, assist in prognosis, and assess patient response to therapy. Imaging results will influence treatment strategy. In general, it is recommended that imaging studies be bilateral because of the high incidence of bilateral joint disease. Basic screening radiographs should be used to demonstrate temporal bone and condylar morphology. Radiographs which can provide this information include plain films, panoramic films, and tomograms (frontal and lateral) [22]. The disc and associated soft tissue structures should also be imaged [23]. Magnetic resonance

imaging (MRI) [24] or arthrography [25] can provide this information. Other radiological studies may also be indicated.

2.5 Positioning the Patient

The situation of the patient is a significant condition for a particular assessment and is diverse for each segment of the assessment:

- History taking is constantly done with the patient sit chime upstanding.
- The assessment systems for manual utilitarian analysis are performed from the 12 o'clock position, or all the more correctly, between the 11 and 1 o'clock positions. Three courses of action are conceivable, the decision relying on the inspector, the patient, and the space accessible. These are:
 - a) The persistent is semi-leaned back with the backrest at about a 45° edge and the analyst is standing upstanding behind the patient.
 - b) The quiet is recumbent and the inspector is standing upstanding.
 - c) The quiet is recumbent and the inspector is situated (the best variety).
- Testing for destructive impacts can be done with the patient either completely leaned back or sitting upstanding.

3. MANUAL FUNCTIONAL ANALYSIS [14]

It is basically divided into two types: Active jaw opening and Passive jaw opening.

Active movements do not contribute to the differential diagnosis (Szentpetery 1993), but serve only to document the initial conditions and to verify the symptoms described by the patient.

3.1 Passive Movements

Passive jaw opening is usually executed with both hands. The index or middle fingers are placed on the upper premolars and the thumbs on the lower incisal edges. The patient opens the mouth as far as possible and at the end of the active movement the clinician assists further opening. The amount of passive movement is evaluated. If the one-handed technique is used the distance can be measured with the other hand.

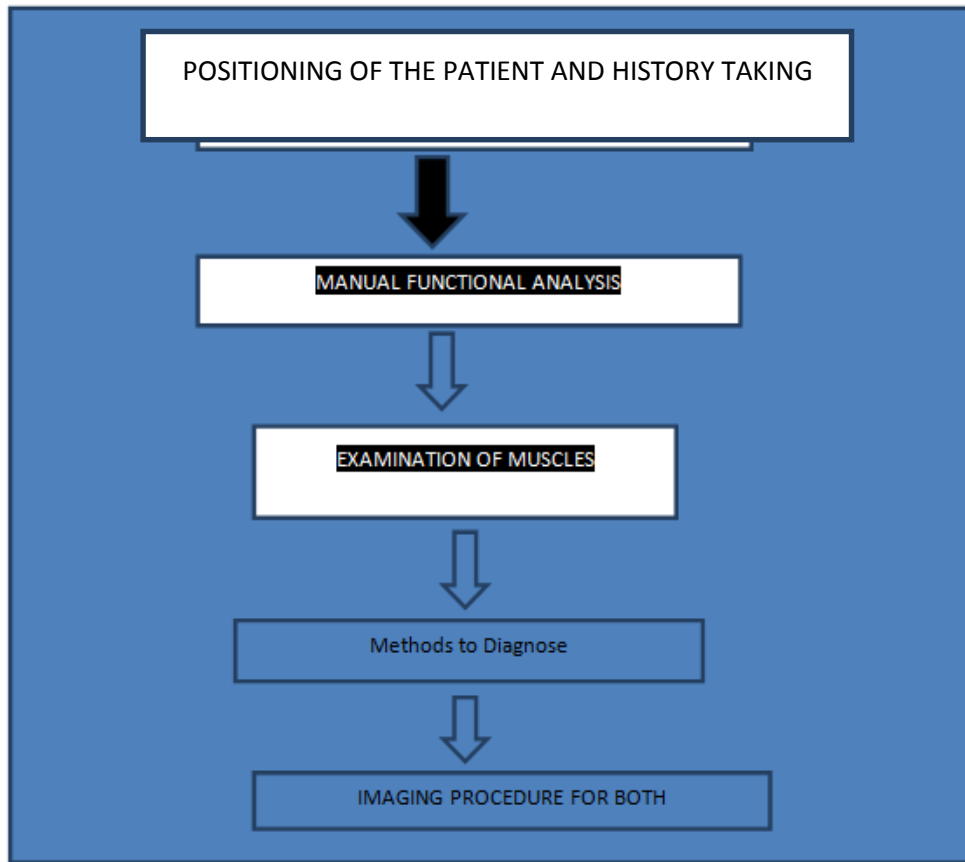


Fig. 2. Flow chart showing sequential differential diagnosis steps

3.2 Examination of Muscles

Usually we get the results in the above diagnosis procedure if the patient is suffering from TMD related problem. Anyhow if there is no finding we move further to examine the muscles. Certainly if patient complaints of muscle pain we should directly move to examination of muscles [26]. (Table 2) pg 88 manual analysis.

4. METHODS FOR DIAGNOSIS

4.1 Primary and Secondary Diagnoses

At the end of the tissue-specific examination, the so-called primary and secondary diagnoses are entered. *Primary diagnoses* include all decompensated functional disturbances that explain the symptoms reported by the patient. *Secondary diagnoses* are compensated functional disturbances that explain the symptoms that could be repeatedly provoked during the examination. For each individual diagnosis, the clinician records the specific loading vector on the examination form. Clarification of the etiological factors cannot begin until this has been done.

4.2 Imaging of TMJ

4.2.1 Panoramic radiography

It shows the jaws and the related structures, being a useful apparatus for the clinician in distinguishing any periodontal or odontogenic reasons for orofacial torment. All encompassing radiography doesn't show up in the rundown of imaging strategies gave by RDC/TMD. Just the parallel piece of the condyle can be surveyed with this method, being constrained because of the superimposition of the zygomatic curve and the base of the skull [27]. All encompassing radiography can help assess the accompanying:

- Degenerative bone changes (just in late stages; it is deficient for the early recognition of bony alterations);
- Asymmetries of the condyles
- Hyperplasia, hypoplasia;
- Trauma;
- Tumors.

The all encompassing radiography doesn't uncover the useful status of the joint and has a

moderately low particularity and affectability when contrasted and CT.

4.2.2 Plain radiography

Comprises of transcranial projection of TMJs. Various angulations are utilized to evade the superposition of the worldly bone and the inverse TMJ: sidelong angled transcranial projections, foremost back projections, submental-vertex projection, transpharyngeal view [28].

4.2.3 Computed tomography (CT)

First used for TMJ evaluation in 1980 [29], CT is considered to be the best method for assessing osseous pathologic conditions of TMJ. It allows a multi planar reconstruction (sagittal, axial,

coronal) of TMJ structures, obtaining 3D images in closed and opened-mouth positions [30]. Signs of degenerative changes in the joint, like surface erosions, osteophytes, remodeling, subcortical sclerosis, articular surface flattening can be evaluated using CT [27].

4.2.4 Magnetic resonance imaging (MRI)

MRI is currently considered the reference method for imaging the soft tissue structures of the TMJ (articular disc, synovial membrane, lateral pterygoid muscle) and has been pointed out as the best imaging modality in diagnosing disc displacements [31,32] MRI could also detect the early signs of TMJ dysfunction, like thickening of anterior or posterior band, rupture of retrodiscal tissue, changes in shape of the disc, joint effusion [32].

Table 1. Piper’s stages for TMD

Stage 1	Structurally Intact TMJ
Stage 2	Intermittent clicking
Stage 3a	Lateral pole clicking
Stage 3b	Lateral pole lock
Stage 4a	Medial pole click
Stage 4b	Medial pole lock

Table 2. Description of different pterygoid muscle

Isometric contraction of the lateral pterygoid muscles	When isometric contraction of the depressors produces preauricular pain, an isometric test is always performed on the lateral pterygoid of the affected side. If this produces the same pain elicited by isometrics of the depressors, there is myofascial pain of the affected lateral pterygoid muscle. If isometric contractions are painless, there is myofascial pain from the suprahyoidal musculature. From this point onward further differentiation can be made only through palpation.
Isometric test of the right lateral pterygoid muscle	For an isometric evaluation of the right lateral pterygoid muscle it is also advisable to choose a joint-relaxing starting position. During the procedure the head must be well supported to avoid overloading the cervical spine. <i>Right:</i> Starting position of the mandible for an isometric test of the right lateral pterygoid muscle. The bilaminar zone on the right side is relaxed by performing a mediotrusive movement
Isometric test of the left lateral pterygoid muscle	Corresponding manual technique for an isometric test of the left lateral pterygoid muscle. The examiner pushes on the mandible toward the midline using a force that just balances the individual patient’s maximum counter force. <i>Right:</i> Starting position of the mandible for the isometric test of the left lateral pterygoid muscle. The bilaminar zone on the left side becomes relaxed by the mediotru-sion.
Palpating the lateral aspect of the tendon of the temporal muscle	The tendon of the right temporal muscle is best examined from the 1 o'clock position. This is done with either the little finger or the middle finger, depending upon the finger length required. Either the tip of the coronoid process or the lateral side of the retromolar triangle may be selected as the starting point

4.2.5 High-resolution ultrasonography

High-goal ultrasonography (US) was first utilized for TMJ investigation in 1991, by Nabeih et al, utilizing a 3.5 MHz transducer [33]. In spite of the fact that it is a non-obtrusive, dynamic, modest method, it isn't regularly utilized in TMJ investigation. Being a constant examination, it gives data about circle position, during mouth openin [34]. In the writing, conflicting degrees of affectability and explicitness were accounted for. These variable degrees of affectability and explicitness announced by the articles might be because of the distinctive hardware utilized (diverse US frequencies). The utilization of high-goal US (transducer in any event 7.5 MHz or higher) essentially expands the demonstrative estimation of this procedure.

4.3 Role of Occlusal Appliances

Dental occlusal splinting and permanent occlusal adjustment have been the mainstays of TMJ disorder treatment. Occlusal splint therapy may be defined as "the art and science of establishing neuromuscular harmony in the masticatory system by creating a mechanical disadvantage for parafunctional forces with removable appliances." Occlusal splint is a diagnostic, relaxing, repositioning and reversible device [34]. Different types and designs of occlusal splints with different classification were reported in the literature. Classification of occlusal appliances according to Okeson [5] include 1) Muscle relaxation appliance/ stabilization appliance used to reduce muscle activity 2) Anterior repositioning appliances/ orthopedic repositioning appliance e 4) Anterior bite plane 5) Pivoting appliance 6) 6oi resilient appliance classification of occlusal appliances according to Dawson [13] include 1) Permissive splints/ muscle deprogrammer 2) Directive splints/ non-permissive splints 3) Pseudo permissive splints (e.g. 6oi splints, Hydrostatic splint).

5. RESULTS

Three investigators evaluated the methodological quality of each identified SR using two measurement tools: the assessment of multiple systematic reviews (AMSTAR) and level of research design scoring. Thirty-one SRs met inclusion criteria and 28 were analysed: 20 qualitative SRs and eight meta-analysis.

Hence, from different literatures data was extracted and a simplified differential diagnosis in a sequential manner was generated.

6. CONCLUSION

TMD pain is a common complaint of patients seen by dental professionals. Even if this complaint is not the primary reason for a patient seeking treatment, or the pain is non odontogenic in origin, it is still important to acknowledge the problem to find an appropriate route to proceed. Hence, a proper simplified sequence to diagnosis and treatment is important. In this article, the new updated imaging procedure and diagnosis is emphasized along with updated classification. A proper systematic review research was done to conclude and simplify the entangled relationship between headache, TMJ disorder and Orofacial pain.

CONSENT

It is not applicable.

ETHICAL APPROVAL

It is not applicable.

COMPETING INTERESTS

Authors have declared that no competing interests exist.

REFERENCES

1. Okeson PJ, Leeuw RD. Differential diagnosis of TMD and other orofacial pain disorders. *Dent Clin N Am*. 2011;55:105-120.
2. Griffiths RH. Report of the president conference on examination, diagnosis and management of TMD; 1983.
3. Steven B. Temporomandibular disorder and headache. *Dent Clin N Am*. 2007;51:129–144.
4. Friction J. Myogenous temporomandibular disorder: Diagnostic and management consideration. *Dent Clin N Am*. 2007;51:61–83.
5. Racich MJ. Occlusion, temporomandibular disorder and orofacial pain. *JOPD*; 2013.
6. Ahmed M, Schiffman EL. Temporomandibular joint disorder and orofacial pain. *Dent Clin N Am*; 2015.
7. Gaurer RL, Semidy MJ. Diagnosis and treatment of temporomandibular disorders. *American Family Physician*. 2015;91(6).
8. Johnson JM, et al. Syndromes of the first and second branchial arches, Part 1:

- Embryology and characteristic defects. AJNR. 2011;32.
9. Billet M, Cadre B. Condylar hyperplasia. J Dentofacial Anom Orthod. 2013;16: 304.
 10. Young A. Idiopathic condylar resorption: The current understanding in diagnosis and treatment. The Journal of Indian Prosthodontic Society. 2017;17(2).
 11. American Society of Temporomandibular Joint Surgeons; Guidelines for Diagnosis and Management of Disorders Involving the Temporomandibular Joint and Related Musculoskeletal Structures.
 12. Henniksan B, et al. Temporomandibular disorder pain after Whiplash trauma: A systematic review. Journal of Orofacial Pain. 2013;27(3).
 13. Giannakopoulos HE, et al. Posttraumatic temporomandibular joint disorders. Craniomaxillofacial Trauma & Reconstruction. 2009;2(2).
 14. Bumann A, Lotzmann U. TMJ disorders and orofacial pain. The Role of Dentistry in a Multidisciplinary Diagnostic Approach.
 15. Marieke Zaffron. Orofacial Pain Guidelines for Assessment, Diagnosis, and Management, Sixth Edition; American Academy of Orofacial Pain.
 16. Merril RL. Central mechanism of orofacial pain. Dent Clin N Am. 2007;51:45–59.
 17. Goldman AR. TMJ syndrome; The overlooked diagnosis. Available:www.dentalbooks-drbassam-blogspot
 18. Aggarwal VR, McBeth J, Zakrzewska JM, Lunt M, Macfarlane GJ. The epidemiology of chronic syndromes that are frequently unexplained: Do they have common associated factors? Int J Epidemiol. 2006;35:468-76.
 19. Schiffman E, Ohrbach R, Truelove E, Look J, Anderson G, Goulet JP, et al. Diagnostic criteria for temporomandibular disorders (DC/ TMD) for clinical and research applications: Recommendations Cation of the International RDC/TMD Consortium Network and Oro- facial Pain Special Interest Group. J Oral Facial Pain Headache. 2014;28:6-27.
 20. Robert L, Gauer MD, Michael J, Semidey DMD. Diagnosis and treatment of temporomandibular disorders. 2015;91(6). Available:www.aafp.org/afp
 21. Headache Classification Committee of the International Headache Society (IHS). The international classification of headache disorders, 3rd Edition (Beta Version). Cephalalgia. 2013;33:629-808.
 22. Cooper BC, Kleinberg I. Examination of a large patient population for the presence of symptoms and signs of temporomandibular disorders. Cranio. 2007;25(2):114-126.
 23. Brand J, et al. The effects of temporomandibular joint internal derangement and degenerative joint disease on tomographic and arthrotomographic images. Oral Surg Oral Med Oral Path. 1989;67:220.
 24. Harms SE, Wilk RM, Wolford LM, et al. The temporomandibular joint: Magnetic resonance imaging using surface coils. Radiology. 1985;157:133.
 25. Katzberg RW, Bessette RW, Tallents RH, et al. Normal and abnormal temporomandibular joint: MR imaging with surface coil. Radiology. 1986;158:183-47. Wilkes CH. Arthrography of the temporomandibular joint in patients with the TMJ pain-dysfunction syndrome. Minn Med. 1978;61:645.
 26. Katzberg RW, Dolwick MF, Helms CA, et al. Arthrotomography of the temporomandibular joint. AJR. 1980;134: 995.
 27. Okeson P. Differential diagnosis of temporomandibular disorder, orofacial and other pain. Dent Clin N Am. 2011;55:105–120.
 28. Talmaceanu D, et al. Imaging modalities for temporomandibular joint disorders: An update. 2018;91(3):280–287.
 29. Ahmad M, Hollender L, Anderson Q, Kartha K, Ohrbach R, Truelove EL, et al. Research diagnostic criteria for temporomandibular disorders (RDC/TMD): Development of image analysis criteria and examiner reliability for image analysis. Oral Surg Oral Med Oral Pathol Oral Radiol Endod. 2009;107(6):844–860.
 30. Brooks SL, Brand JW, Gibbs SJ, Hollender L, Lurie AG, Omnell KA, et al. Imaging of the temporomandibular joint: A position paper of the American Academy of Oral and Maxillofacial Radiology. Oral Surg Oral Med Oral Pathol Oral Radiol Endod. 1997;83(5):609–618.
 31. Baba IA, Najmuddin M, Shah AF, Yousuf A. TMJ imaging: A review. International Journal of Contemporary Medical Research. 2016;3(8):2253–2256.
 32. Liedberg J, Panmekiate S, Petersson A, Rohlin M. Evidence-based evaluation of

- three imaging methods for the temporomandibular disc. Dentomaxillofac Radiol. 1996;25:234–241.
33. Bag AK, Gaddikeri S, Singhal A, Hardin S, Tran BD, Medina JA, et al. Imaging of the temporomandibular joint: An update. World J Radiol. 2014;6(8):567–582.
34. Ahmed Yaseen Alqutaibi, Afaf N, Aboalreja L. Types of occlusal splint in management of Temporomandibular Disorders (TMD). J Arthritis. 2015;4:4.

© 2020 Brar et al.; This is an Open Access article distributed under the terms of the Creative Commons Attribution License (<http://creativecommons.org/licenses/by/4.0>), which permits unrestricted use, distribution, and reproduction in any medium, provided the original work is properly cited.

Peer-review history:

The peer review history for this paper can be accessed here:
<http://www.sdiarticle4.com/review-history/61082>