



Bilateral Persistent Pupillary Membrane: Bilateral Obturating Form

Ayoub Redouan^{1,2*}, Mohamed Khalifi^{1,2}, Loubna El Maaloum^{1,2}, Bouchra^{1,2}, Allali^{1,2} and Asmae El kettani^{1,2}

¹*Pediatric Ophthalmological Department, 20 August 1953 Hospital, Casablanca, Morocco.*
²*Hassan II University, Casablanca, Morocco.*

Authors' contributions

This work was carried out in collaboration among all authors. All authors read and approved the final manuscript.

Article Information

Editor(s):

(1) Dr. Yasushi Shibata, Mito Medical Center, University of Tsukuba, Japan.

Reviewers:

(1) Thanuja G.P, M.S. Ramaiah medical College, India.

(2) Majid Moshirfar, University of Utah, USA.

Complete Peer review History: <http://www.sdiarticle4.com/review-history/64962>

Case Study

Received 18 April 2021
Accepted 23 June 2021
Published 29 June 2021

ABSTRACT

Persistence of the pupillary membrane (PPM) is a congenital pathology characterized by the persistence of Tunica vasculosa lentis anterior, which normally resolves during the third trimester by the apoptotic phenomena.

We report the case of a girl referred for an esotropia, at the ophthalmologic examination we found a dense bilateral pupillary membrane blocking the visual axis, Surgical resection of the pupillary membrane is the technique of choice in thick pupillary membranes that completely cover the visual axis, because of the major risk of amblyopia.

Keywords: *Esotropia; Persistent pupillary membrane; surgical resection; high myopia.*

1. INTRODUCTION

Persistence of the pupillary membrane (PPM) is a congenital pathology characterized by the persistence of Tunica vasculosa lentis

anterior which normally resolves during the third trimester by the apoptotic phenomena. The bilateral form remains rare, found especially in premature children, which can affect visual function, that's why medico-surgical

*Corresponding author: E-mail: Drayoubredouan@gmail.com;

management is necessary to prevent and treat amblyopia.

We report the case of a girl referred for alternating esotropia whose ophthalmologic examination found a dense bilateral pupillary membrane blocking the visual axis which required surgical resection.

2. OBSERVATION

We relate the case of a 6-year-old girl, with no history of prematurity, and no familial similar case, who was referred to the pediatric

ophthalmology department for strabismus. On ophthalmologic examination, visual acuity was counting finger, with right eye esotropia. The Slit-lamp examination found a dense pupillary membrane covering the entire visual axis even after mydriasis (Fig. 1). The anterior segment examination was normal (no associated congenital cataract or keratoconus).

After injection of the viscoelastic, the pupillary membrane was resected by a Vannas micro-scissors (Fig. 2). the corrected postoperative visual acuity was 02/10 in both eyes (Snellen's visual acuity), the refraction under cycloplegia

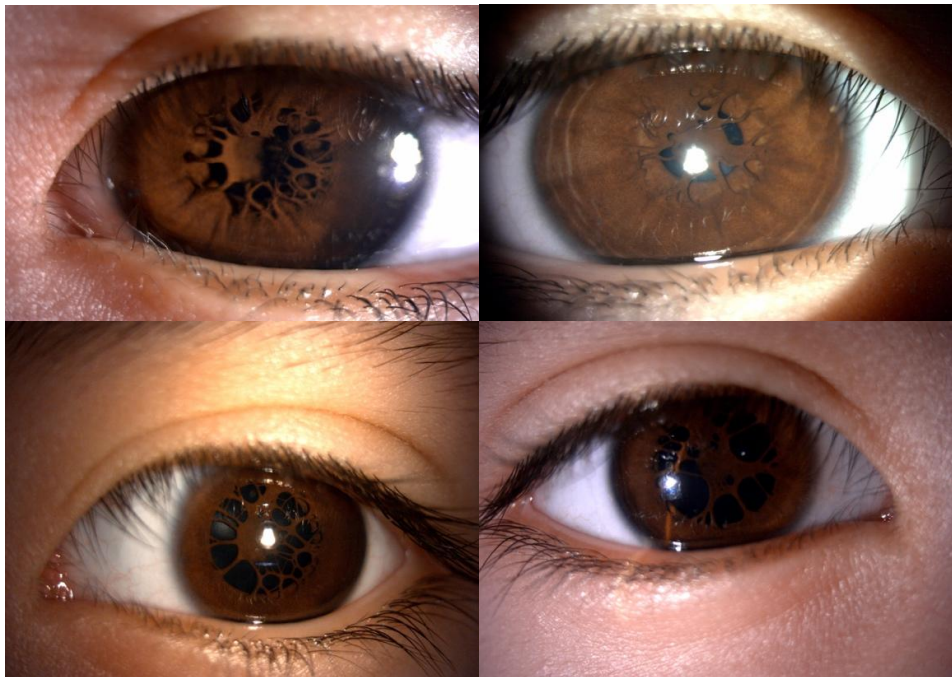

Fig. 1. Persistence of the bilateral pupillary membrane before and after dilation, dense membrane occluding the visual axis in both eyes

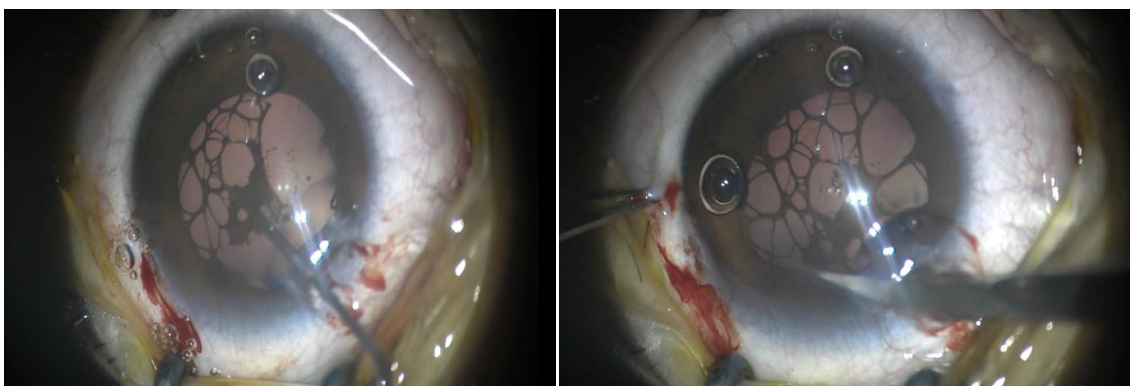


Fig. 2. Surgical removal of the pupillary membrane by micro-vannas with pupilloplasty

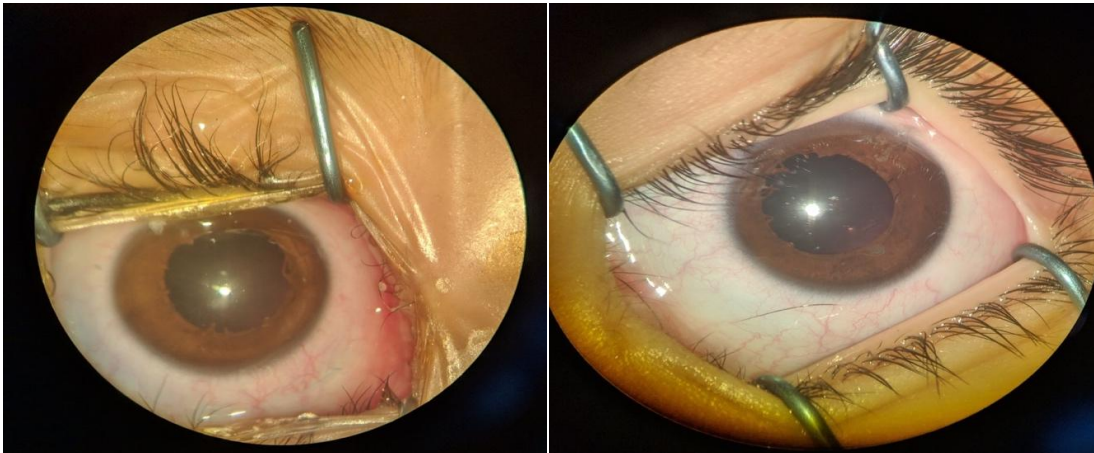


Fig. 3. Appearance of the iris after surgical removal of the pupillary membrane in both eyes, noted the persistence of a few limited iris fibers on the pupil which leave the visual axis clear

showed a myopia - 5 diopters in the right eye and - 4 diopters in the left eye. The pupil was round regular with persistence of a few fibers of the iris limited to the pupillary edge (Fig. 3). The fundus was normal with diffuse chorioretinal atrophy.

3. DISCUSSION

The persistence of the pupillary membrane (PPM) is a congenital disease, due to the persistence of the Tunica vasculosa lentis anterior, this vascular layer completely disappears at the 8th month of embryonic life thanks to apoptotic mechanisms [1].

Usually, PPM is discreet, with a few iris fibers stretched across the pupil, without visual impact. In rare cases, especially premature infants, it is thick and dense, forming an obturating plaque occupying the visual axis [2]. Certain iris fibers adhere to the cornea or to the anterior crystalloid, which explains the occurrence of cataracts, edema or corneal opacity [2,3].

Most membranes are asymptomatic and require monitoring given the risk of amblyopia which must be managed early. The use of mydriatic eye drops in some patients allows the release of adhesions of the iris collar and their detachment from the anterior capsule [2,4].

Performing an Nd YAG laser pupilloplasty is a useful approach in older children. Complications such as cataracts, ocular hypertension, uveitis and hyphema are rare [5,6]. Surgical resection of the pupillary membrane is the technique of choice in thick pupillary membranes completely

covering the visual axis with the risk of amblyopia. Complications of this surgical technique are hyphema and cataracts when the membrane is vascularized adherent to the anterior crystalloid [7,3].

4. CONCLUSION

The persistence of the pupillary membrane obturating form is a severe pathology that requires rapid surgical management to avoid amblyopia, which must be systematically managed after the surgery.

CONSENT

As per international standard or university standard, patient's consent has been collected and preserved by the authors.

ETHICAL APPROVAL

As per international standard, written ethical approval has been collected and preserved by the author(s).

COMPETING INTERESTS

Authors have declared that no competing interests exist.

REFERENCES

1. Fard AM, Asghari S, Pourafkari L, Nader ND. Persistent pupillary membrane. QJM. 2016;109: 139-40.

2. Doyle JJ, Reddy AK. Bilateral persistent pupillary membranes. JAMA Ophthalmology. 2016;134:e160030.
3. Ida M, Mimura T, Goto M, et al. Excision of congenital bilateral persistent pupillary membrane in a child with exotropia. Open ophthalmol J. 2015;9:33-5.
4. Burton BJ, Adams GG. Persistent pupillary membranes. Br J Ophthalmol. 1998; 82:711-2.
5. Ahmad SS, Binson C, Lung CK, Ghani SA. Bilateral persistent pupillary membranes associated with cataract. Digit J Ophthalmol. 2011;17: 62-5.
6. Gupta R, Kumar S, Sonika, Sood S. Laser and surgical management of hyperplastic persistent pupillary membrane. Ophthalmic Surg Lasers Imaging. 2003; 34:136-9.
7. Tsai YY, Chiang CC, Tsai CH. Surgical technique for removing an extensive persistent pupillary membrane. J Cataract Refract Surg. 2004;30:1622-5.

© 2021 Redouan et al.; This is an Open Access article distributed under the terms of the Creative Commons Attribution License (<http://creativecommons.org/licenses/by/4.0>); which permits unrestricted use; distribution; and reproduction in any medium; provided the original work is properly cited.

Peer-review history:

*The peer review history for this paper can be accessed here:
<http://www.sdiarticle4.com/review-history/64962>*