



A Case Report of Endoscopic Management of Traumatic Intrahepatic Bile Duct Injury

Amol Nansaheb Wagh¹, Parth Bhavesh Gada^{1*}, Hemant Mukhtaram Jawale¹
and Snehal Milind Dandge¹

¹Department of General Surgery, Grant medical College and Sir J. J. Group of Hospitals, Mumbai 400008, India.

Authors' contributions

This work was carried out in collaboration among all authors. Authors AW, PG and HJ designed the study, performed the statistical analysis, wrote the protocol and wrote the first draft of the manuscript. Authors HJ and SD managed the analyses of the study. Authors PG and SD managed the literature searches. All authors read and approved the final manuscript.

Article Information

Editor(s):

(1) Dr. Asmaa Fathi Moustafa Hamouda, Jazan University, Saudi Arabia.

Reviewers:

(1) S. Y. Mulkipatil, Karnataka Institute of Medical Sciences (KIMS), India.

(2) Irin Perveen, Enam Medical College, Bangladesh.

Complete Peer review History: <http://www.sdiarticle4.com/review-history/69669>

Case Study

Received 14 April 2021

Accepted 18 June 2021

Published 23 June 2021

ABSTRACT

Introduction: Penetrating Abdominal Trauma is less common than Blunt Abdominal Trauma in India. The clinical appearance of bile duct injuries is highly variable and depends primarily on the underlying cause.

Case: We present a case of a stab injury ie penetrating abdominal injury who developed AAST grade III hepatic injury, for which exploratory laparotomy with perihepatic packing was done as patient was hemodynamically unstable and an abdominal drain was also placed. Billious drain was seen on fifth post-operative day, which was managed by Endoscopic Retrograde Cholangiopancreatography (ERCP) with sphincterotomy and 7 Fr x 10 cm stent placed up to distal right main hepatic duct. Bile leak stopped after ERCP.

Discussion: Traumatic biliary tree injury should be kept in consideration when dealing with trauma patients. Surgeons should bear in mind the good success rates of ERCP to avoid more morbid procedures, unless indicated.

*Corresponding author: E-mail: parthg1895@gmail.com;

Keywords: Endoscopic retrograde cholangiopancreatography; abdominal injuries; penetrating wounds.

1. INTRODUCTION

Penetrating or blunt injury to the biliary tree remains a rare complication of trauma occurring in 0.1% of trauma admissions [1]. Bile duct injuries can occur after abdominal trauma, postoperatively after cholecystectomy, liver resection or liver transplantation and also as a complication of endoscopic retrograde cholangiopancreatography (ERCP). The clinical appearance of bile duct injuries is highly variable and depends primarily on the underlying cause.

2. CASE REPORT

A fifty-year-old female, brought by relatives with alleged history of assault by a known person with a sharp object to her neck, chest and abdomen at her residence. She was referred from a private hospital after initial resuscitation. She is a known case of Diabetes Mellitus on oral medications. On examination, she was hemodynamically unstable. Per abdomen was soft. She had multiple sutured wounds measuring 8x1 cm, 3x1 cm and 4x1 cm over the neck, right axillary region and right lumbar region respectively. X-ray

of Chest and abdomen did not reveal any pneumoperitoneum. Ultrasound of abdomen and pelvis was suggestive of mild to moderate hemoperitoneum. Patient was posted for exploratory laparotomy. Intraoperatively, a 3 x 2 cm hepatic laceration was seen in segment VI & VII (AAST grade III) (Fig. 1), which was packed with Gelfoam sponge. A 30FG abdominal drain was placed after a thorough abdominal wash with warm saline. Patient was stable post-operatively. Bilious drain was seen on fifth post-operative day (POD), which gradually increased in quantity. Magnetic resonance cholangiopancreatography (MRCP) done on POD8 (Fig. 2) showed right posterior sectoral duct injury. Hence ERCP was done on POD10 which confirmed the findings of MRCP. A sphincterotomy was done and 7 Fr x 10 cm stent was deployed and free flow of bile was seen (Fig. 3). CT was done post ERCP (Fig. 4). No bile leak was seen in the drain after ERCP. She was discharged on POD 18 after drain removal. Patient was followed up after 4 months, where repeat ERCP was done. As right posterior sectoral bile duct was not completely healed, repeat stenting was done.

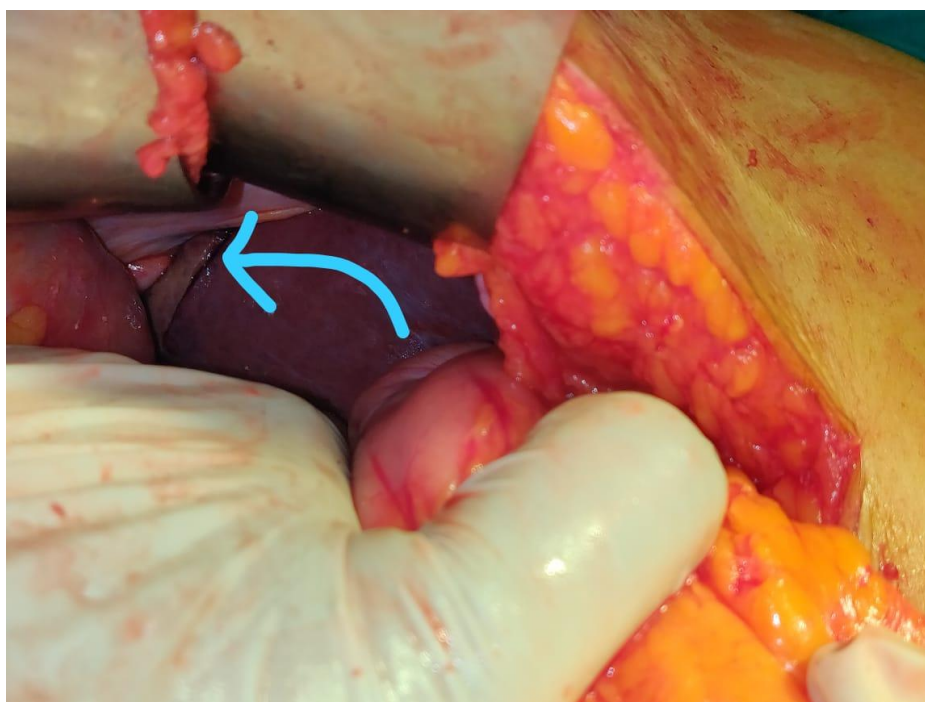


Fig. 1. Intraoperative image – 3 x 3 cm laceration (arrow) in right lobe of liver – segment VII

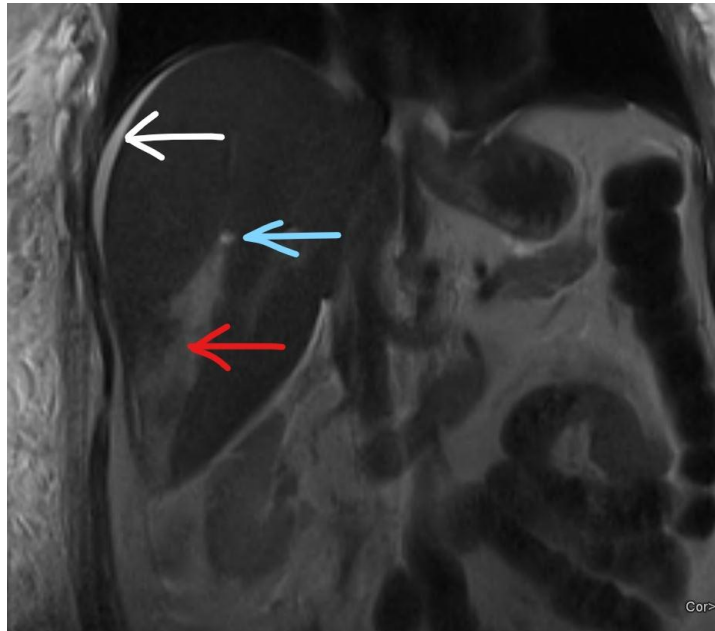


Fig. 2. Coronal plane of Magnetic resonance cholangiopancreatogram – A sectoral duct of segment VII (blue arrow) is seen terminating within the collection along the laceration site (red arrow), likely suggestive of right posterior sectoral duct injury at its terminal site. Subcapsular collection (white arrow) of maximum thickness 7 mm is seen over the right lobe with a wedge-shaped infarct of altered signal intensity secondary to hepatic infarction following the injury

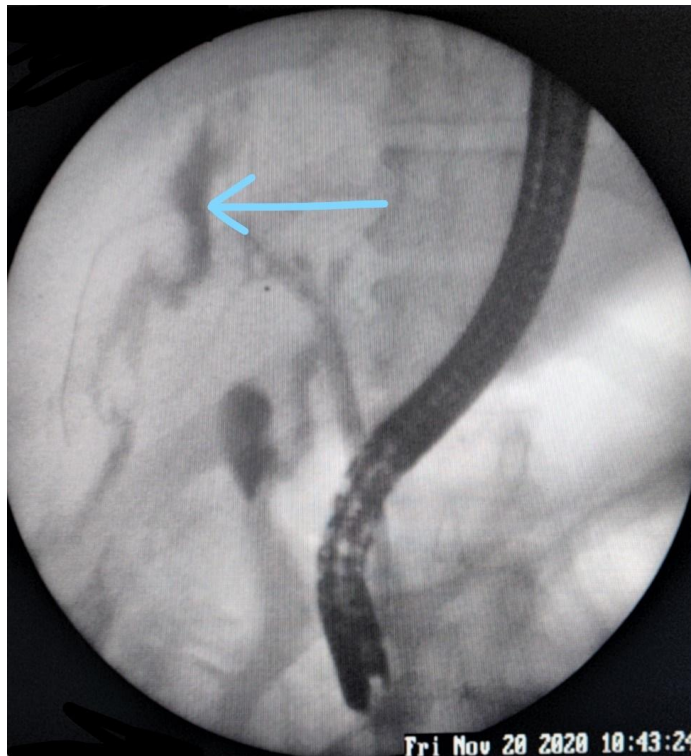


Fig. 3. Endoscopic retrograde cholangiopancreatogram – the site of leak (arrow)

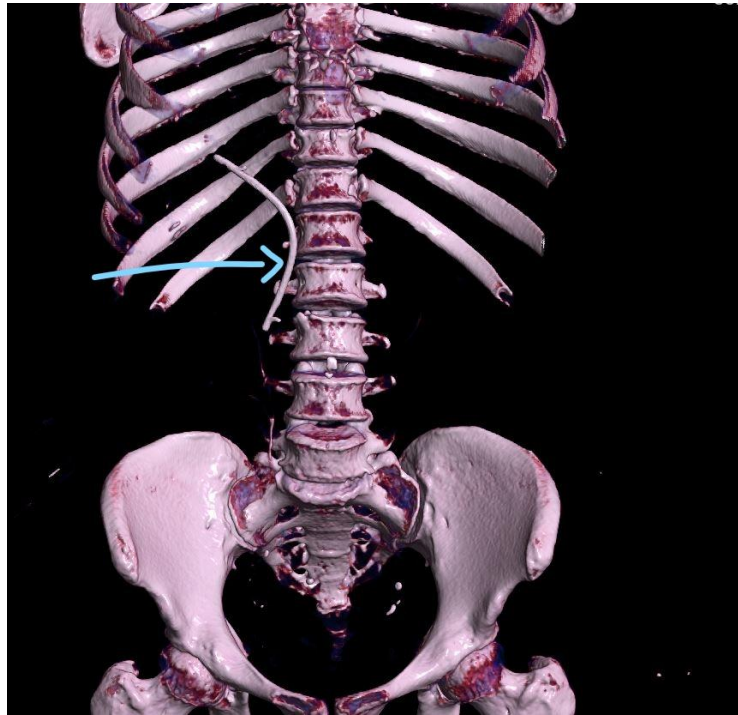


Fig. 4. 3D reconstruction image of post-ERCP Computed Tomography scan of abdomen – showing a 7 Fr x 10 cm stent in right hepatic duct and common bile duct (arrow)

3. DISCUSSION

Trauma accounts for 10.1% of the global burden of the disease [2], of which abdomen makes up 11.72% of all trauma cases and has a proportional case fatality rate of 12.87% in the US as per the NTDP annual report 2016 [3]. Abdominal trauma is classified as blunt abdominal trauma (BAT) or penetrating abdominal trauma (PAT). PAT is mostly diagnosed reliably and easily, whereas BAT is often missed because clinical signs are less obvious [4]. In India, BAT is almost twice as common as PAT [4,5] which is contrary to the trend in US where PAT (23.8%) is commoner than BAT (12.1%) [6].

Commoner mechanisms of PAT in India are stab injuries rather than gunshot wounds. With reference to the algorithm of management of abdominal stab injuries [7], patients with hemodynamic instability, peritonitis, or evisceration require immediate laparotomy. If negative, local wound exploration is advised to determine whether anterior or posterior fascia is violated. Patients with possible fascial penetration should be monitored with serial clinical examination and laboratory studies.

We decided to go ahead with exploratory laparotomy in view of unstable hemodynamics of the patient and eFAST showing mild hemoperitoneum. Intraoperatively, hepatic packing was done ie damage control laparotomy, bleeding was controlled and patient was shifted to ward.

Risk factors for bile leak include high-grade liver injury, centrally-located liver trauma and use of Transcatheter Arterial Embolization (TAE). A bilirubin level greater than 43.6 $\mu\text{mol/L}$ provides a sensitivity of 100% and specificity of 85.1% for predicting major bile leak [8].

Nonoperative management of hepatic injury can lead to complications like biloma, biliary fistula, intraabdominal abscess, hepatic abscess, haemobilia, liver necrosis or abdominal compartment syndrome [9]. Adjunctive modalities like angiography, ERCP, image-guided drainage and laparoscopy can be used in such conditions. Scanning with HIDA, endoscopic retrograde cholangiography, and intraoperative cholangiography has been useful in detecting occult ductal injuries [10].

CT guided percutaneous drainage can play a key role and can obviate the need of exploratory laparotomy in some cases [11]. Our patient had persistent high output bile drainage from the abdominal drain placed after the operation, which indicates injury to segmental or lobar bile duct. ERCP has a number of advantages over open operation in the diagnosis and management of small traumatic biliary leaks as it does not require a general anesthetic and also provides effective biliary drainage by endoscopic papillotomy and stenting, apart from being minimally invasive and cheaper [12]. ERCP in our patient showed injury to right posterior sectoral duct.

In a retrospective study of ten patients who underwent ERCP for the management of a traumatic bile leak over a 3-year period; biliary stent placement led to successful outcome in 9 of 10 cases (90%). The mean duration of follow-up was 337 days (range, 101-821 days). There were no ERCP-related complications [13]. Another study from Houston [14] showed successful management by ERCP in all 14 of 14 cases (100%) with a mean duration of follow-up was 85.6 days (range 54-175 days) and again no ERCP-related complications. This highlights the importance of ERCP.

In a retrospective review of 30 patients with 33 biliary injuries presenting to trauma services in Melbourne, with a mortality rate of 10%, cholecystectomy was done in 8 out of 10 gallbladder injuries. The number of injuries to intrahepatic and extrahepatic biliary duct injuries were 14 and 9 respectively. Of these, 4 out of 7 segmental duct injuries required a surgical procedure like hepatic resection or debridement. 5 out of 9 common bile duct injuries required T-tube placement, with or without bilioenteric anastomosis and one a pancreaticoduodenectomy.¹ This shows the role of surgery in such injuries.

Another endoscopic yet cost effective way of dealing with traumatic biliary injuries is a nasobiliary drain (NBT) with 90% effectiveness, with most leaks settling within 3 to 12 days. It permits a cholangiogram to check for any persistent leak, it can be removed easily without doing another endoscopy. However, the tube is uncomfortable for the patient and there is a risk of dislodgement of the tube [15].

The gravity of the injury dictates the best endoscopic management for the patient. Sphincterotomy alone suffices for small leaks, but stent is required for larger leaks [16].

Transpapillary stenting decreases the pressure gradient across the sphincter of Oddi which obviates a sphincterotomy and hence its potential complications as well [17]. Better criteria are needed to help decide the modality of treatment. Also, further research is warranted to identify patients which will benefit from ERCP versus those who require early surgical intervention.

Percutaneous drainage of intra-abdominal or intrahepatic bile collections, ERCP with biliary sphincterotomy and temporary bile duct stenting, represent an effective and safe strategy for the management of bile leaks following both blunt and penetrating hepatic trauma. The treatment requires close multidisciplinary cooperation between surgery, interventional gastroenterology and interventional radiology.

4. CONCLUSION

ERCP should be considered in the management of traumatic bile leaks, because endobiliary stent placement provides a successful outcome in a majority of cases, irrespective of the severity of injury. Primary surgical interventions like segmentectomy or lobectomy should be reserved only for cases of failure of endoscopic management.

CONSENT

Written informed consent was taken from the patient for publishing the data.

ETHICAL APPROVAL

As per international standard or university standard written ethical approval has been collected and preserved by the author(s).

ACKNOWLEDGEMENT

Department of Gastroenterology, LTMMC and Sion Hospital, Mumbai, where ERCP was done.

COMPETING INTERESTS

Authors have declared that no competing interests exist.

REFERENCES

1. Thomson BNJ, Nardino B, Gumm K, et al. Management of blunt and penetrating biliary tract trauma. *J Trauma Acute Care Surg.* 2012;72(6):1620-1625.

- DOI: 10.1097/TA.0b013e318248ed65
2. Haagsma JA, Graetz N, Bolliger I, et al. The global burden of injury: Incidence, mortality, disability-adjusted life years and time trends from the Global Burden of Disease study 2013. *Inj Prev*. 2016;22(1):3-18.
DOI: 10.1136/injuryprev-2015-041616
 3. NTDB Reports and Publications. American college of surgeons. Accessed March 27, 2021. Available: <https://www.facs.org/quality-programs/trauma/tqp/center-programs/ntdb/docpub>
 4. Kundlas R, GR, Alexis J, Jagadish S, Tp E. Clinico – epidemiological profile, pattern and outcome of abdominal trauma in A level 1 trauma centre in South India. *IJCMR*. 2020;7(5).
DOI: 10.21276/ijcmr.2020.7.5.29
 5. Krishnappa N, Khan A, Sakranaik S. An analysis of injury patterns of abdominal trauma in patients attending surgical emergency department of rural hospital, Karnataka, India. *International Surgery Journal*. 2017;4(11):3736-3739.
DOI: 10.18203/2349-2902.isj20174897
 6. Townsend CMR, Daniel Beauchamp, B Mark Evers, Kenneth L Mattox. *Sabiston textbook of surgery: The biological basis of modern surgical practice*. 20th Edition. 20th ed. Elsevier Saunders; 2017.
 7. Biffl WL, Kaups KL, Cothren CC, et al. Management of patients with anterior abdominal stab wounds: a Western Trauma Association multicenter trial. *J Trauma*. 2009;66(5):1294-1301.
DOI: 10.1097/TA.0b013e31819dc688
 8. Yuan KC, Wong YC, Fu CY, Chang CJ, Kang SC, Hsu YP. Screening and management of major bile leak after blunt liver trauma: a retrospective single center study. *Scand J Trauma Resusc Emerg Med*. 2014;22:26.
DOI: 10.1186/1757-7241-22-26
 9. Blumgart's surgery of the liver, biliary tract and pancreas, 2-volume set - 6th edition. Accessed March 27, 2021. Available: <https://www.elsevier.com/books/blumgarts-surgery-of-the-liver-biliary-tract-and-pancreas-2-volume-set/jarnagin/978-0-323-34062-5>
 10. Feliciano DV. Biliary injuries as a result of blunt and penetrating trauma. *Surg Clin North Am*. 1994;74(4):897-907;discussion 909-912.
 11. Castagnetti M, Houben C, Patel S, et al. Minimally invasive management of bile leaks after blunt liver trauma in children. *J Pediatr Surg*. 2006;41(9):1539-1544.
DOI: 10.1016/j.jpedsurg.2006.05.007
 12. Lubezky N, Konikoff FM, Rosin D, Carmon E, Kluger Y, Ben-Haim M. Endoscopic sphincterotomy and temporary internal stenting for bile leaks following complex hepatic trauma. *Br J Surg*. 2006;93(1):78-81.
DOI: 10.1002/bjs.5195
 13. Bridges A, Wilcox CM, Varadarajulu S. Endoscopic management of traumatic bile leaks. *Gastrointest Endosc*. 2007;65(7):1081-1085.
DOI: 10.1016/j.gie.2006.11.038
 14. Spinn MP, Patel MK, Cotton BA, Lukens FJ. Successful endoscopic therapy of traumatic bile leaks. *Case Rep Gastroenterol*. 2013;7(1):56-62.
DOI: 10.1159/000346570
 15. Chong VH, Jalihal A, Tan KK. Nasobiliary drainage for traumatic bile duct injury. *Gastrointest Endosc*. 2008;67(2):387-388; author reply 388.
DOI: 10.1016/j.gie.2007.09.009
 16. Bajaj JS, Spinelli KS, Dua KS. Postoperative management of noniatrogenic traumatic bile duct injuries: role of endoscopic retrograde cholangiopancreatography. *Surg Endosc*. 2006;20(6):974-977.
DOI: 10.1007/s00464-005-0472-3
 17. Kaffes AJ, Hourigan L, De Luca N, Byth K, Williams SJ, Bourke MJ. Impact of endoscopic intervention in 100 patients with suspected postcholecystectomy bile leak. *Gastrointest Endosc*. 2005;61(2):269-275.
DOI: 10.1016/s0016-5107(04)02468-x

© 2021 Wagh et al.; This is an Open Access article distributed under the terms of the Creative Commons Attribution License (<http://creativecommons.org/licenses/by/4.0>), which permits unrestricted use, distribution, and reproduction in any medium, provided the original work is properly cited.

Peer-review history:

The peer review history for this paper can be accessed here:
<http://www.sdiarticle4.com/review-history/69669>