



Recovery Profile of Patients Suffered with Traumatic Brains Injuries (TBI): Analysis of Case Reports

Gabriel Rodrigues Brito ^{a*}, Matheus de Lima Botelho ^a
and Mateus Silva Santos ^a

^a Faculty of Medicine, University of Gurupi (UnirG), Paraíso, Brazil.

Authors' contributions

This work was carried out in collaboration among all authors. All authors read and approved the final manuscript.

Article Information

DOI: 10.9734/JAMMR/2023/v35i205185

Open Peer Review History:

This journal follows the Advanced Open Peer Review policy. Identity of the Reviewers, Editor(s) and additional Reviewers, peer review comments, different versions of the manuscript, comments of the editors, etc are available here: <https://www.sdiarticle5.com/review-history/104721>

Review Article

Received: 11/06/2023

Accepted: 18/08/2023

Published: 26/08/2023

ABSTRACT

Aims: Identify the different recovery profiles of patients with traumatic brain injury (TBI).

Methodology: This study constituted a review of the literature based on the analysis of case reports published in past five years, about the profile of recovery of TBI victims on PubMed database. Manuscript in English and Portuguese language were considered. About of criteria of eligibility were prioritized articles containing information about: Patient's ages, genders, and complaints, TBI classification treatment, recovery, follow-up, and sequelae of the victims. Post-mortem studies and focused on surgical or drug treatment of the affected patient were excluded.

Results: Based on the established criteria, 08 studies were selected that contained information about the recovery of patients affected by TBI and that contemplated the established selection criteria.

Discussion: Among the results obtained, regarding the recovery profile of patients who are victims of traumatic brain injury, we list the recognition of the similarity of the pathogenic mechanisms involved in TBI, the emergence of various posterior dysfunctions, interdependence of severity,

*Corresponding author: E-mail: gabrielrodriguesbrito@gmail.com;

affected area and immediate intervention chosen. As well as, a variation of conducts was presented in each case, added to the significant evidence of the involvement of external factors among the prognosis on a case-by-case basis, such as: the lack of hospital structure, time until the beginning of the intervention and the presence of irreversible sequelae that they can be from a single or multiple body systems depending on the case.

Conclusion: The recovery profile of TBI patients can vary depending on the severity and extent of brain damage. These patients usually undergo a multidisciplinary rehabilitation process aimed at promoting functional recovery and improving quality of life. In the early stages of recovery, it is common for patients to have physical, cognitive, and emotional impairments. In addition, neuropsychological rehabilitation is essential to treat cognitive deficits, such as memory, attention, concentration and reasoning problems.

Keywords: Brain injuries; prognosis; recovery of function.

1. INTRODUCTION

Traumatic Brain Injury (TBI) or, as it is also known, consists by definition of the involvement of a brain injury resulting from a force applied to the skull, capable of interrupting the full physiological functioning of the brain, temporarily or permanently, having how it causes penetrating or non-penetrating trauma [1]. In addition, it constitutes the most common reason for admission to emergency services, and the main cause of death and sequelae in polytraumatized patients, and in Brazil, it is estimated that more than 1 million people live with irreversible neurological sequelae caused by TBI [2].

Within its pathophysiology, the action of direct, rotational or shear forces after focal involvement of the lesion triggers a series of factors that clarify the evolution of the condition³. The initial injury mechanism damages the axonal membranes, generating a fragility that culminates in a greater output of K⁺ ions, which were previously concentrated mostly in the intracellular environment, such an event triggers the so-called "Impact Depolarization", taking into account since the difference in the generated concentration gradient promotes sodium influx and consequently forced cell depolarization. As a result, several amino acids and excitatory neurotransmitters are released into the synaptic clefts, promoting the transit of Ca²⁺ and K⁺ ions to and from the cells [3,4].

After the first events, cerebral hypoxia tends to occur through the inflammatory process and the formation of pericellular edema, also known as vasogenic edema, which, due to the difference in pressure caused, promotes cellular hypoxia, forcing the brain to use the glycolytic mechanism to obtain energy. However, due to the unsustainability of this route, the accumulation of

local lactic acid promotes the breakdown of the blood-brain barrier and intensifies cell death, which can quickly evolve into a progressive and diffuse condition, with these mechanisms already written, an occurrence in a time window of 4 to 6 hours, such useful information to predict the possible evolution in the prognosis, as well as the observation of radiological alterations [3-5].

As for the evaluation of the TBI patient and its acute management, the hierarchical obedience of the factors in the initial management is of paramount importance, which will promote safety in the treatment and culminate in a better prognosis. It is necessary to recommend, at the initial moment, the assessment of the airways, breathing and circulation being followed by a score on the Glasgow coma scale, which must be repeated at considerable time intervals, given the rapid evolution to complications in certain cases. Furthermore, it is understood that in addition to this initial assessment, the presence of computed tomography in the management of traumatized patients, as well as possibly necessary interventions of intubation orotracheal and decompressive craniotomy, advocate the dimensional recognition of the injury, damage and resulting complications, in order to ensure the improvement and minimization of post-traumatic sequelae [5].

Among the main causes of TBI, we can mention car accidents, pedestrians being run over, cycling and motorcycle accidents, physical aggression, falls, firearm injuries, among other less frequent ones [6-9]. The severity, extent and type of primary injury resulting from the TBI depend on the physical mechanisms and the type of impact (direct or inertial mechanism) that occurred in the trauma and consequently this will affect the degree of recovery of the affected individuals [10]. Thus, the present study aimed to

analyze case reports involving TBI, for the denotation of differential events from the mechanism of injury, initial management, prognosis and the presence of post-traumatic injuries, in order to outline the recovery profile of the victims and their differences.

2. METHODOLOGY

2.1 Search Strategies

This study constituted a review of the literature based on the analysis of case reports about the recovery of TBI victims. For the elaboration of the present study, the search for published reports in the PubMed database in the past five years, the preference for this timeline was due to the high evolution in lines of treatment and in the forms of follow-up of patients who suffered trauma. The following terms were used for the search strategy: Traumatic brain injury, recovery, using the boolean operator "AND".

2.2 Inclusion Criteria

The present study included: case reports published in English and Portuguese and containing information such as: Patient's ages, genders, and complaints, TBI classification treatment, recovery, follow-up, and sequelae of the victims.

2.3 Exclusion Criteria

The following were not included in this study: *post-mortem* studies on TBI, articles that focused on surgical or drug treatment of the affected patient.

2.4 Selection of Studies

Fig. 1 shows the results of the successive screening steps and their respective numbers. Of the total, 8 articles met the criteria established for eligibility.

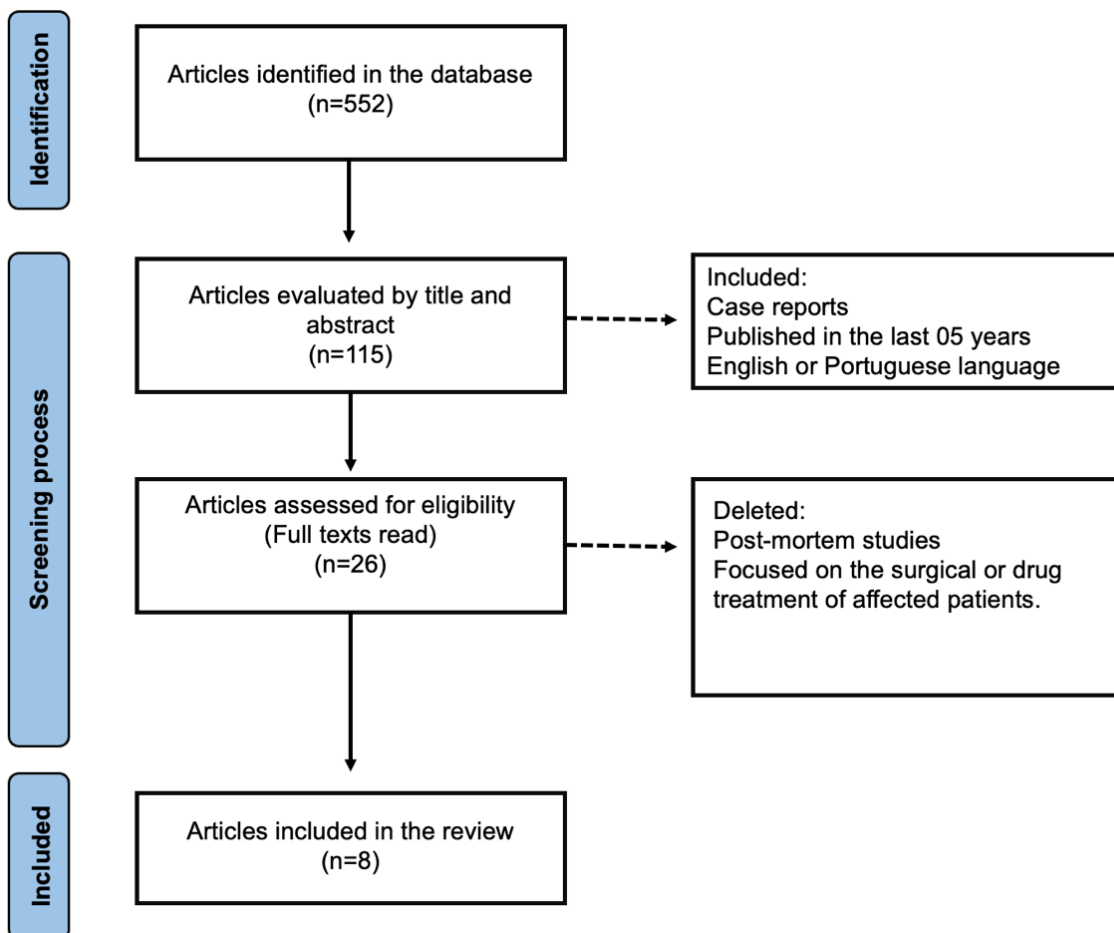


Fig. 1. Information flow and stages of review

3. RESULTS

Based on the established criteria, 08 studies were selected (Table 1) that contained information about the recovery of patients affected by TBI and that contemplated the established selection criteria.

4. DISCUSSION

To understand the recovery profile of patients after TBI, there needs to be an analysis thorough of all the nuances understood from the initial treatment measures, place, care center, injury severity, sequelae, unforeseen future consequences, among other factors that make this type of injury unique among urgent and emergency care. In the cases analyzed in this study, there was evidence of formation of post TBI lioma, endocrine disorders, motor sequelae, among others, in which it is common in several cases for patients to evolve through surgical treatment, which therefore indicates a division between the prognoses through treatment, since the TBI can and tends to evolve with compressive effects and foci hemorrhagic which, consequently, with the increase in pressure intracranial causes death of neurons and accumulation of metabolic substrates after neuronal death. By configuring an emergency situation in such a way that its treatment aims to ensure the full functioning of the other parts of the brain, as well as to avoid the occurrence of a progression of the case.

As for the cases presented, Kui Chen et al. (2022) demonstrates the formation of gliomas as a possible result of trauma, those cell mass tumors that in this context develop between glial cells, are responsible for brain architecture and nutrition and even if their pathogenesis is not completely understood, the criteria of Manuelidis [18] and Moorthy [19], denoted that: previous good health, a period of initial and highlighted incubation, the formation of the glioma in the exact place of the trauma are three factors suggestive of its formation after TBI. Such information strongly suggests a cause/consequence of the local inflammatory process caused by the trauma and the promotion of oncogenic factors due to neural stem cells migrating to the site for repairing the lesion, in addition to the immune response through the secretion of cytokines and reactive species of oxygen, propitiating properties mutagenic to the local.

Yet as a result of TBI, damage can have irreversible consequences that reverberate in all organic functions. A great example of this are the endocrine repercussions presented in cases of damage to the hypothalamus-pituitary axis, whether directly or in the architecture of the rods pituitary or in the gland specifically, or even be secondary to diffuse and communicating axonal damage of that axis. A case described was the one of Astafyeva et al. (2022) in which a peculiarity in the prognosis, the development of DI by a Russian teenager, after TBI in an automobile accident that culminated in a depression of the cranial vault and reaching the sell a turcica. As an initial manifestation of DI, a condition of polyuria 3 days after the injury and the return of full consciousness of the patient only 21 days after the injury, which even with multidisciplinary and continuous treatment with reconstruction of the affected cranial region, the endocrine disorder developed made it permanent in this case, further demonstrating the diverse characterization of post-traumatic sequelae. TBI in the prognostic profile of these patients and denoting negative factors, which transcend the initial intervention and can become permanent even with treatment.

In addition, the major complications faced in the treatment of TBI and in the evolution of the patients' prognosis, include not only the decision to intervention surgical or conservative, when necessary, but also the consequences long-term impact of delayed initial treatment, and the structure of care offered to patients in a precarious way. such a fact could it be demonstrated in the study by Sawa et al. (2021), where the patient suffered delay in care, having as an initial measure only a simple dressing on a time window of 48hrs added to another 5 hours of transfer to the center of more complex healthcare. Such that, temporarily omitted an injury to the brain parenchyma by bone flap, stones and traces not removed after trauma, and among the obstacles caused, it generated the unconsciousness of the victim for a period relative time of 6hrs together with the high cost of tomography in the region (this exam, standard of excellence in management initial) and the absence of bags for blood transfusion that the interventions necessary for the case were delayed. In this way, it is possible to list the structural factor of health care also as a key factor in the evolution and the prognosis of TBI victims.

Table 1. Distribution of selected studies

Title	Patient's ages, genders, and complaints	Treatment, recovery, follow-up, and sequelae of the victims
Post-traumatic brain injury glioma: characteristics, report of 2 cases and literature review [5]	A 57-year-old man arrives at the hospital with ongoing dizziness and headaches. Notably, he had a severe traumatic brain injury (TBI) at 40. Another case involves a 59-year-old man who developed seizures a decade after a serious TBI in the left parietal lobe.	In the initial case, the TBI at 40 years old resulted in glioblastoma in the left temporal region, leading to surgical resection, chemotherapy, and radiotherapy following the Stupp protocol. Similarly, a 59-year-old patient developed an astrocytoma in the left temporo-parietal region years after TBI. This patient had no neurological deficits and received chemotherapy and radiotherapy after surgery.
Delays in a traumatic brain injury: case report [11]	A 22-year-old male patient arrived at the local hospital with an open traumatic brain injury (TBI) following an assault.	At first, the 22-year-old patient received sutures and wound care without further investigation. Two days later, he was referred to a specialized hospital. On arrival, he showed right-sided hemiplegia and aphasia, with stable vital signs and normal pupils. A CT scan indicated pneumocephalus, collapsed left lateral ventricle, and cerebral contusion. Surgery was delayed by 5 days due to logistics. The patient recovered well but developed advancing dysarthria and right-sided hemiparesis.
Permanent diabetes insipidus after traumatic brain injury: case report and literature review [12]	A 16-year-old male patient presented with diabetes insipidus.	The patient was assisted by a complex interdisciplinary network, including motor rehabilitation, psychological support and pedagogical assistance, in addition to pharmacotherapy. This approach significantly improved the subject's behavior and motor skills. However, symptoms such as thirst, polyuria and nocturnal enuresis persist even with desmopressin therapy, requiring replacement by vazomirin. Symptoms remain if the drug is withdrawn.
Penetrating traumatic brain injury resulting from a rooster attack: case report and literature review [13]	A 10-month-old female patient experienced a penetrating traumatic brain injury (TBI) in the right frontal region following an attack by a rooster.	Surgical intervention was undertaken due to intraparenchymal hemorrhage in the right frontal area. Ceftriaxone, ampicillin, and metronidazole were administered to prevent meningoencephalitis. The child was monitored for 2 months by the institution, and a slight left-sided fine motor skill impairment was the sole observed issue.

Title	Patient's ages, genders, and complaints	Treatment, recovery, follow-up, and sequelae of the victims
Excellent recovery of a child after non-missile penetrating traumatic brain injury: Case report [14]	An 11-year-old male patient arrived at the emergency room with a penetrating traumatic brain injury (TBI) caused by a non-missile object measuring 30 cm in the frontal region.	The patient had daily improvement in the level of consciousness, after 6 days of the traumatic event, the patient had completely recovered consciousness and did not have any motor or cranial nerve deficits – he only had a complaint of blurred vision in the left eye. Furthermore, 6 months have passed and he has had no problems related to gross motor and cranial nerve function.
Cerebral venous sinus thrombosis caused by traumatic brain injury complicating thyroid storm: case report and discussion [15]	A 29-year-old male, with a previous diagnosis of Basedow-Graves disease, was admitted to the hospital with a concussive TBI.	The treatment was drug and aimed to control the thyroid storm and reduce thrombogenesis, in addition to respiratory support and analgesia. This patient was followed up for 6 months, after which time he presented recanalization of most of the venous sinuses, but still had some losses in fine motor skills in the right hand and in verbal expression.
Contracoup injury of the prefronto-thalamic tract in a patient with mild traumatic brain injury: case report [16]	A 62-year-old female patient complains of cognitive dysfunction and depressed mood following a mild traumatic brain injury (TBI) with injury to the occipital region 2 months ago.	After initial analysis, various tests were conducted, including MRI in T1, T2, and FLAIR sequences, but only CT with SPECT showed reduced perfusion in both frontal lobes. The patient exhibited neuropsychological impairment, decreased IQ, impaired memory, and moderate depression. Unfortunately, no information was provided regarding the treatment of this patient.
Aphonogelia After Recovery from Severe Traumatic Brain Injury: Case Report [17]	A 16-year-old female patient is brought to the emergency room after a car accident. She had a Glasgow Coma Scale (GCS) score of 6.	The patient had intraparenchymal hemorrhage in the right temporal lobe, subarachnoid hemorrhage in the sulcus of the right parietal lobe, and intraventricular hemorrhage. Initial treatment was conservative, including intubation and mechanical ventilation; she stayed in the ICU for 3 weeks in a coma. Follow-up lasted a year after the injury, showing impressive recovery despite the accident's severity. She faced gross motor problems but her main sequela was the inability to laugh (aphonogelia).

From this perspective, it is clear that the causes of TBI are diverse, and may be, for example, the result of an animal attack. However, a case report by Maksoud et al. (2019) describes a penetrating brain injury generated by a rooster attack, in this case, a 10-month-old child was attacked by the animal that struck his head with its beak. After closing the lesion in the frontal region with skin

glue, the patient was released with specific instructions. It is not surprising that shortly after arriving at her home, the child suffered a focal epileptic seizure in her left arm, had several episodes of emesis and developed an ocular deviation. An MRI was performed which revealed an intraparenchymal hemorrhage in the right frontal lobe resulting from the injury caused by the animal. In view of the rapidly deteriorating situation, there was surgical intervention with craniotomy. The patient was referred to the pediatric ward and received antibacterial treatment due to possible encephalitis and meningitis. Due to the location of the injury, she had loss of fine movement on the left side.

Other cases are surprising and sometimes unbelievable, such as the one reported by Yousif et al. (2022), which describes an excellent recovery of a pediatric patient after a severe TBI penetrating. In short, this work in question describes the case of an 11-year-old boy who presented to the emergency room with lowered consciousness - Glasgow coma scale 6 - after being hit in the head by a 30 cm metallic object, that extended from his forehead to the central zone of the base of the skull. After CT without conclusive results, the decision was surgical intervention to solve the problem. Subsequently, postoperatively, the patient received daily follow-up and, surprisingly, had no motor or cranial nerve deficits, leaving the hospital with a complaint of blurred left vision and nothing else. As you can see, some cases are exotic and others surprising, revealing that traumatic brain injuries are multifaceted. In the report published by McLeod et al. (2019) a rather unusual complication was also demonstrated. After a car accident, the patient had aphonogelia (inability to smile loudly), when observed in the literature, few cases associated with this condition are found, which strengthens the hypothesis that a TBI can lead to several consequences that are still little evidenced.

From this perspective, the case reported by Gong et al. (2022), describes a cerebral venous sinus thrombosis caused by a TBI, something

that complicated a thyroid storm – this case shows the strong relationship between the pituitary axes and accidents of this type. This patient in question was 29 years old when he was a victim of TBI, another important point was his previous primary hyperthyroidism - Basedow-Graves disease. However, the main problem developed eight days after the accident, when he showed signs of thyroid storms - that is, tachycardia, hyperthermia, sweating and irritability - in addition, he had abnormal thyroid blood tests, and that's when he fell into a deep coma. After 6 months of follow-up, the patient showed some impairment of fine motor skills in the right hand and difficulty in verbal expression.

5. CONCLUSION

The recovery profile of TBI patients can vary depending on the severity and extent of brain damage. These patients usually undergo a multidisciplinary rehabilitation process aimed at promoting functional recovery and improving quality of life. In the early stages of recovery, it is common for patients to have physical, cognitive, and emotional impairments. In addition, neuropsychological rehabilitation is essential to treat cognitive deficits, such as memory, attention, concentration and reasoning problems.

In the present study, different sources of trauma can be observed and, therefore, several paths for an intervention aimed at recovering the affected individual. Trauma ranged from injuries with domestic animals to car accidents, which are the main causes of TBI today. In addition, the recovery of those affected showed great discrepancies, where in some cases the sequelae became very evident, as in the case of aphonogelia. Due to the great social and economic losses that TBI causes to the State nowadays, and the growing trend of new cases, especially of patients with sequelae of this condition, it is necessary to study more about the characteristics, causes and health costs generated by victims of TBI.

CONSENT

It is not applicable.

ETHICAL APPROVAL

It is not applicable.

COMPETING INTERESTS

Authors have declared that no competing interests exist.

REFERENCES

1. Capizzi A, Woo J, Verduzco-Gutierrez M. Traumatic brain injury: An overview of epidemiology, pathophysiology and medical management. *Med Clin North Am.* 2020;104(2):213-238. DOI: 10.1016/j.mcna.2019.11.001
2. Eapen B, Cifu D. Rehabilitation after traumatic brain injury. St. Louis (MO): Elsevier Inc.; 2018.
3. Cucurullo SJ. Head trauma. In: Cucurullo SJ, editor. Physical medicine and rehabilitation board review. 2nd edition. New York: Demos Medical. 2010;49–50, 51–3, 90–1.
4. Dixon KJ. Pathophysiology of traumatic brain injury. *Phys Med Rehabil Clin N Am.* 2017;28(2):215-225. DOI: 10.1016/j.pmr.2016.12.001
5. Chen K, Andrade-Barazarte H, Liang W, et al. Post-traumatic brain injury glioma: Characteristics, report of 2 cases report and literature review. *Medicine (Baltimore).* 2022;101(52):e32477. DOI: 10.1097/MD.00000000000032477
6. Krauss JF, McArthur DL. Epidemiology of brain injury. In Evans RW. (ed). *Neurology and trauma.* Houston: Saunders, 1996:3-17.
7. Mackenzie EJ. Epidemiology of injuries: current trends and future challenges. *Epidemiol Rev.* 2000;22:112-119.
8. Kay A, Teasdale G. Head injury in the United Kingdom. *World J Surg* 2001;25: 1210-1220.
9. Melo JRT, Silva RA, Silva LGA, Hermida MB. Characteristics of craniofacial trauma at the General Hospital of the State of Bahia, Brazil. *Ciência e Saúde.* 2003;3:31-35.
10. Brock RS, Cerqueira DPSS. Craniofacial trauma. Disponível em; 2008. Available.http://www.medicinanet.com.br/c_onteudos/revisoes/1175/trauma_de_cranio.htm>
11. Sawa B, Assoumane I, Ngoko Y, Chaibou Sode H, Sanoussi S. Delays in a traumatic brain injury: A case report. *Trop Doct.* 2022;52(1):147-150. DOI: 10.1177/00494755211055539
12. Astafyeva LI, Sidneva YG, Badmaeva IN, et al. Permanent central diabetes insipidus after traumatic brain injury. Case report and literature review. *Zh Vopr Neurokhir Im N N Burdenko.* 2022;86(5):112-118. DOI: 10.17116/neiro202286051112
13. Maksoud S, Lawson McLean A, Bauer J, Schwarz F, Waschke A. Penetrating traumatic brain injury resulting from a cockerel attack: case report and literature review. *Childs Nerv Syst.* 2020;36(5):1067-1070. DOI: 10.1007/s00381-019-04441-4
14. Yousif RS, Omar AM, Ismail M, Hamouda WO, Alkhafaji AO, Hoz SS. Excellent recovery after nonmissile penetrating traumatic brain injury in a child: A case report. *Surg Neurol Int.* 2022;13:388. DOI: 10.25259/SNI_350_2022
15. Gong S, Hong W, Wu J, et al. Cerebral venous sinus thrombosis caused by traumatic brain injury complicating thyroid storm: A case report and discussion. *BMC Neurol.* 2022;22(1):248. DOI: 10.1186/s12883-022-02777-0
16. Jang SH, Kwon YH, Lee SJ. Contrecoup injury of the prefronto-thalamic tract in a patient with mild traumatic brain injury: A case report. *Medicine (Baltimore).* 2020; 99(32):e21601. DOI: 10.1097/MD.00000000000021601
17. McLeod SA, Lam A, Spencer A, Wei XC, Gnanakumar V. Aphonogelia After Recovery from Severe Traumatic Brain Injury: A Case Report. *PM R.* 2019;11(1): 94-97. Doi: 10.1016/j.pmrj.2018.05.018
18. Manuelidis EE. Glioblastoma multiforme. In: *Pathology of the nervous system.* 1971: 2237–40.
19. Moorthy RK, Rajshekhar V. Development of glioblastoma multiforme following traumatic cerebral contusion: Case report and review of literature. *Surg Neurol.* 2004; 61(2):180-184. DOI: 10.1016/s0090-3019(03)00423-3

© 2023 Brito et al.; This is an Open Access article distributed under the terms of the Creative Commons Attribution License (<http://creativecommons.org/licenses/by/4.0>), which permits unrestricted use, distribution, and reproduction in any medium, provided the original work is properly cited.

Peer-review history:
The peer review history for this paper can be accessed here:
<https://www.sdiarticle5.com/review-history/104721>