



Efficacy of Ascorbic Acid in Reducing Glyphosate-Induced Toxicity in Rats

E. V. Ikpeme¹, O. Udensi^{1*}, U. B. Ekaluo¹ and T. O. Solomon¹

¹*Department of Genetics and Biotechnology, University of Calabar, PMB 1115, Calabar, Nigeria.*

Authors' contributions

This work was carried out in collaboration between all authors. EVI designed the study and wrote the protocol; OU performed the statistical analysis, interpreted and formatted the final manuscript; UBE wrote the first draft of the manuscript while TOS did the bench work and literature search. All authors read and approved the final manuscript.

Research Article

Received 11th June, 2012
Accepted 19th August 2012
Online Ready 19th October 2012

ABSTRACT

Aim: Humans and animals interact with their environments on a daily basis and, as a consequence, are exposed to a broad spectrum of synthesized chemicals present in the food they eat, the air they breathe and the water they drink including glyphosate. This study was aimed at investigating the effects of glyphosate on the sperm dynamics of male albino rats and the protective effects of ascorbic acid.

Methods: Twenty five mature male albino rats were weighed and divided into five groups in a completely randomized design (CRD). Group 1 rats served as the control. Rats in groups 2 and 4 received 250ml/kg and 500ml/kg of glyphosate while groups 3 and 5 rats were administered with 250ml/kg and 500ml/kg of glyphosate and 200mg/kg of ascorbic acid, respectively, which were administered orally using oral gavages. The treatment regimen lasted for 65 days.

Results: Our results showed that there were significant adverse effects ($P < 0.05$) of glyphosate treatment on sperm parameters and the cyto-architecture of the gonad, which showed disruption in the seminiferous tubules, necrotic germinal epithelium and clumped Leydig cells. However, administering the rats with ascorbic acid caused significant ameliorating effects on the parameters investigated.

Conclusion: Succinctly, glyphosate exposure to animals is detrimental to their reproductive physiology, including the cellular integrity of the gonads. This not

*Corresponding author: Email: princeuou4u@yahoo.com; ugorji2012@gmail.com; ekeivikpeme@gmail.com;

notwithstanding, administering the affected animals with ascorbic acids might reduce the toxicity inflicted by the glyphosate.

Keywords: Ascorbic acid; glyphosate; gonads; rats; sperm profile; toxicity.

1. INTRODUCTION

Humans and livestock interact with their environment and consequently are exposed to broad spectrum of synthesized chemicals present in the food they eat, water they drink and the air they breathe. One of such chemicals is glyphosate.

Glyphosate [N-(phosphonomethyl) glycine] is a water-soluble, non-selective herbicide applied to foliage resulting in death of most herbaceous plant (Kremer and Means, 2009). The mode of action is usually the inhibition of the enzyme 5-enolpyruvyl-shikimate-3-phosphatase synthase (EPSPS) in the shikimic acid pathway. This however, blocks the synthesis of essential aromatic amino acids and precursors of other critical aromatic compounds, which includes plant growth regulators and phytoalexins (Duke et al., 2003).

Critically, glyphosate as an extremely effective herbicide remains intact in the plant with little degradation and is systematically transported to metabolically active sites throughout the plant before inducing symptoms (Cerqueira and Duke, 2006). In a recent demonstration, agricultural soils amended with phosphorus fertilizers are high in unbound glyphosate because soil sorption sites are occupied by competing phosphonate ions; thus, glyphosate remaining in the soil solution is vulnerable to potential uptake by plant roots, microbial metabolism, or leaching into groundwater (Simonsen et al., 2008). According to Neumaann et al. (2006) glyphosate released through the roots of dying plants was transferred to living plants (not treated with glyphosate) via root absorption and suggested that glyphosate applied to vegetation in orchard alleys may be similarly transferred to trees causing disease and yield losses.

Descalzo et al. (1996), Kuklinshy-Sobral et al. (2005) opined that glyphosate exhibit non-herbicidal effects manifested by enhancement or suppression of the activity of latent pathogenic and/or plant growth-promoting bacteria and fungi, which may subsequently impact on growth of non-target plants. A new weave of technology in weed management is the production of transgenic crops resistant to glyphosate. This may reduce pre-emergence herbicide use and better conserve soils by increasing the use of no-tillage.

Important of note is the fact that this chemical when sprayed could be inhaled by either the sprayer or passerby or even livestock, which may lead to serious health-related effects. Studies have however shown that glyphosate has serious toxic effects on health and the environment. Being an endocrine disruptor in human cells, it has been reported to induce DNA damage in human cells; interferes with the physiological DNA repair machinery, leading to genomic instability and possible cancer development. It was also reported that the adjuvant damage human placental cells and human embryonic cells.

This paper is therefore imperative giving the different submissions by researchers. It should be understood that spermatogenesis is endocrinal-linked process and as such any disruption may lead to severe dysfunction to the process. It is our understanding that Vitamin C being

an antioxidant could exert ameliorating effect when glyphosate-induced damage occurs. It is on this premise that this paper finds credence.

2. MATERIALS AND METHODS

2.1 Experimental Animals

Twenty five sexually matured male albino rats were purchased from the animal house of the Department of Zoology and Environmental Biology, University of Calabar, Calabar. Glyphosate was purchased from Cross River Agricultural Development Project (CRADP). The rats were maintained under standard conditions of humidity, temperature and standard chow (feed) and tap water was given *ad libitum*. The rats were allowed to stabilize for a period of one week. This study was conducted in accordance with the declaration of Helsinki on the guiding principles in care and use of animals.

2.2 Experimental Procedure

The twenty five rats were divided into five groups of five rats each in a completely randomised design (CRD). Rats in group 1 served as the control while rats in groups 2 and 3 received 250ml/kg of glyphosate in the morning while rats in group 3 received 200mg/kg of ascorbic acid dissolved in 1ml of distilled water in the evening. Additionally, rats in group 4 and 5 received 500ml/kg of glyphosate and group 5 rats received 200mg/kg of ascorbic acid in the morning and evening. These administrations were done through oral gavage for 65 days (Note: the oral lethal dose of glyphosate for rat is 5000mg/kg while ascorbic acid is 1900mg/kg) (Copping, 2002). At the end of the treatment regimen, they were sacrificed under chloroform anaesthesia. The testes and epididymes were dissected and weighed.

2.3 Data Collection

Data were collected on the following parameters: sperm motility, sperm count, sperm viability, sperm morphology, semen pH and weight of organs (testes and epididymes).

2.3.1 Sperm quality analysis

2.3.1.1 Estimation of sperm count

This was carried out according to the method of Ekaluo et al. (2008). The epididymal content was obtained by macerating with fine scissors known weights of the caput and cauda epididymes in a glass petridish containing physiological saline in the ratio of 1:10w/v. After vigorous pipetting, the suspension was separated from tissue fragments by filtering it through an 80µm stainless mesh. The sperm cells were counted by cytometry. Five different counts were done for each sample and the mean were taken as the mean count for each male rat.

2.3.1.2 Evaluation of sperm motility

The sperm cell suspension was diluted in 2ml of physiological saline and dropped on glass slides. This was viewed under light microscope as to determine the motile and non – motile sperm cells by their movement (WHO, 1992).

2.3.1.3 Sperm viability determination

This was estimated using the improved one step eosin-nigrosin staining technique. A fraction of each suspension of the sperm samples was mixed with equal volume of eosin – nigrosin stain and air dried smears were prepared on glass slides for each samples according to Bjorndahl et al. (2003). The slides were coded randomly and examined under the microscope for percentage viability. Normal live sperm cells exuded the eosin – nigrosin while dead sperm cells took up the stain. Percentage viability was calculated based on the number of viable (live) sperm cells divided by the number of sperm cells within 30 minutes multiply by 100.

2.3.1.4 Sperm head abnormality test

A portion of the sperm suspension was mixed with 1% eosin Y solution (10:1) for 30 minutes and air-dried smears were prepared on glass slides for the sperm head abnormality test. The slides were examined for percentage sperm head abnormalities in every 200 spermatozoa observed on each slide and five air-dried smears were prepared on glass slides for each sample. The percentage of sperm head abnormality was calculated according to Ekaluo et al. (2009).

2.3.1.5 Estimation of weight of organs

The testes and epididymis were weighed using an electronic weighing balance (model – Scout Pro SPU 601 [600g]) and the results were recorded.

2.3.2 Histological method/processing (tissue processing)

The tissues were fixed in Bouin's fluid for twenty four hours and were dehydrated through ascending grades of alcohol (two changes one hour each namely: 70%, 95% and absolute alcohol). The tissues were cleared in two changes of xylene (one hour each) and were infiltrated in molten paraffin wax at 60°C. Three changes were made (one hour each) and the tissues were embedded in pure paraffin wax to make tissues blocks. Sections of the tissue were made with a microtome at 5 μ . The sections were floated on a water bath and picked on clean albumenized slides and dried for staining in an incubator. Haematoxylin and Eosin (H&E) staining method was used to stain the sections. The sections were waxed in two changes of xylene, passed through absolute, 70% and 95% alcohols and rinsed in water. The sections were stained in haematoxylin for fifteen minutes, rinsed in water and differentiated in 1% alcohol and placed under several changes of fresh water for thirty minutes until the sections were quite blue and stained in eosine for three minutes, rinsed in water and dehydrated in ascending grades of alcohol (70%, 95% and absolute alcohols) and cleared in xylene. The sections were mounted with cover slips using DPX mounting media (synthetic media composing dystrine and propylene dissolved in xylene solvent). The impact of the co-administration of ascorbic acid was estimated by counting the lesions under 15 microscopic fields and then comparison was made. The degree of lesion was encoded thus; + (moderate), ++ (high) and +++ (very high).

2.4 Statistical Analysis

The data collected were subjected to analysis of variance (ANOVA). Least significant difference (LSD) test was used to separate the means where significant differences were observed (Obi, 2002).

3. RESULTS AND DISCUSSION

3.1 Results

3.1.1 Sperm parameters

Our results showed that there were significant adverse effects ($P < 0.05$) of glyphosate treatment on sperm parameters. However, administering the rats with ascorbic acid caused significant ameliorating effects on the parameters investigated.

For sperm count, the rats in the control treatment had the highest sperm count. However, treating with glyphosate caused a significant decrease of 34.23% and 32.16% at 250ml/kg and 500ml/kg doses, respectively. Administering the rats that received the glyphosate treatment with ascorbic acid at the dose of 200mg/kg resulted to significant increase ($P < 0.05$) in the sperm count.

There was no significant difference ($P > 0.05$) observed for the sperm motility of rats in the control and those treated with 250ml/kg of glyphosate. There was slight difference between the sperm motility of rats treated with 250ml/kg and those treated with 500ml/kg. Ascorbic acid administration caused significant increase in the motility of the sperm cells. Glyphosate treatment reduced sperm viability, especially at 500ml/kg while for sperm head abnormality; there was significant increase after treating with glyphosate. While ascorbic acid resulted to increase in sperm viability, it caused decrease in percentage of sperm head abnormality.

Additionally, testicular weight was not significantly difference even after treating with glyphosate and ascorbic acid. However, epididymal weight was significantly reduced at 500ml/kg of glyphosate but increased when ascorbic acid was administered (Table 1).

3.1.2 Histology of the gonad

The treatment of rats with glyphosate caused several degrees of lesions on the cyto-architecture of the gonad, which was dose-dependent. Treating rats with 250mg/kg resulted to hyperplasia of the interstitial areas (Leydig cells) due to inflammatory cells invasion. There was necrosis of the germinal epithelium and the lesions observed were high (++) . Rats administered with 500mg/kg had their seminiferous tubules detached. The interstitial vessels were dilated, congested with evidence of stasis. The tissue was oedematous having a very high degree of lesions (+++). However, co-administering with ascorbic acid reduced the degree of lesion moderately (+) (figs. 1 to 5).

Table 1. The effects of glyphosate and ascorbic acid on the organ weights and sperm parameters of male albino rats

Parameters	Control	Concentrations in ml/kg			
		250	250 + Vit. C	500	500 + Vit. C
Sperm motility (%)	24 ^a ±2.45	38.00 ^a ±2.21	42 ^{ab} ±2.00	46.00 ^b ±1.23	56.00 ^{bc} ±2.34
Sperm viability (%)	53 ^{ab} ±4.35	56 ^{ab} ±2.45	58 ^{bc} ±4.89	38.00 ^a ±0.68	42 ^a .00 ±5.82
Sperm head abnormality (%)	30.00a±0.45	66.00b±0.85	23.00a±1.01	68.2b±1.23	20.00a±0.43
Sperm count (x10 ⁶ /ml)	97 ^e ±0.83	63.8 ^a ±3.65	78.4 ^c ±3.07	65.8 ^{ab} ±1.35	85.2 ^{cd} ±3.27
Testis weight (g)	1.16 ^a ±0.05	1.1 ^a ±0.05	1.01 ^a ±0.04	1.11 ^a ±0.02	1.13 ^a ±0.02
Epididymes weight (g)	0.35 ^b ±0.12	0.33 ^{ab} ±0.1	0.31 ^{ab} ±0.03	0.26 ^a ±0.01	0.38 ^b ±0.04

* Means followed with the same superscript along each horizontal array indicate no significant difference ($P > 0.05$)

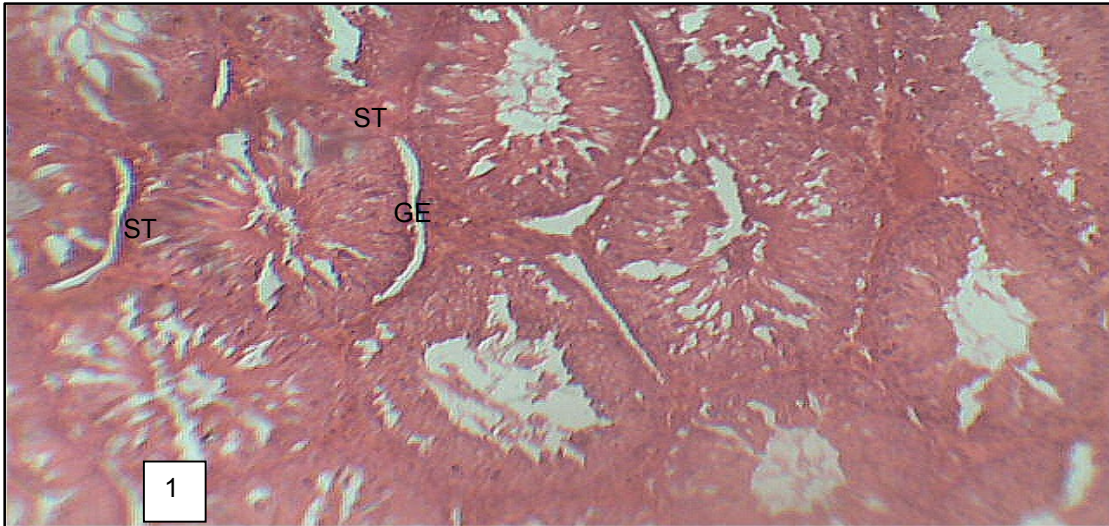


Fig. 1. Seminiferous tubules (ST) with normal germinal epithelium (GE) with normal tissues (Control; H/E; X100)

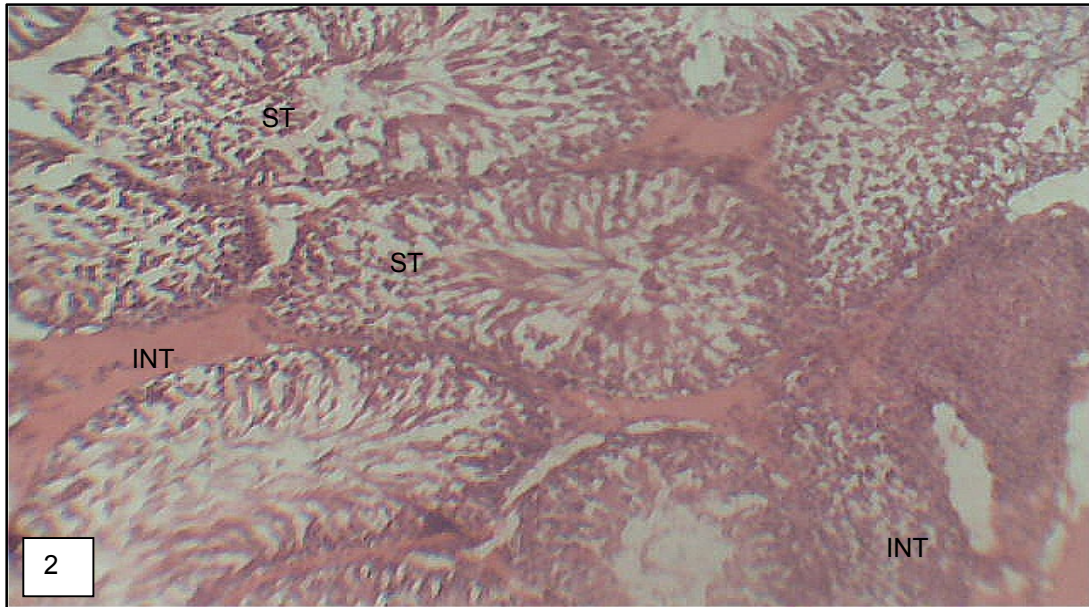


Fig. 2. Congested interstitium (INT) with some interstitial areas bulky and hyperplastic due to inflammatory cells invasion, seminiferous tubules (ST) with necrotic germinal epithelium. (250ml/kg of glyphosate; H/E; X100)

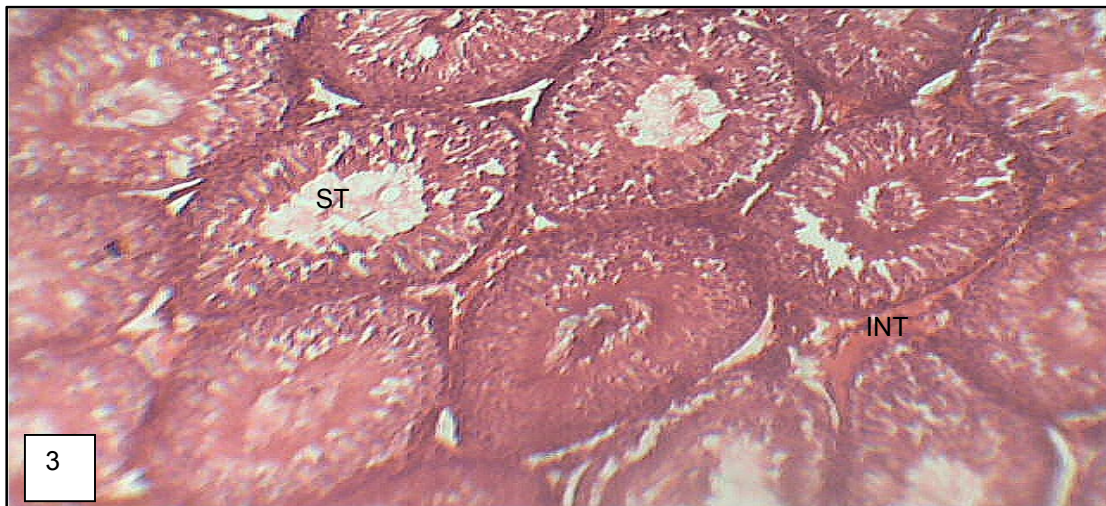


Fig. 3. Photomicrograph of testis showing repaired damaged seminiferous tubules and congested interstitial vessels. Germinal epithelium looks normal (250ml/kg of glyphosate + 200mg/kg of ascorbic acid)

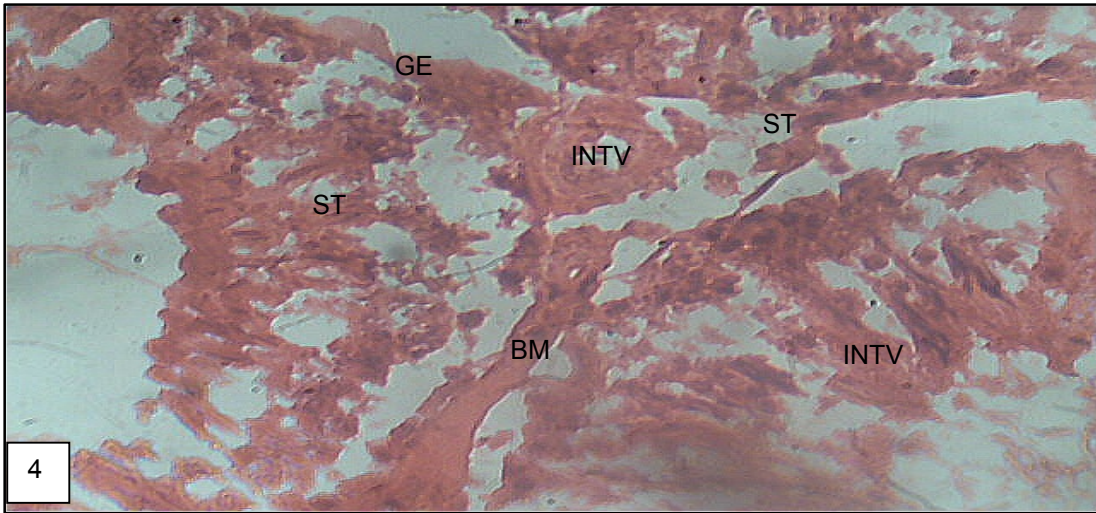


Fig. 4. Seminiferous tubules (ST) with necrotic germinal epithelium (GE), detached from the basement membrane (BM). The interstitial vessels (INTV) are dilated, congested with evidence of stasis. The whole tissue is oedematous. Inflammatory cells are however not seen (500ml/kg of glyphosate; H/E X400)

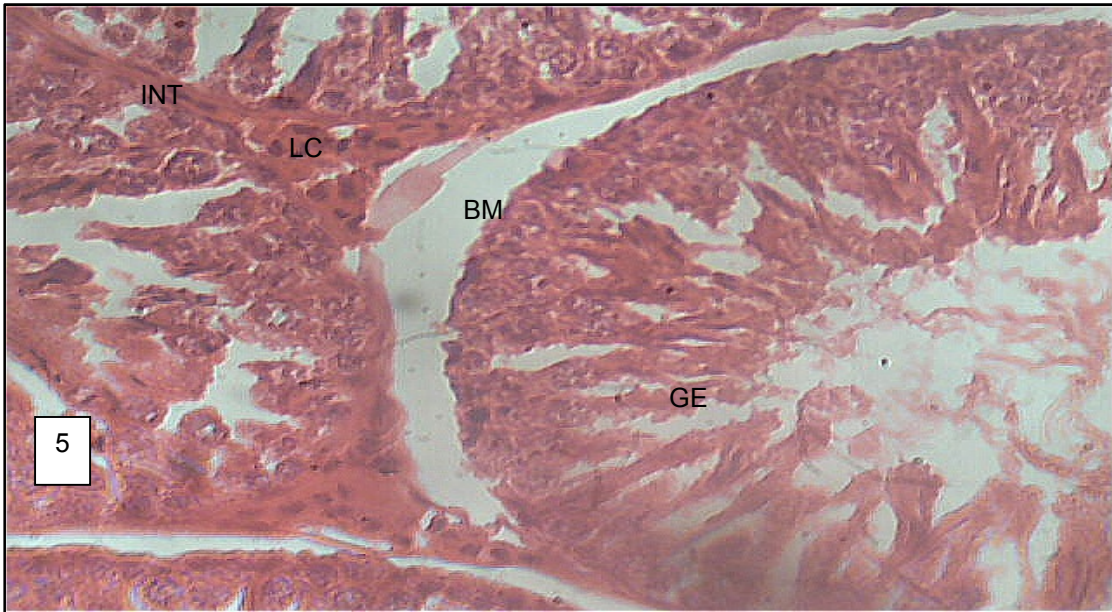


Fig. 5. Seminiferous tubules with poorly maturing germinal epithelial cells resting on intact basement membrane. Leydig cells look normal (500ml/kg of glyphosate + 200mg/kg of ascorbic acid)

3.2 Discussion

Though glyphosate has been observed to non-selectively cause the death of most herbaceous plants, its actions however, has not been without hazardous effects to non-targeted plants, animals and environment (Cerqueira and Duke, 2006; Simonsen et al., 2008; Haney et al., 2000). Glyphosate has caused severe damage to crops, which it was meant to protect by decreasing nutrient availability to plants, increased plant susceptibility to diseases, etc. Research has indicated that plants sprayed with glyphosate or other herbicides are more susceptible to many biological and physiological disorders (Babiker et al., 2011; Larson et al., 2006; Means and Kremer, 2007; Descalzo et al., 1996).

One will begin to imagine the safety of humans and livestock that will either inhale or take these chemicals into their systems through any means. According to Benachour and Seralini (2009), Gasnier et al. (2009), glyphosate is an endocrine disruptor. Though the hormonal profile analysis was not carried out in this current paper, it is rather probable that the treatment may have disrupted the synergy between testosterone and follicle stimulating hormone during the process of spermatogenesis (Ikpeme et al., 2010; Gelatin et al., 2005; Ekaluo et al., 2011). Ikpeme et al. (2010) assertively revealed that the distortion in fertility in male mammals is directly correlated with the disruption of spermatogenesis and the hormone regulatory machineries. This might partly underscore our present results on the effect of glyphosate on sperm parameters. Abarikwu et al. (2009) reported a dose-dependent adverse effect of atrazine on the testicular and epididymal sperm numbers, motility, viability morphology and daily sperm production. This however, confirms the work of Sifakis et al. (2011) about pesticides including glyphosate. Our results revealed that the administration of glyphosate to rats at different doses caused significant toxicity effects to testicular integrity, which might be the underlying cause of the effects on sperm profile. Mohammed et al. (2004) has earlier reported that alteration of testicular cells maligned spermatogenesis. Thus the reduction in sperm count could be linked to the alterations of this cellular machinery underlying sperm cells production (Ikpeme et al., 2010). It is very likely that the glyphosate or adjuvant may have acted during the spermatogonial stage instead of the spermatid formation phase. This was the positions of Sharpe (1992), Ikpeme et al. (2010). Additionally, the permeation of glyphosate/adjuvant through the blood-testis barrier after treatment may have as well led to sperm motility reduction. The adverse affect of glyphosate on sperm head may be attributed to the direct cyto-toxic effect on the epididymis (Fatma et al., 2009).

The influence of hormones during spermatogenesis notwithstanding, it is obvious that the integrity of the cyto-architecture of the gonads is also very important in the process of sperm production. Sakr and Azalo (2001) reported reduction in the diameter of seminiferous tubules and the degeneration of Leydig cells after rats had inhaled pyrethroid. Similarly, Rani et al. (2007) observed that rats exposed to carbaryl showed distorted seminiferous tubules, accumulation of cellular mass in the lumen of the testis and loss of sperm in varying degrees. The actions of the above reported chemicals may also be applicable to the glyphosate administration whose distorting effects on the testicular cells were evident. Pesticide exposure disrupts the reproductive system as they have estrogenic and anti-androgenic properties. Specifically, atrazine reduces testicular testosterone in male rats and it is associated with poor semen quality. It also causes disorganization of histo-architecture of the gonads, degeneration in some areas of the seminiferous epithelium and the existence of necrotic features (Sifakis et al., 2011). This is similar to our current report on glyphosate. It is probable that glyphosate impairs reproductive function and elicits a depletion of

antioxidant defense system in the testis and epididymis of the rats, indicating the induction of oxidative stress. The administration of ascorbic acid may have compensated this depletion.

Important possibility is the fact that glyphosate treatment might have as well affected the thyroid gland of the rats. According to Udoh et al. (2010), treating rats with *Ipomea batatas* induced hypertrophy and hyperplasia in the morphology of the thyroid gland. This pathology stage could lead to altered production of sex hormones binding globulin and sex hormone metabolic pathways and clearance rates (Knudson, 1995). The alteration in the function of the gland might also influence negatively spermatogenesis and subsequently fertility (Krassas and Pontikides, 2004; Lohiya et al., 2008). Since thyroidectomy inhibits spermatogenesis and development of Leydig cells (Udoh et al., 2005), it does therefore mean that any action that affect the thyroid gland adversely could spell doom for reproduction, especially in males. Udoh et al. (2010) opined that pathological changes observable in the thyroid gland could lead to impaired sperm motility, oligospermia, asthenospermia and in fertility in man. This might be the situation with glyphosate treatment.

Our present results corroborate the report of Salah et al. (2009); Nashwa and Venes (2008) that Ascorbic acid administration decreases sperm abnormalities and increases sperm count, motility and viability. Though, the mode of action is not very clear in the present study, ascorbic acid has been reported to aid in the maintenance of healthy connective tissues and the integrity of the cell walls. Being an antioxidant, it is involved in the prevention of cellular damage by safely interacting with free radicals and terminating the chain reaction before vital molecules are damaged. It also removes free radical intermediates and inhibits other oxidative reactions. Possibly, the administration of glyphosate to rats may have released so much free radical into the rat's system, which might have invariably induced the distortions observed in the cells of the gonad. Expectedly, treating with ascorbic acid may have mopped up the released free radicals, thus maintaining the integrity of the cells.

4. CONCLUSION

Succinctly, glyphosate exposure to animals is detrimental to their reproductive physiology, including the cellular integrity of the gonads. This notwithstanding, administering the affected animals with ascorbic acids might reduce the toxicity inflicted by the glyphosate.

COMPETING INTERESTS

Authors have declared that no competing interests exist.

REFERENCES

- Babiker, E.M., Hulbert, S.H., Schroeder, K.L., Paulitz, T.C. (2011). Optimum timing of preplant applications of glyphosate to manage Rhizoctonia root rot in barley. *Plant Disease*, 95, 304-310.
- Benachour, N., Séralini, G.E. (2009). Glyphosate formulations induce apoptosis and necrosis in human umbilical, embryonic and placental cells. *Chem. Res. Toxicol*, 22, 97-105.
- Bjórndahl, L., Sódourlund, I., Kvist, U. (2003). Evaluation of the one-step eosin-nigrosin staining technique for human sperm vitality assessment. *Human Reproduction*, 18, 813-816.

- Cerdeira, A.L., Duke, S.O. (2006). The current status and environmental impacts of glyphosate-resistant crops: a review. *J. Environ. Qual*, 35, 1633–1658.
- Copping, L.G. (2002). Post emergence herbicide. *Agrow Report*, 230, 180.
- Descalzo, R.C., Punja, Z.K., Levesque, C.A., Rahe, J.E. (1996). Identification and role of pythium species as glyphosate synergists on bean (*Phaseolus vulgaris*) grown in different soils. *Mycological Res*, 100, 971-978.
- Duke, S.O., Rimando, A.M., Pace, P.F., Reddy, K.N., Smeda, R.J. (2003). Isoflavone, glyphosate and aminomethylphosphonic acid levels in seeds of glyphosate-treated, glyphosate-resistant soybean. *J. Agric. Food Chem*, 51, 340–344.
- Ekaluo, U.B., Ikpeme, E.V., Udokpoh, A.E. (2009). Sperm head abnormality and mutagenic effects of aspirin, paracetamol and caffeine containing analgesics in rats. *The Internet J. Toxicol*, 7(1).
- Ekaluo, U.B., Udokpoh, A.E., Ikpeme, E.V., Peter, E.U. (2008). Effect of chloroquine treatments on sperm count and weight of testes in male rats. *Global J. Pure and Applied Sci*, 14, 175-177.
- Fatma, G.U., Suna, K., Dilek, D., Filiz, D., Yusuf, K. (2009). Malathion induced testicular toxicity in male rats and the protective effect of vitamins C and E. *J. Food chem. Toxicol*, 47, 1903-1908.
- Gasnier, C., Dumont, C., Benachour, N., Clair, E., Chagnon, M.C., Séralini, G.E. (2009). Glyphosate based herbicides are toxic and endocrine disruptors in human cell lines. *Toxicology*, 262, 184-191.
- Gelain, D.P., Casali, E.A., Dal-Pizzol, F. (2005). Effect of FSH and vitamin A upon purinergic secretion by rat Sertoli cells. *Mol. Cell Biochem*, 278, 185-195.
- Haney, R.L., Senseman, S.A., Hons, F.M., Zuberer, D.A. (2000). Effect of glyphosate on soil microbial activity and biomass. *Weed Sci*, 48, 89–93.
- Ikpeme, E.V., Udensi, O., Ekaluo, U.B., Efieneokwu, N. (2010). Biological response of male wistar rats to crude extract of *Ficus exasperata* (VAHL). *Int. J. Current Res*, 7, 9-13.
- Knudson, P.B. (1995). Hypothyroidism in adults: variable clinical presentation and approaches to diagnosis. *J. Am. Board Fam. Pract.*, 8, 109-113.
- Krassas, G.E., Pontikides, N. (2004). Male reproductive function in relation with thyroid alterations. *Clin. Endocrinol.*, 65(4), 446-452.
- Kremer, R.J., Means, N.E. (2009). Glyphosate and glyphosate-resistant crop interactions with rhizosphere microorganisms. *Europ. J. Agronomy*, 31, 153–161.
- Kuklinshy-Sobral, J., Welington, L.A., Mendes, R., Pizzirani-Kleiner, A.A., Azevedo, J.L. (2005). Isolation and characterization of endophytic bacteria from soybean (*Glycine max*) grown in soil treated with glyphosate herbicide. *Plant Soil*, 273, 91–99.
- Larson, R.L., Hill, H.L., Fenwick, A., Kniss, A.R., Hanson, L.E., Miller, S.D. (2006). Influence of glyphosate on Rhizoctonia and Fusarium root rot in sugar beet. *Pest Management Sci*, 62, 1182-1192.
- Lohiya, N.K., Boomi, M., Goyal, S., Ansari, A.S. (2008). Sperm motility inhibitory effect of the benzene chromatographic fraction of the chloroform extract of the seeds of carica papaya in langur monkey, presbytis entellus entellus. *Asian J. Androl*, 10(2), 298-306.
- Means, N.E., Kremer, R.J. (2007). Influence of soil moisture on root colonization of glyphosate-treated soybean by *Fusarium* species. *Comm. Soil Sci. Plant Anal*, 38, 1713–1720.
- Mohammad, J.G., Vahid, K., Ramin, A., Mohsen, N., Mohammad, A. (2004). Effect of *Achillea santolina* on mice spermatogenesis. *Daru*, 12(1), 36-39.
- Nashwa, A., Venes, Y. (2008). Impact of vitamin C on genotoxicity, sperm abnormalities and serum biochemical alterations in deltamethrin exposed rats. *Egyptian J. Clin. Path*, 21(1), 168-188.

- Neumann, G., Kohls, S., Landsberg, E., Stock-Oliveira Souza, K., Yamada, T., Römheld, V. (2006). Relevance of glyphosate transfer to non-target plants via the rhizosphere. *J. Plant Dis. Protect*, 20, 963–969.
- Obi, J.U. (2002). Statistical methods of determining differences between treatment means and research methodology issues in laboratory and field experiments, SNAAP Press, Enugu.
- Rani, A., Sahai, A., Srivastava, A.K., Rani, A. (2007). Cabaryl induced histopathological changes in the testis of albino rats. *J. Anatomy Soc*, 56(1), 4-6.
- Sakr, S.A., Azalo, A.E. (2001). Effect of pyrethroid inhalation on the testis of albino rat. *Pak. J. Biol. Sci*, 4(4), 498-500.
- Salah, S.H., Abdou, H.S., AbdelRahin, E.A. (2009). Modulatory effect of vitamins A, C and E mixtures against teflutherin pesticide genotoxicity in rat. *Res. J. Agric. Biol. Sci*, 5(6), 1070-1078.
- Séralini, G.E., Cellier, D., de Vendomois, J.S. (2007). New analysis of a rat feeding study with a genetically modified maize reveals signs of hepatorenal toxicity. *Arch. Environ. Contam. Toxicol*, 52, 596–602.
- Sharpe, R.M. (1992). Are environmental chemicals threats to male fertility? *Chem. and Industry*. 3, 88-94.
- Simonsen, L., Fomsgaard, I.S., Svensmark, B., Spliid, N.H. (2008). Fate and availability of glyphosate and AMPA in agricultural soil. *J. Environ. Sci. Health B*, 43, 365–375.
- Udoh, F.V., Udoh, P.B., Umoh, E.E. (2005). Activity of alkaloid extract of *Carica papaya* seeds on reproductive functions in male wistar rats. *Pharm. Biol*, 43(6), 563-567.
- Udoh, P.B., Udoh, F.V., Umo, I.S., Ikpeme, E.V. (2010). Effect of *Ipomoea batatas* leaf extract on the thyroidgonadal axis of male wistar rats. *J. Physiol. Pathophysiol.*, 1(2), 18-21.
- World Health Organization (WHO). (1992). Laboratory manual for the examination of human semen and sperm cervical mucus interaction. Cambridge University Press, Cambridge.